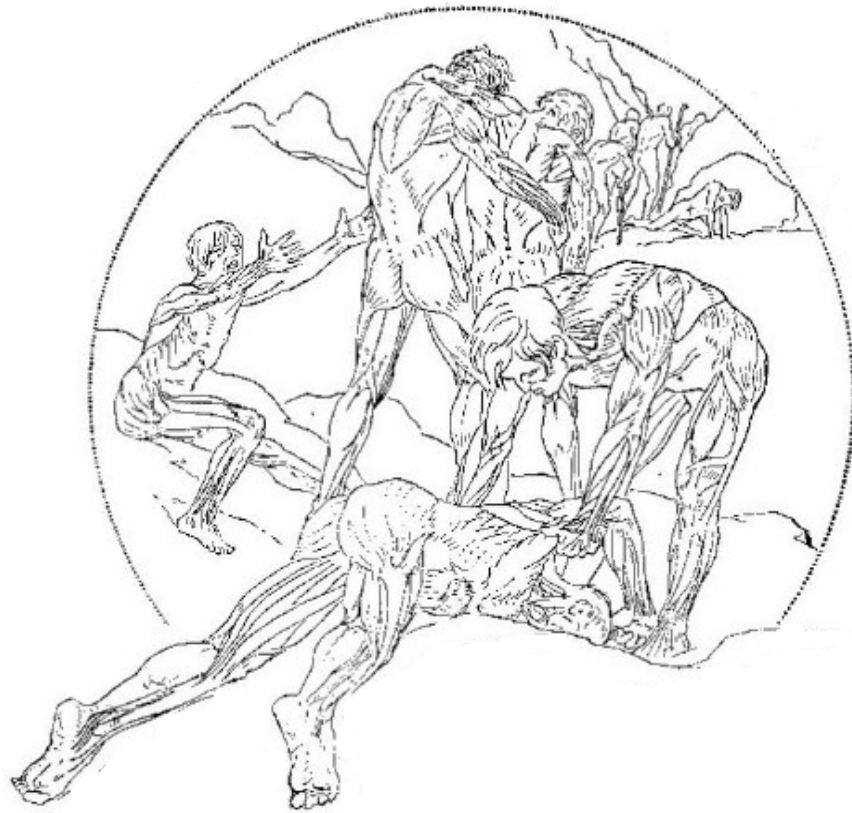

Shortcut Secrets  
of  
*Figure Drawing*



*By Victor Perard*

Art Instructor Traphagen Art School, New York City.  
Lecturer on Anatomy, formerly Art Instructor Cooper Union, New York City.  
Graduate Ecole des Beaux-Arts, Paris, the National Academy of Design and Art  
Students' League, New York City—Painter and Illustrator.

© 2010 All Rights Reserved

## *Publisher's Note*

*Thank you for purchasing "Shortcut Secrets of Figure Drawing" If this is your first time using the book, I recommend you scan it a couple of times and focus on the parts that jump out at you right away -- then take out your drawing pad and start copying a few of the illustrations.*

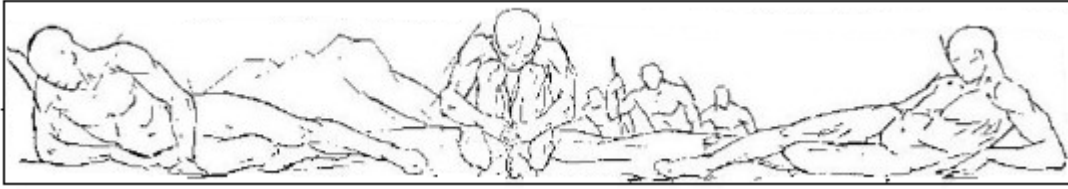Practice some of the sections for a few weeks. You'll notice a difference right away, and it will encourage you to try some of the other sections.

Whatever happens, you'll use the book as a constant reference as you're on your way to becoming a master artist.

*Please contact me at **support@MyDrawingTutorials.com** if you have any questions, issues, or feedbacks.*

*-Ethan*

*www.MyDrawingTutorials.com*



## *Praises For This Book*

*"An excellent resource for nearly any artist. **This is much better than anything I've seen coming out today.** With Perad's work you can actually get a sense for the whole human figure. I really like the way there are so many poses, angles, and positions illustrated. You can **use this material again and again** as a reference anytime you need. I highly recommend it."*

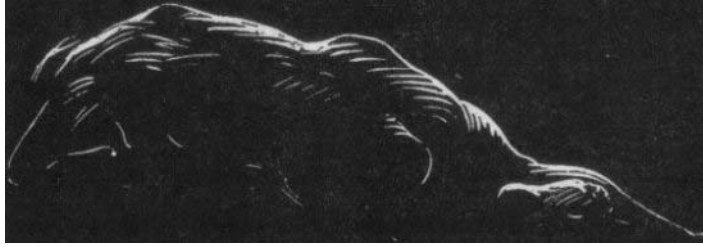**- Daniel Nie**

**Full time artist and recipient of the Sam Ragan Fine Arts Award with his artwork extensively displayed in the U.S., Europe and Canada.**

*"...**Superb drawings, excellent diagrams** - VERY thorough. I give this one very high marks."*

**-Terry Beatty**

**Acclaimed inker of DC Comics' "animated-style" Batman comics. His cover paintings appear regularly on Scary Monsters magazine and Monster Memories annual. His drawings and sculptures have been featured in various gallery shows in Minneapolis.**



## *Preface*

The purpose of this book is to present in a simple and direct manner the subject of anatomy as it is applied to Art. As little text as possible has been used, and much dependence has been placed on pictorial representations because the latter are a more direct means of impressing the artist with construction and form. For this reason this work has been copiously illustrated, often showing various views of the same structures and actions.

To the beginner the study of anatomy is too often dull, prosaic and difficult and this is due, in large part, to the fact that many text books on the subject contain insufficient descriptive drawings. Even though the student plows through many pages of text, he often fails to visualize the subject properly. Therefore it has been endeavored to substitute illustrations for descriptive text whenever practical. The drawings have been arranged in groups for the purpose of comparison, and in this way the eye becomes accustomed to observe much which otherwise might escape attention.

To express outward form correctly requires a knowledge of the internal structure, that is, of the bones which compose the framework and define its proportions and of the muscles and tendons which direct its action.

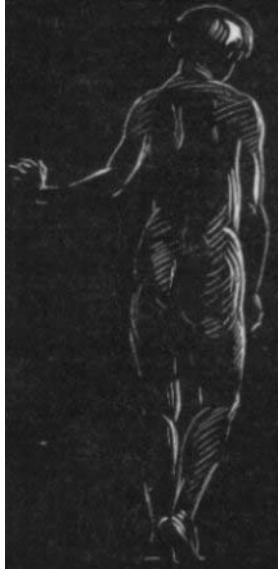Every figure artist finds sooner or later, as he advances in his artistic career, that his work needs strengthening through a well grounded knowledge of anatomy. The great masters of the past realized this and their grasp on the fundamentals of anatomy is reflected not only in their finished works, but in such of their preliminary sketches as are still preserved.

The ability to construct figures correctly from the imagination rather than to depend entirely on models is a distinct aid to the draftsman and to the sculptor. The student of anatomy should therefore test his skill by making memory drawings and by applying his knowledge to compositions of his own fancy.

When working from living models, the artist will find that his knowledge of anatomy will enable him to analyze and interpret the forms before him in a more understanding way than he could without such information. It will develop in him greater powers of observation. An understanding of anatomy is an instrument in the mechanics of Art: a means to be employed to assist but never allowed to dominate. The artist must learn properly to evaluate his anatomical information and to know the part it is to play in the development of his art. The studies he makes will then be done more intelligently and with better draftsmanship as an inevitable result.

*- Victor Perard*





## *Notes on Proportion*

Since proportion is the comparative relation of one thing to another, some standard or unit of measure must arbitrarily be established. In Art, this unit is known as the "head" which is the distance from the top of the skull to the tip of the chin. The illustrations in this book are based on the proportion of seven and a half "heads" to the height of an erect figure. The use of this standard will obviate much descriptive text. It is well, however, to bear in mind that this standard of proportion is modified by such elements as race, sex, age and physical differences peculiar to the individual. For this reason the following notes on proportion are grouped under the heads: Male, Female, Children and General Observations.

***Proportions of the Male.*** The greatest width of the male figure is at the deltoids, a little below the shoulders and the width here is about two heads.

The width between the hips should equal one and one half heads, and the width between the nipples one head.

The height of the figure, seven and one-half heads, should approximate one "head" for the head, two and three-quarter heads for the neck and trunk, and three and three-quarter heads for the lower extremities.

From the finger tips to the elbow should measure two heads.

***Proportions of the Female.*** The bones of the female are shorter and have less rough surfaces than those of the male. The sternum or breast bone is shorter and more curved and the pelvis is broader and shallower which gives a greater width to the hips. The sacrum is wider and projects at an angle backward.

The posterior superior iliac spines and the anterior iliac spines are further apart than those of the male. The distance from the rib cage to the pelvis is greater due to the shallower and broader pelvis.

There is less distance from the crest of the iliacs to the great trochanters of the hips, because

the anterior iliac spines are spread out and lower, and further apart. In the female figure the Poupart's ligaments and the furrow of the groin are more horizontal.

The shoulders are narrower and the collar bones (clavicles) straighter and shorter thus giving a more graceful and longer neck and more sloping shoulders in comparison with the square shoulders of the male.

The arms are shorter in proportion to the trunk which is due to the shorter humerus bone of the female, and because the humerus bone is shorter, the elbow is higher.

Variations in the length of the female leg are more frequent than those of the trunk and so it is more difficult to judge the height of the female figure when seated. But the length of the torso is proportionately longer than in the other sex. The legs are shorter and the skull smaller.

The center of the female figure is above the pubic bone while in the male, the center is about at the pubic bone. The width of the female hips is about the width of the chest wall plus that of one arm and is greater than that of the male of the same height. The fact that the female sacrum is at a greater angle than that of the male and that there is more fat on the buttocks gives these a greater diameter.

The female abdomen, is more rounded and the thighs are thicker from the back to the front than in the other sex.

***Proportions of Children.*** The child of three is about one half the height of the adult, and at ten, about three-quarters the height of the adult. As the child grows older the relative sizes of the head and the trunk change. At twenty-five the figure is full grown.

At birth the center of the figure is a little above the navel, at two years at the navel and at three years the center is level with the iliac bone.

With advancing age this point gradually lowers depending to a great extent on the length of the legs.

***General Observations.*** The clavicle bone continues to grow for a considerable period after the other bones of the body have attained their full development and therefore the shoulders are said to broaden.

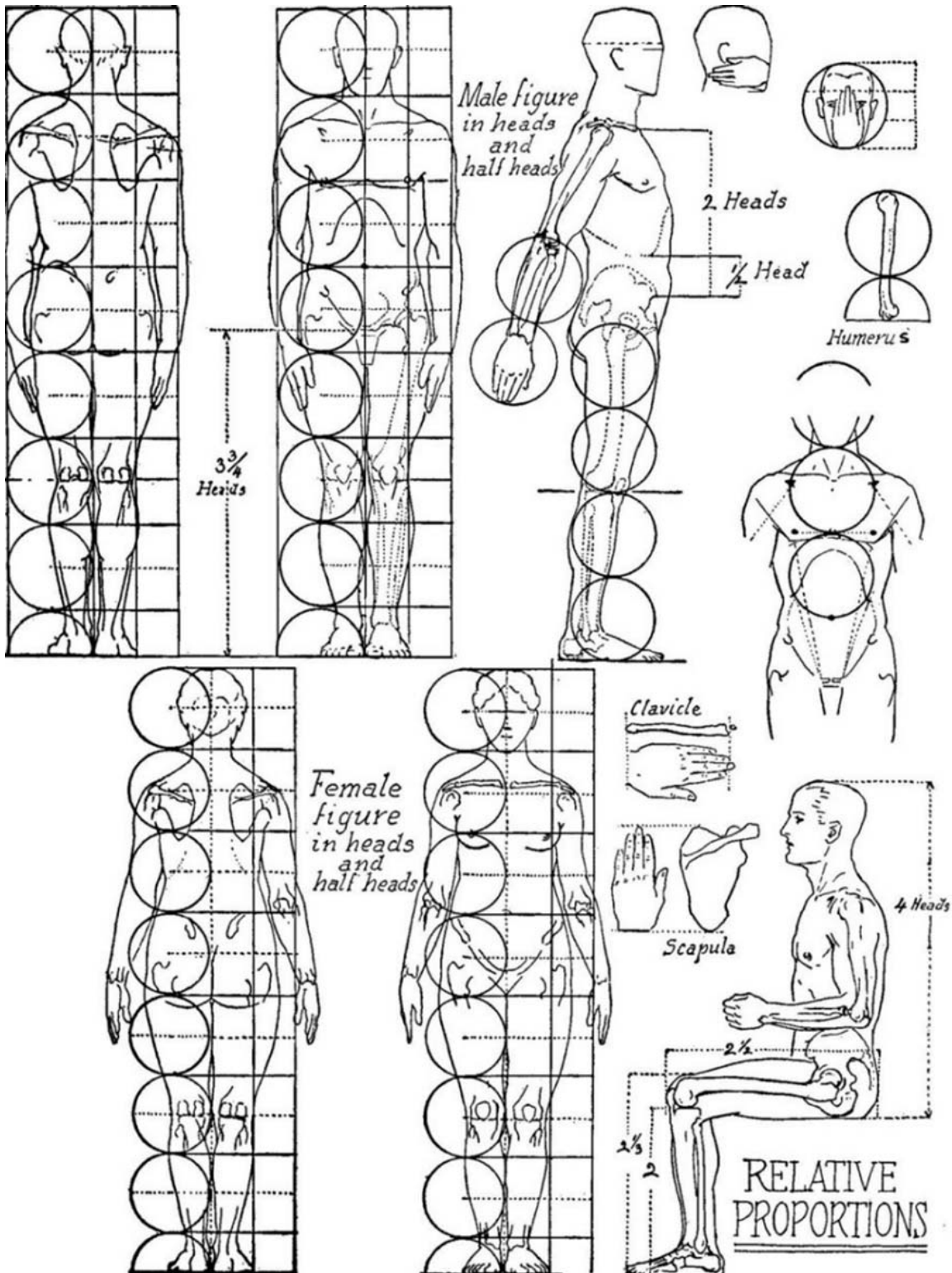
Only very tall people have a height of eight heads. Short people are seven heads or less. The muscles of the adult account for about one half the weight of the body.

The skeleton always provides the proportions of the figure with slight allowances for the padding between the joints, between each vertebra, and under the heel and foot. In old age the figure shortens due to the hardening and shrinking of the cartilages between the bones.

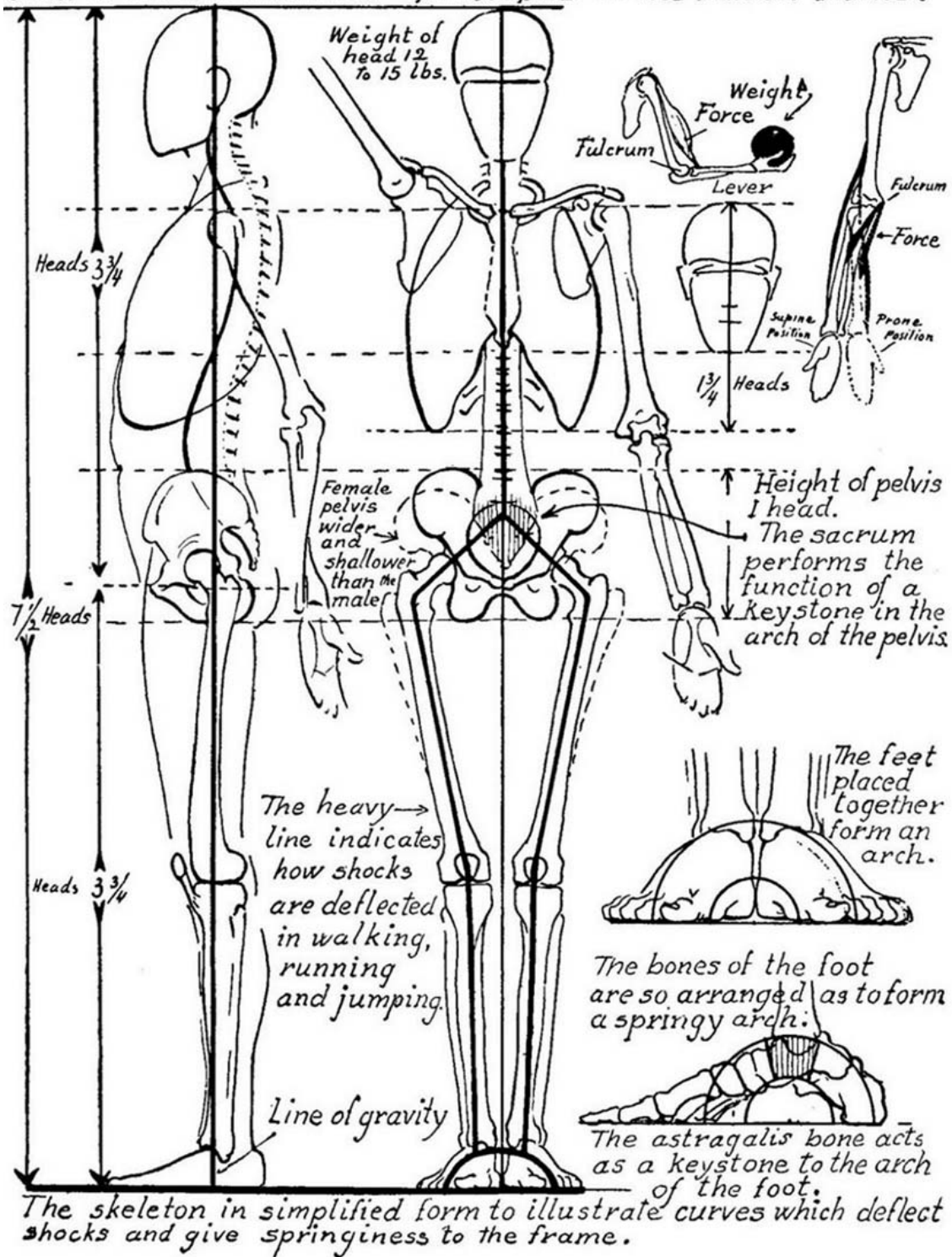


Part I

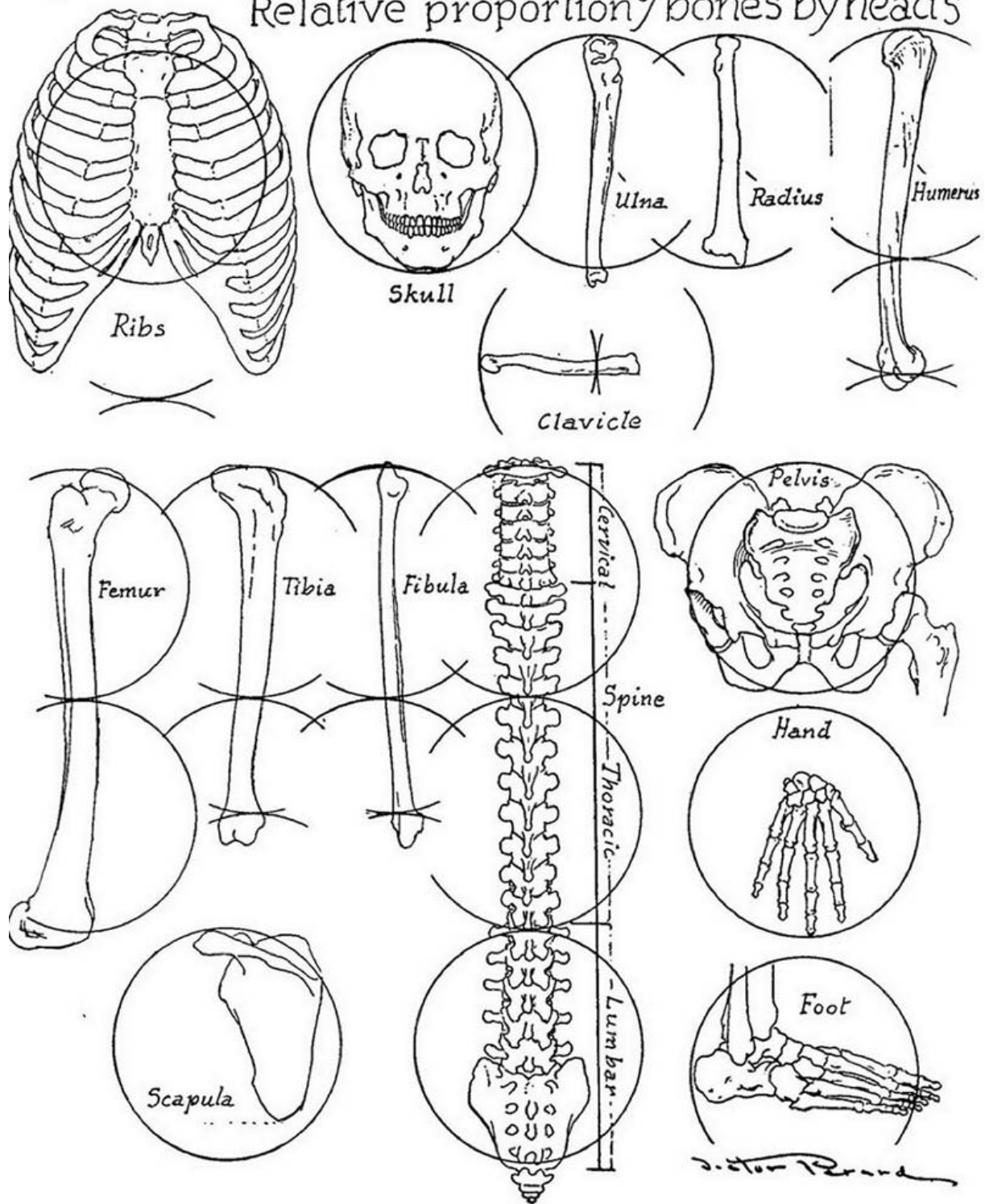
*Proportion*  
&  
*Drawing*

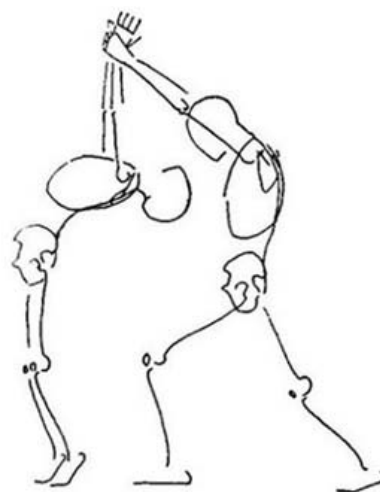
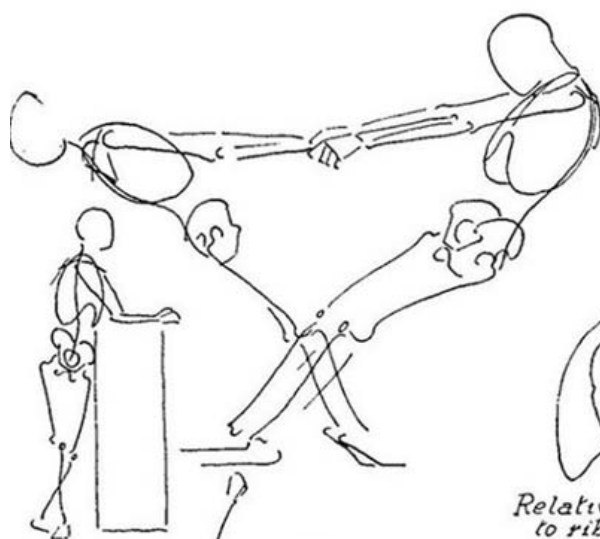


*Some of the mechanical principles of the human frame.*



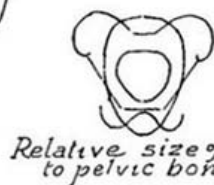

# Relative proportion of bones by heads



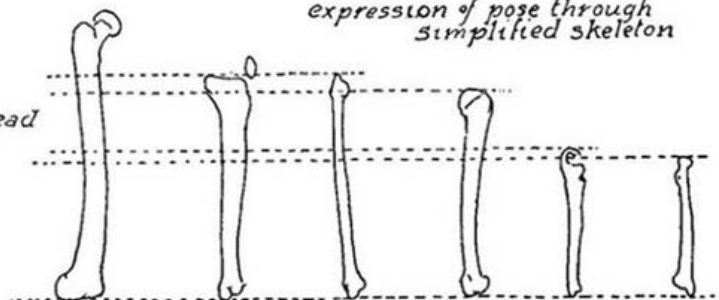


*Relative size of head to rib cage*

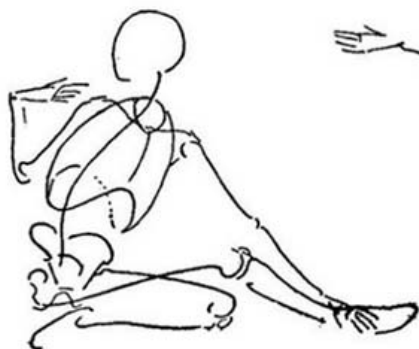
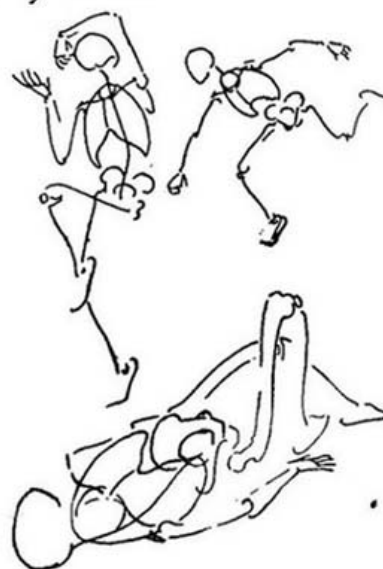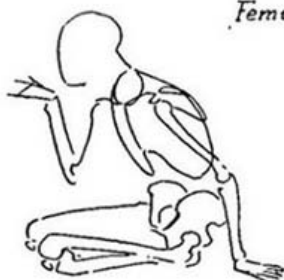
*Method for obtaining expression of pose through simplified skeleton*

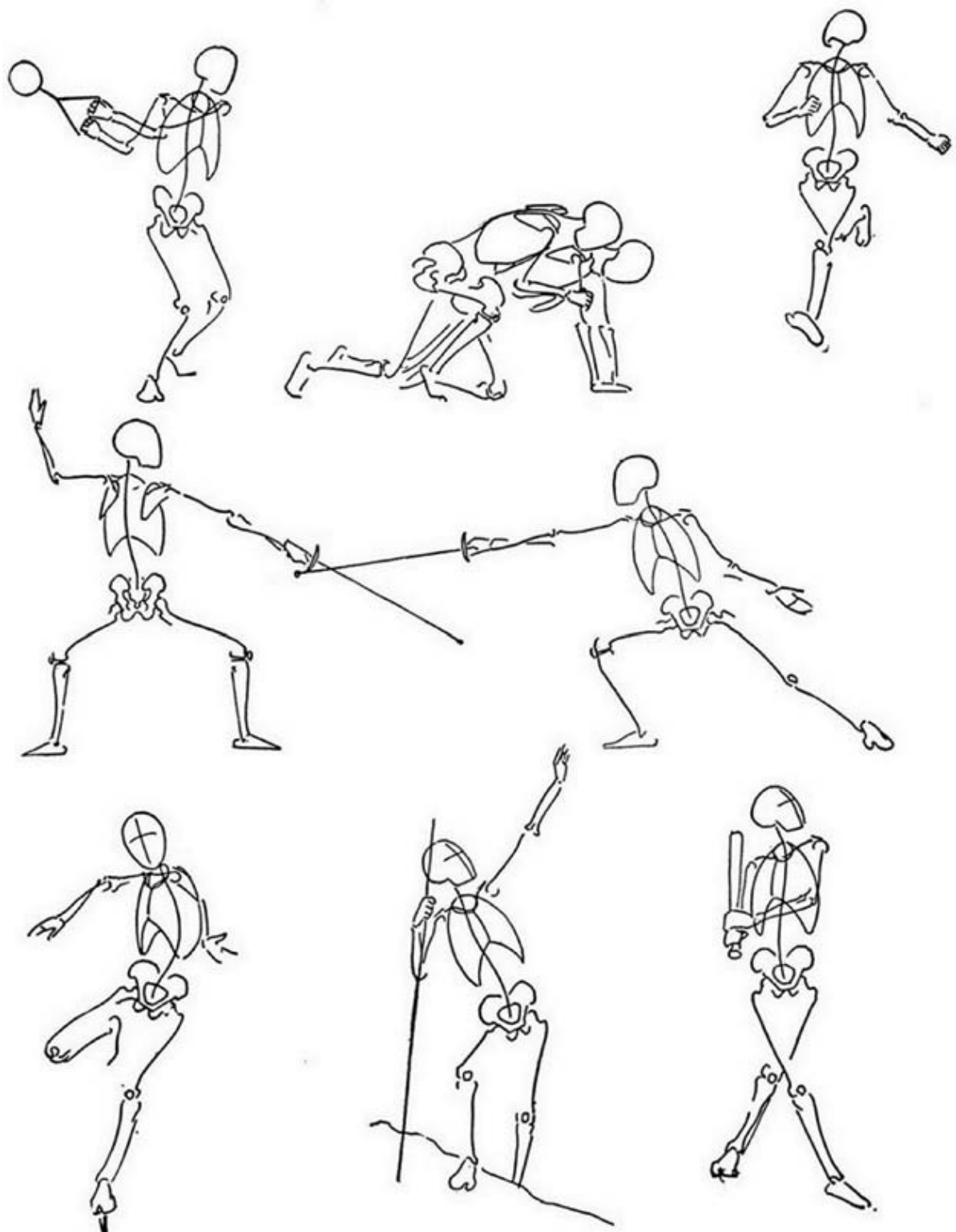


*Relative size of head to pelvic bone*

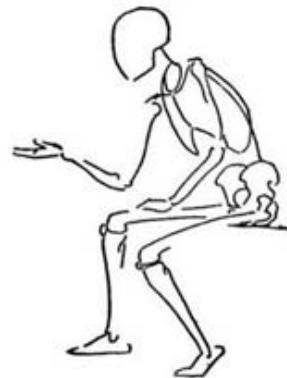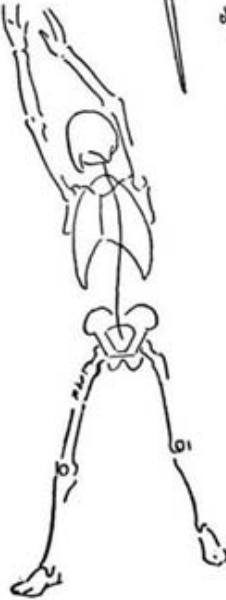
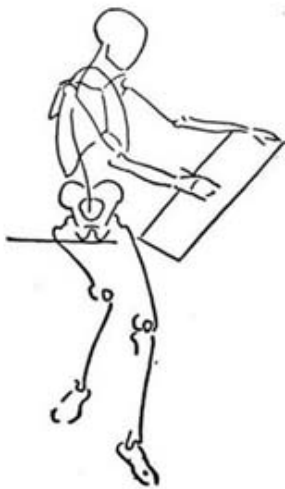
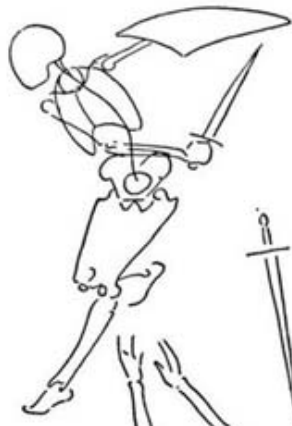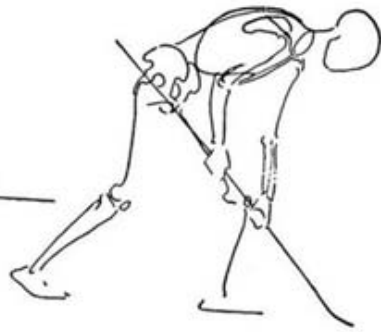


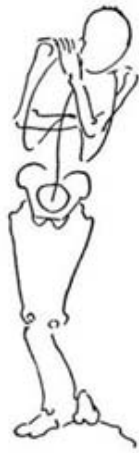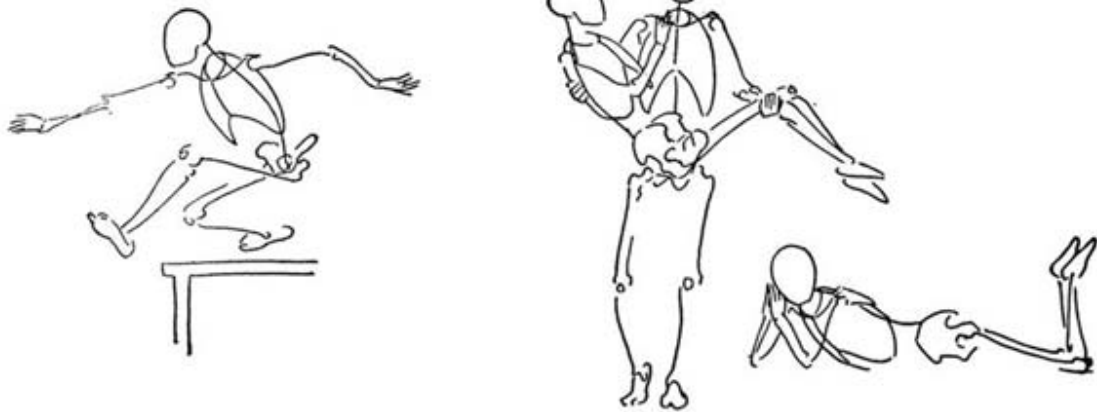
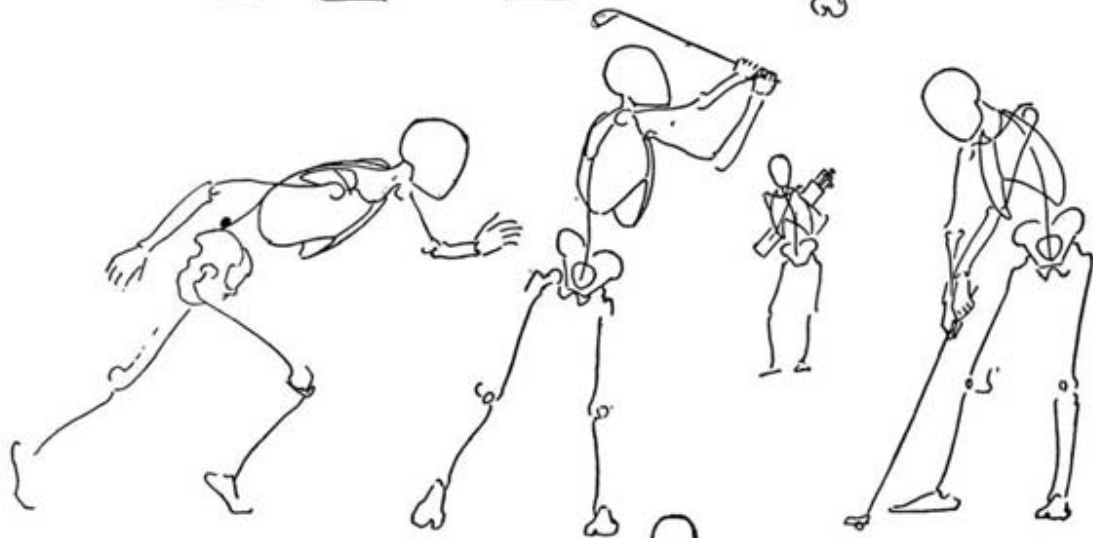
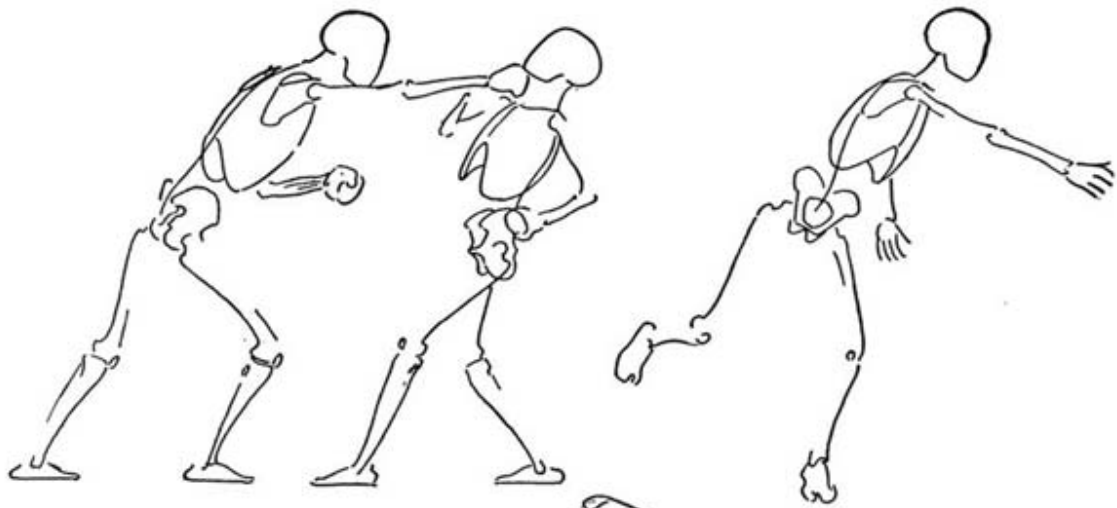
*Relative size of bones*

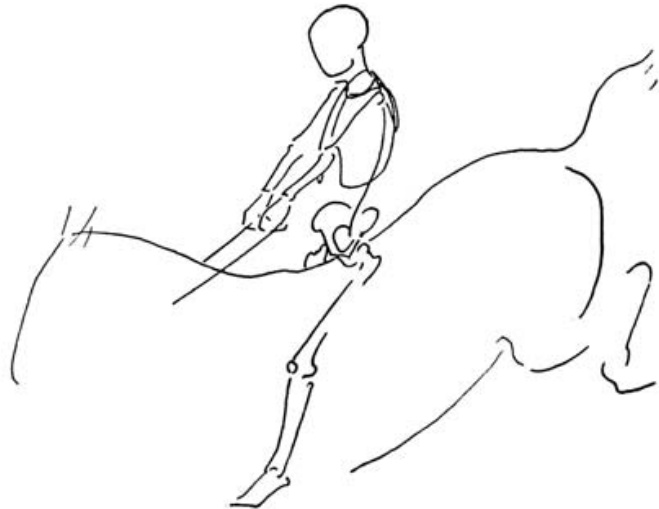
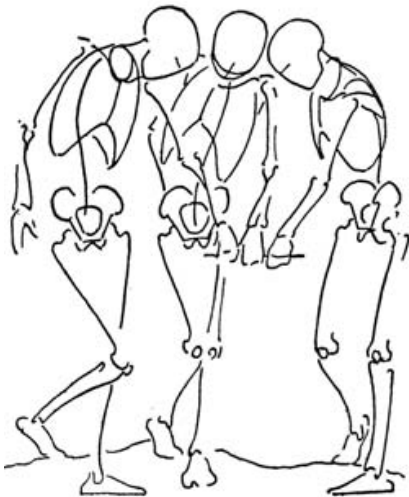
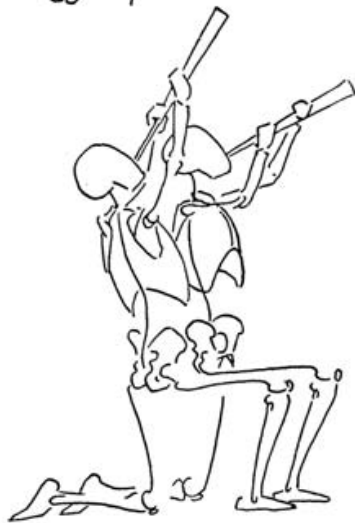
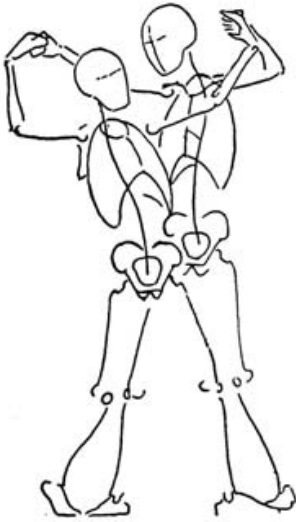
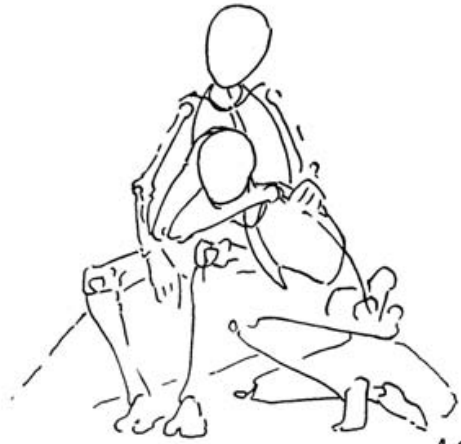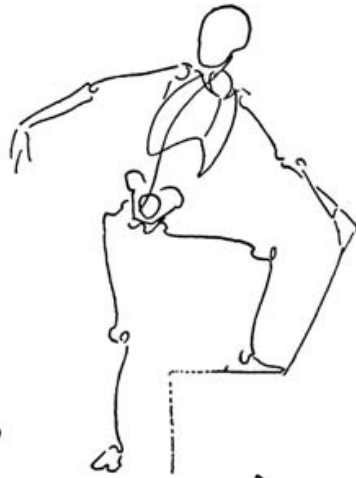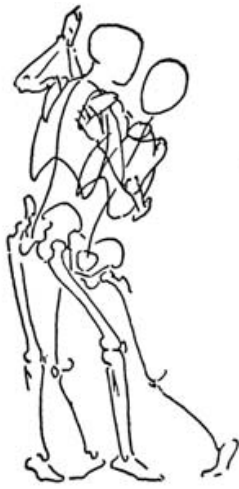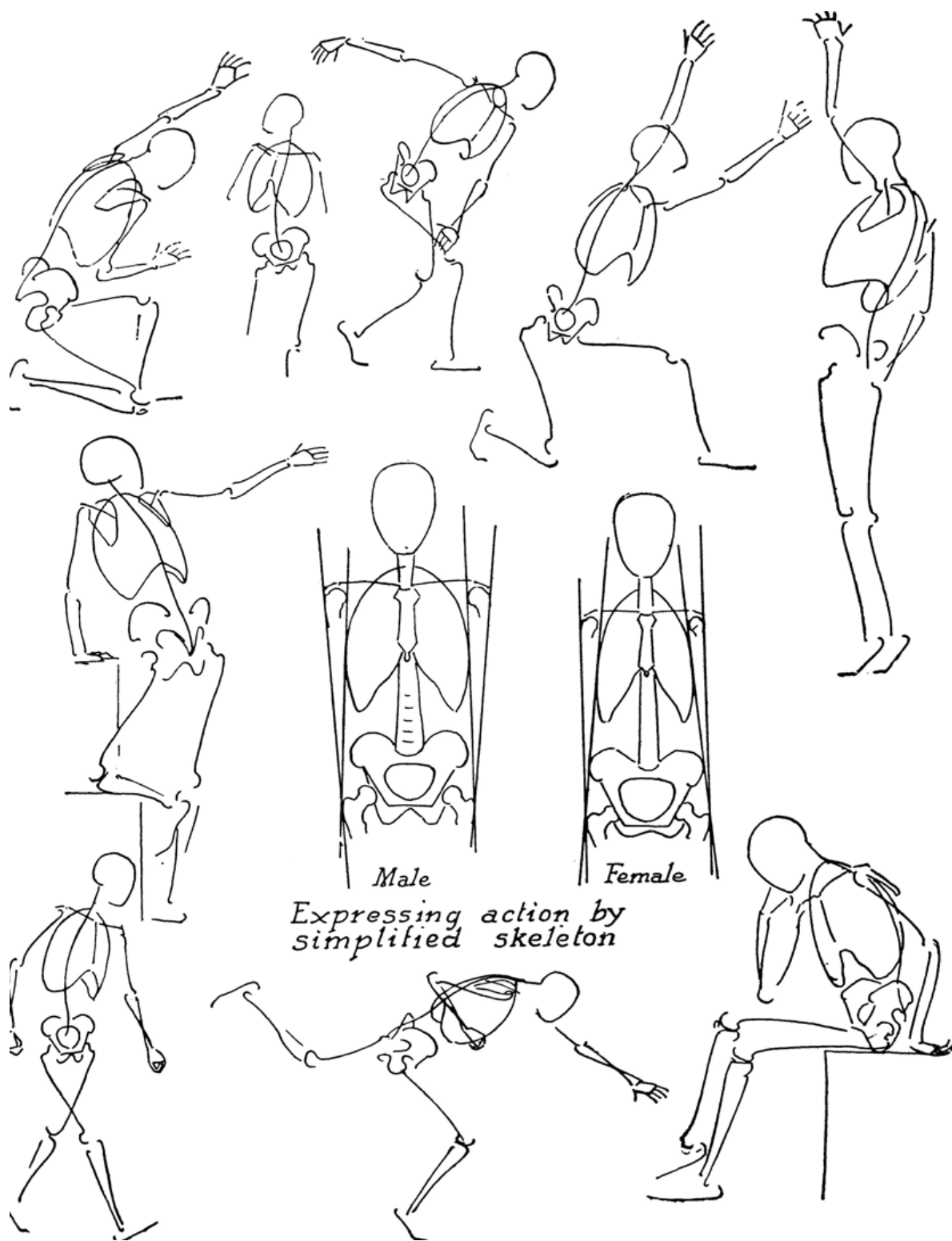










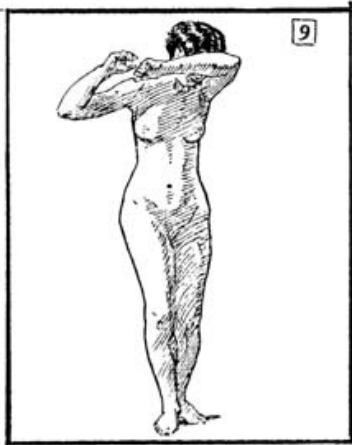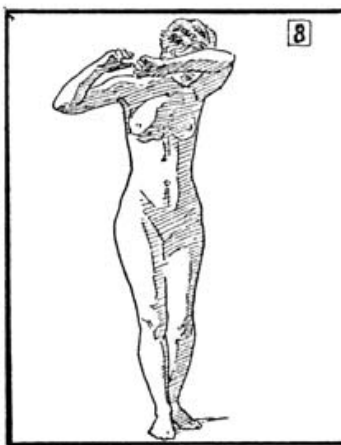
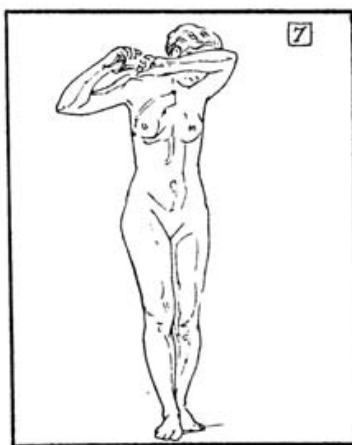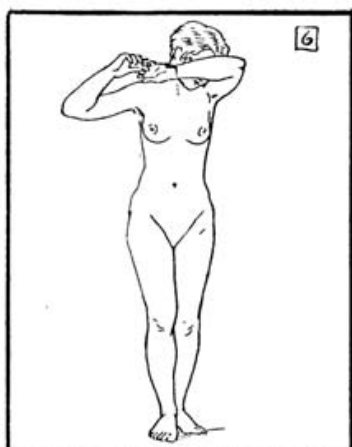
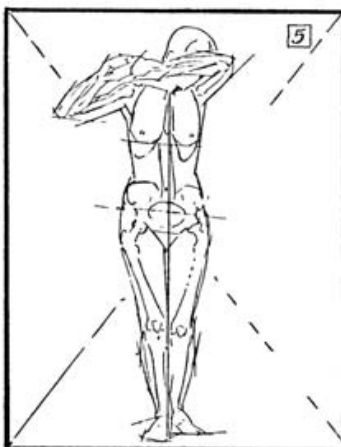
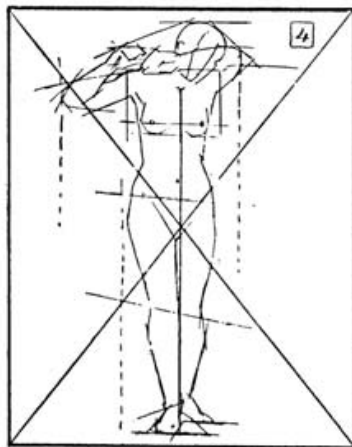
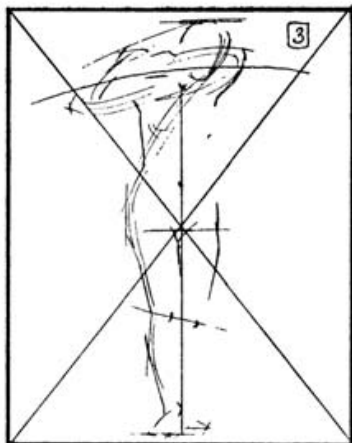
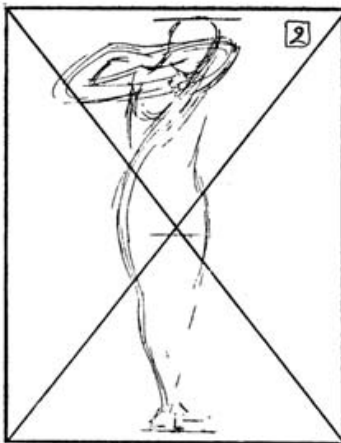
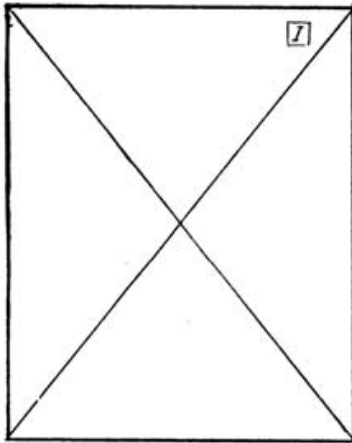


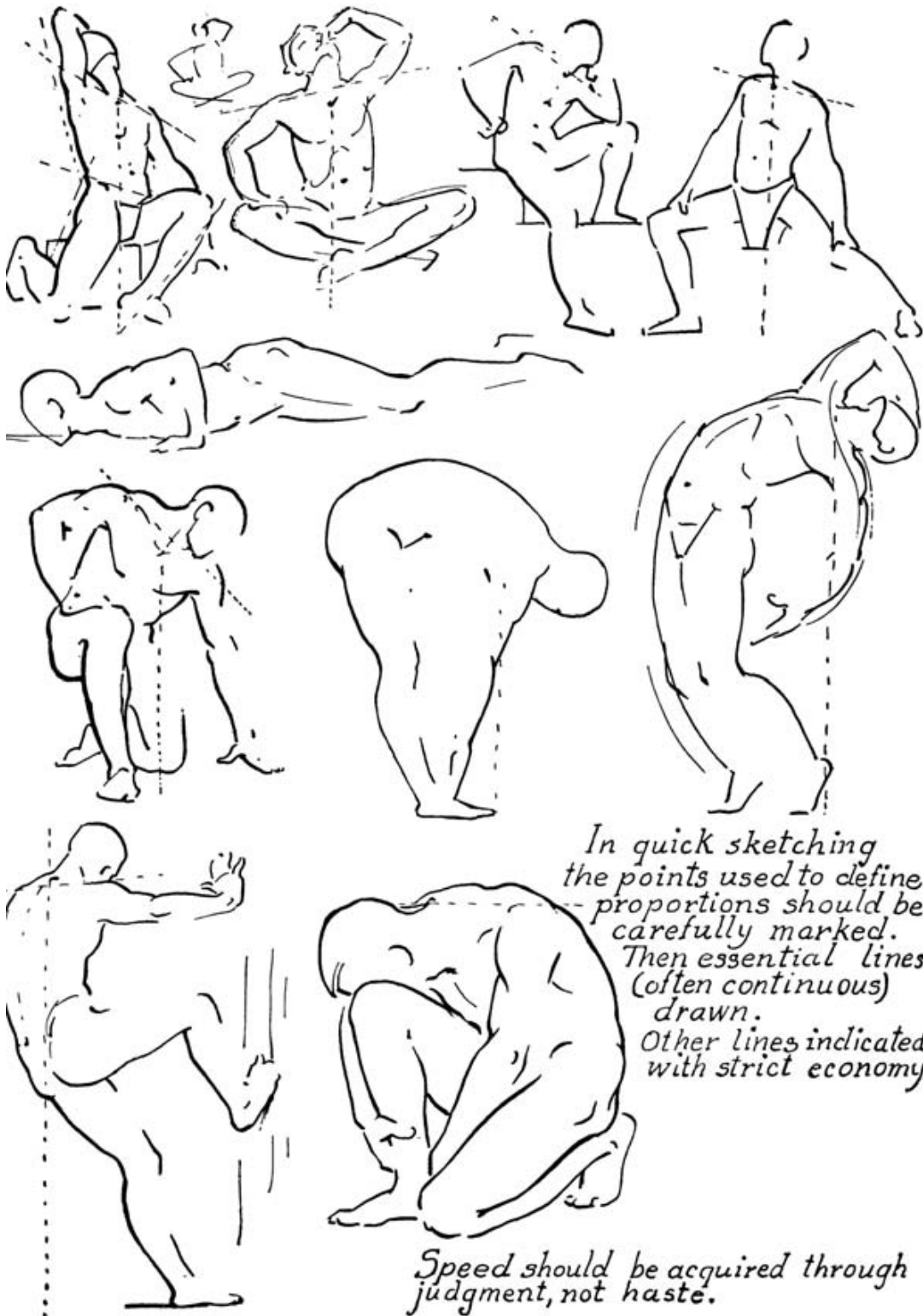
Male Female  
Expressing action by  
simplified skeleton

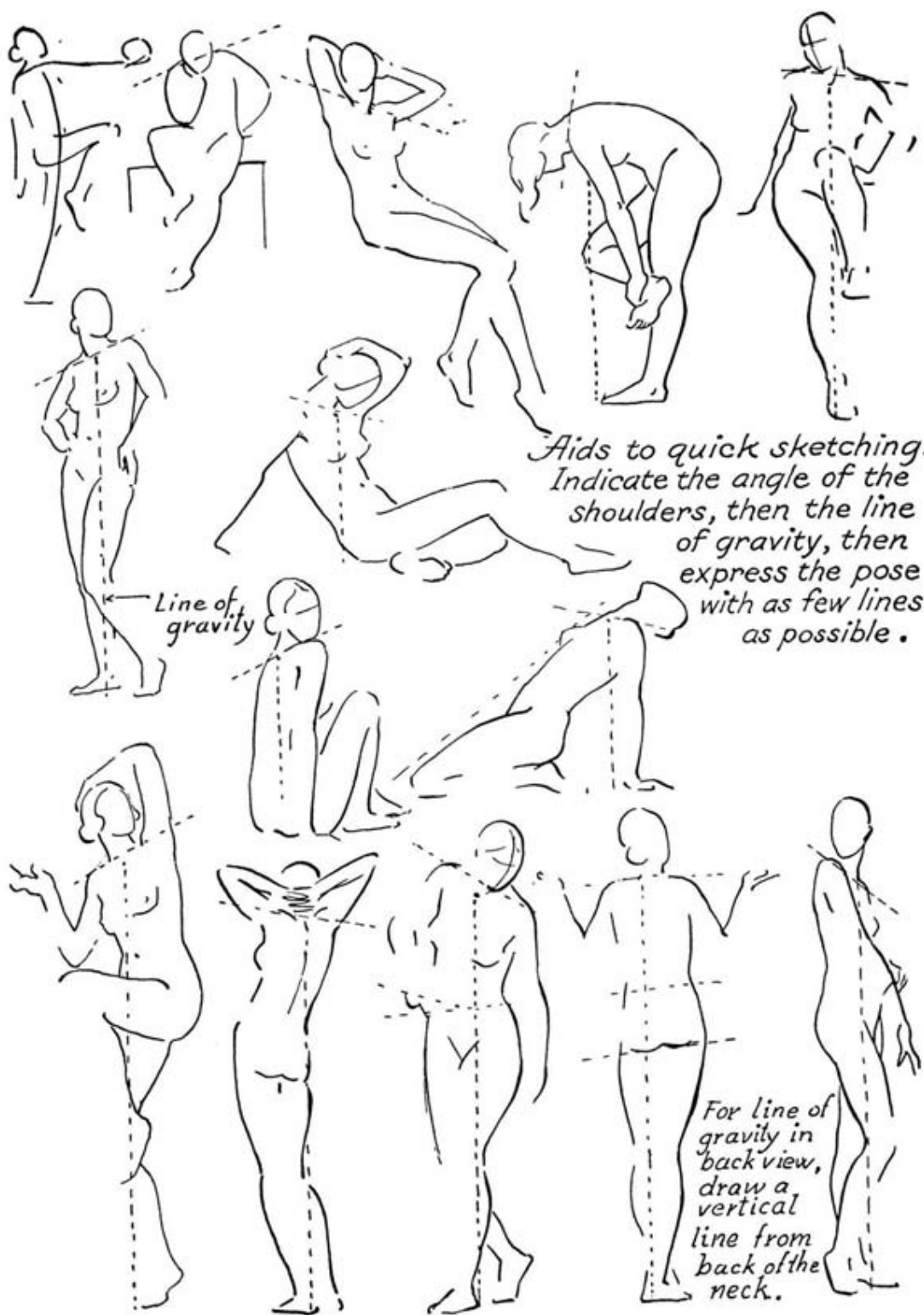
# Method of Drawing

## From Life or from the Cast

1. Find the center of the paper by drawing lines from corner to corner. This is done to help center the study.
2. Measure with the eye or pencil to find the center of the subject and make a line at that point as related to the center of the paper. Draw a line at the head and another at the feet.
3. With free lines search for the rhythm of the pose, to help visualize the figure and to place it on the paper the size intended. Draw lightly so that the mental impression of the figure is not obliterated by a heavy drawing, and corrections can be easily made.
4. Decide where the pit of the neck should be placed and draw a perpendicular line from this point (if a front view) to the feet. If a back view, draw the perpendicular line from the seventh cervical vertebra to the feet.
5. Find the line of the shoulders, giving the angle of their positions. If a standing figure, first draw the leg on which there is most weight, to obtain the proper balance of the figure.
6. Give the line showing the angle of the position of the pelvis.
7. Indicate a line through the knee-caps. Draw the torso, indicating its bulk, marking the width of shoulders, hips, neck and head. Block with straight lines going beyond the intersections to obtain a better idea of the direction of line and to avoid a cramped feeling. Method of Drawing
8. Sketch within the lines a simplified skeleton, to check up on position of joints and bulk of chest. (Refer to pages on proportion.) See that the pit of the neck, the pubic bone, the navel, the pelvis, the knee-caps and the inner ankles are in proper relation to each other. Compare relative sizes of head to bulk of torso, hands to face, feet to hands, arms to legs, and thickness of the neck to that of the head, leg and arm.
9. Go over the outline, perfecting it, searching for character and for grace of line.
10. Indicate the outline of the planes and of the principal shadows.
11. Fill in the planes in large surfaces, and connect the shadows as much as possible.
12. Without losing their mass, model the planes keeping well in mind the direction of light.
13. In drawing the head, decide on the bulk and draw in the planes of the face (see Part III), then the eyes, the mouth and the nose last. It is easier to fit a head on a figure, than to fit a figure to a head.





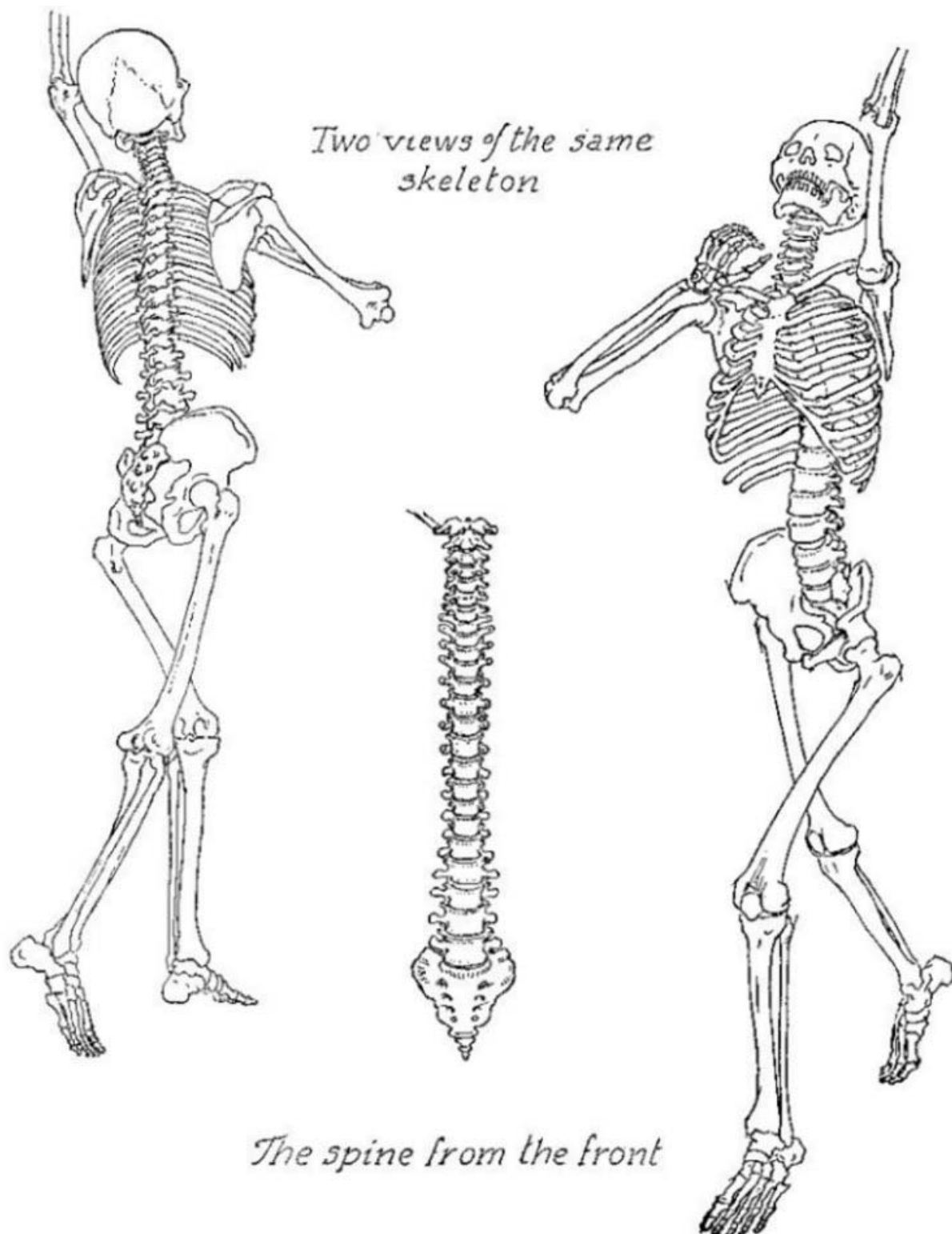


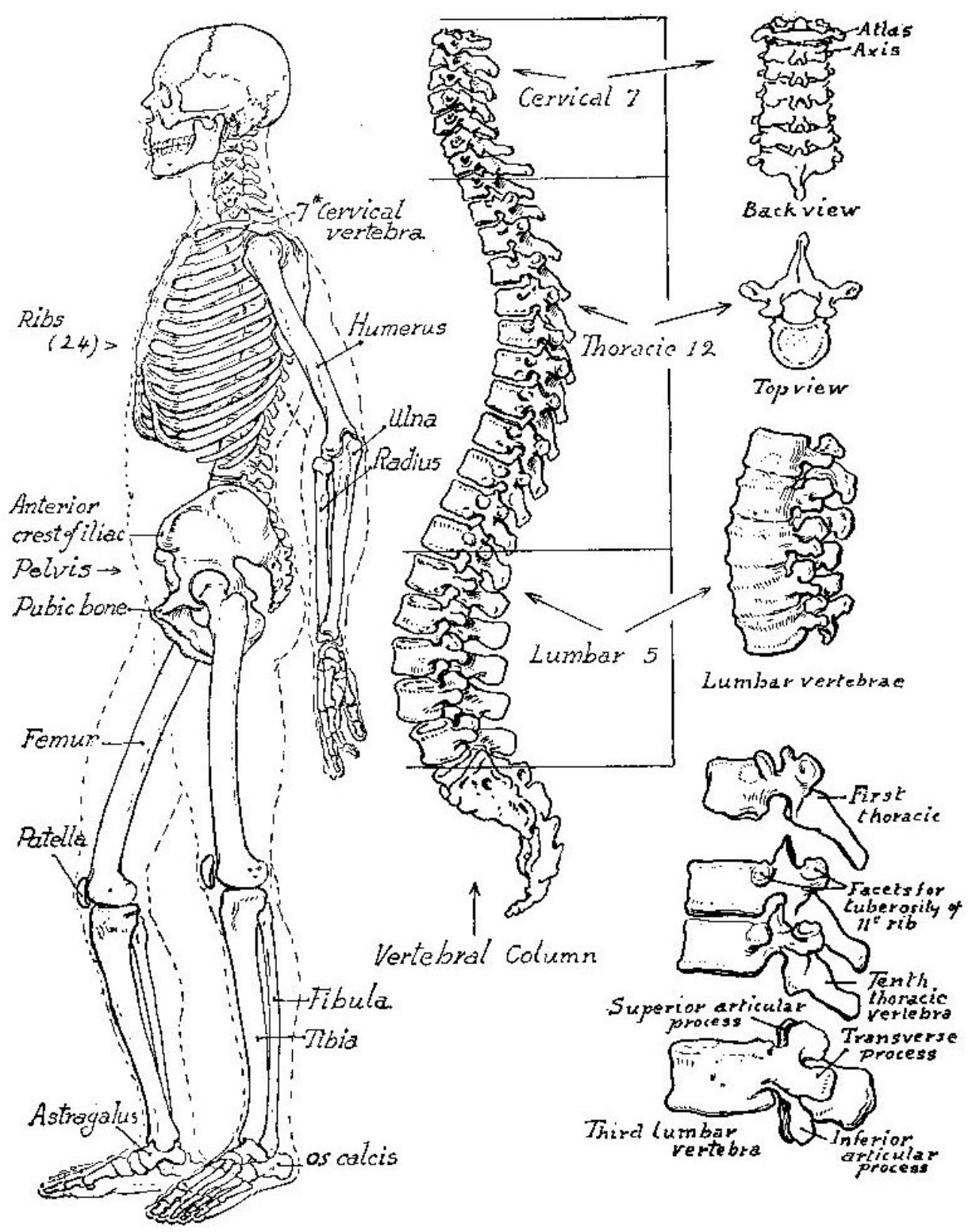


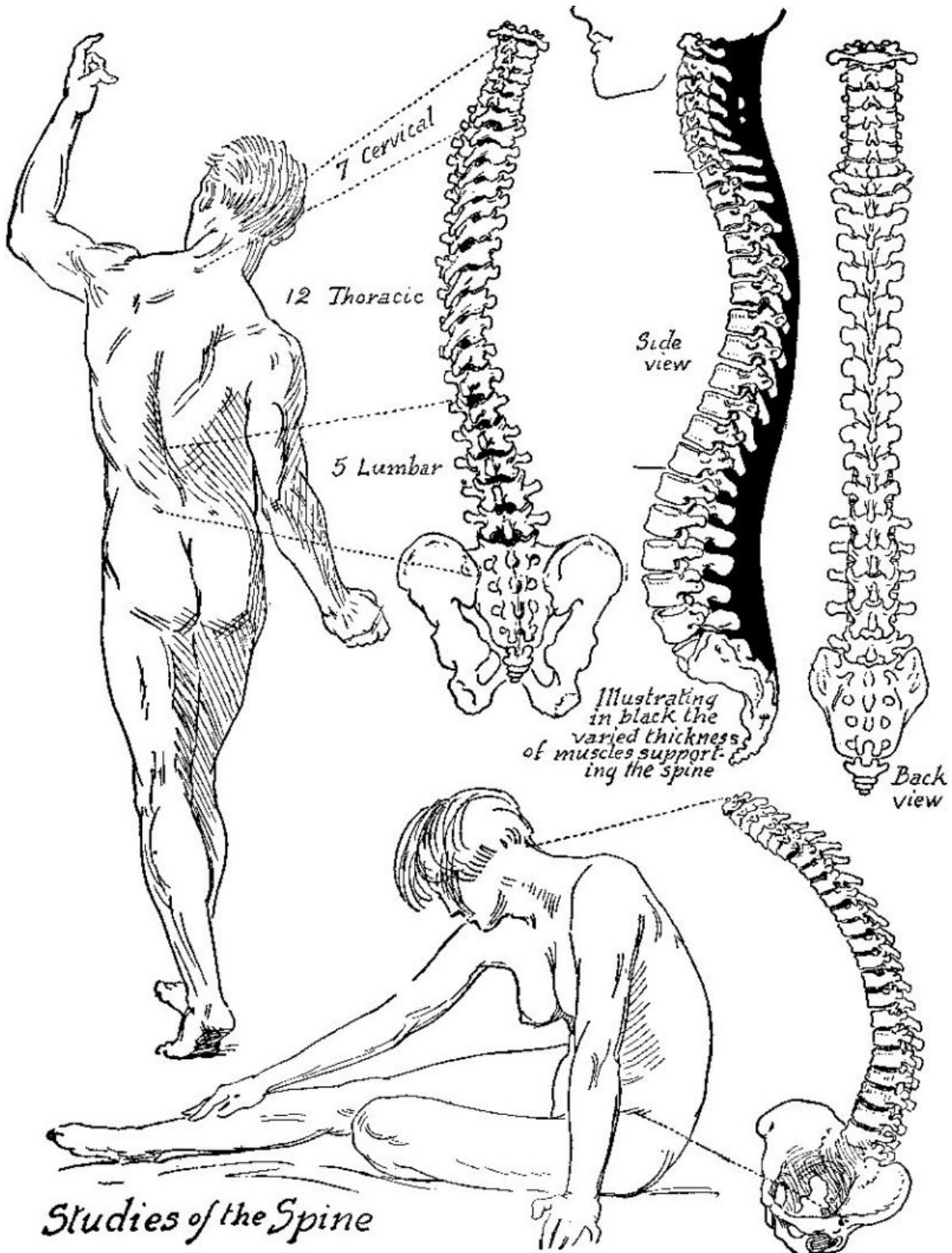


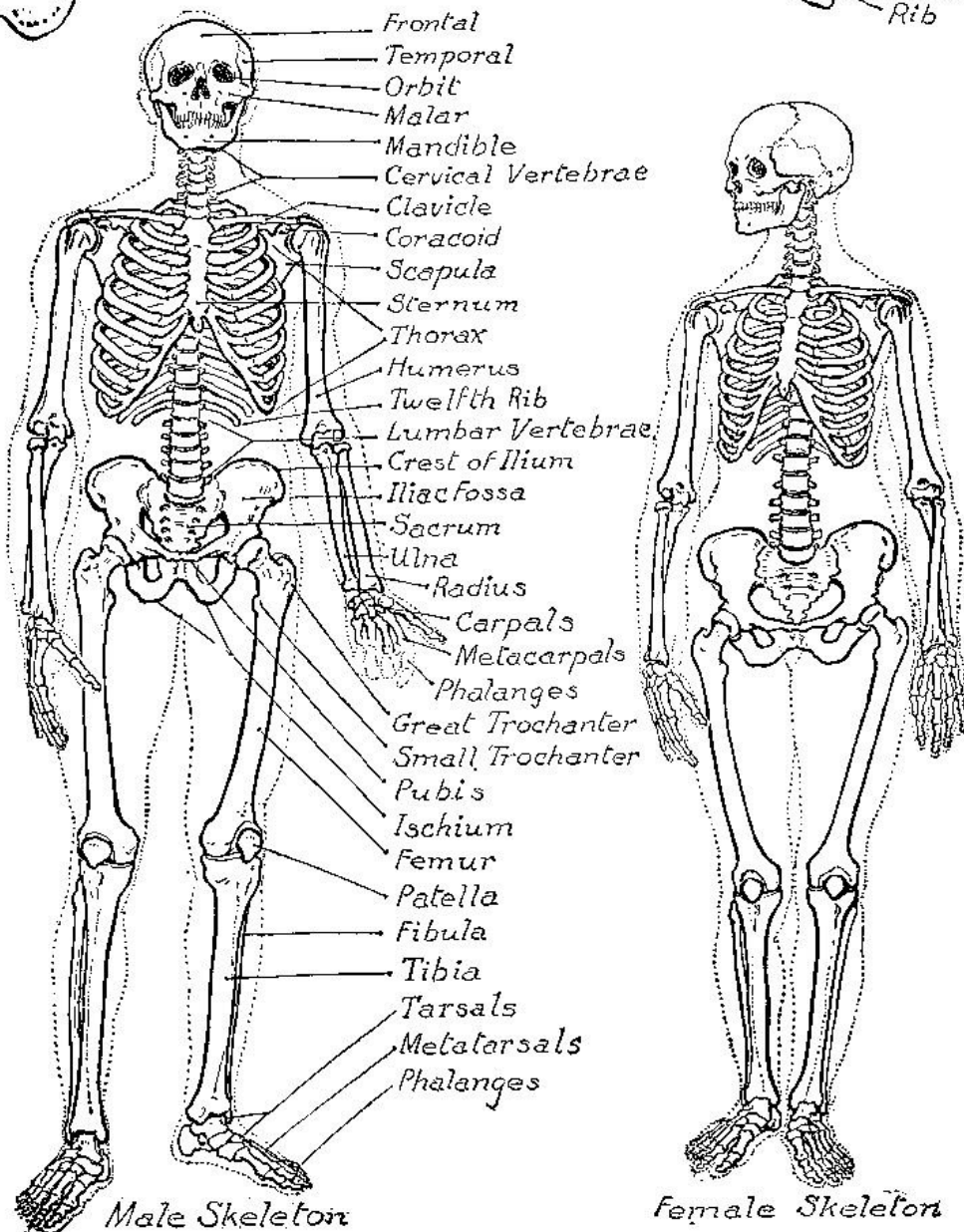
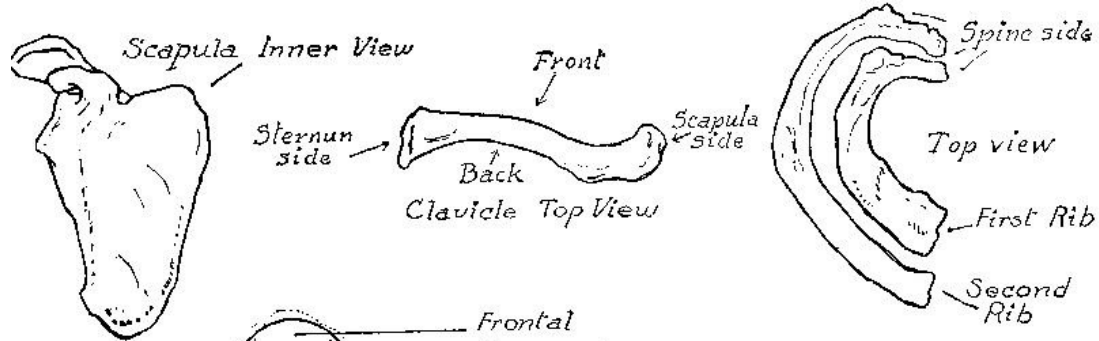
## Part II

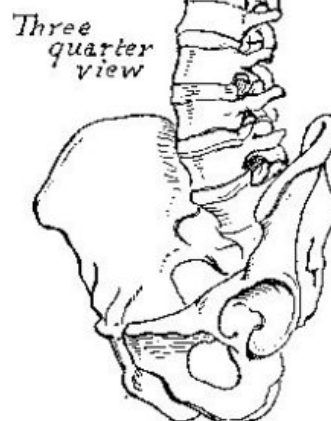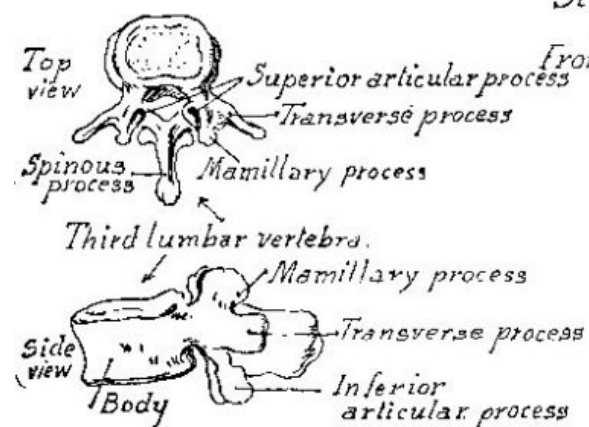
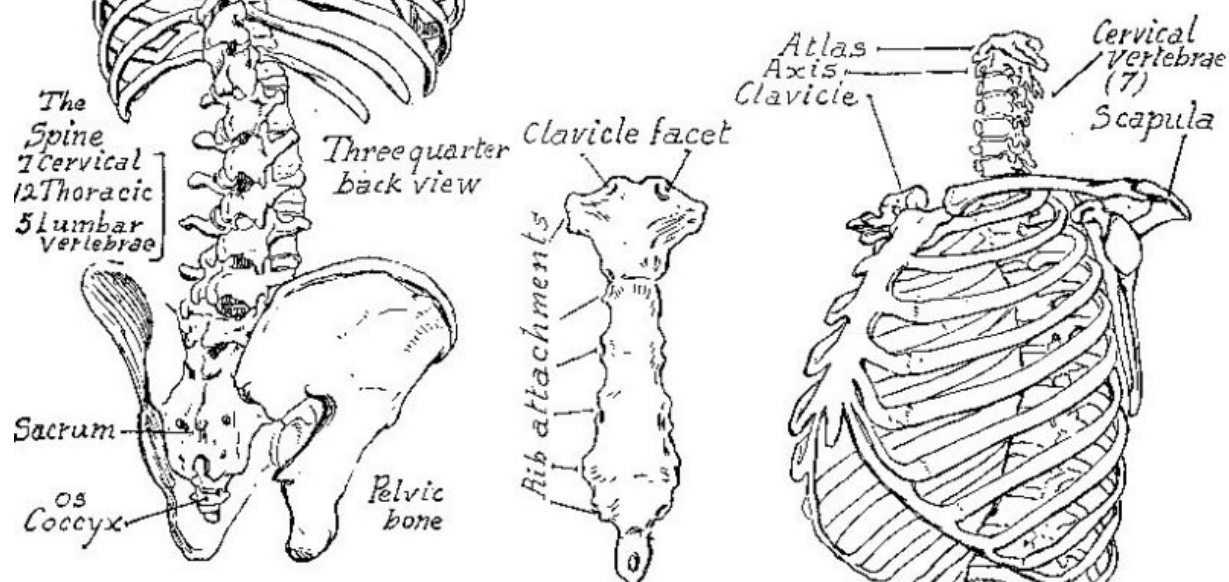
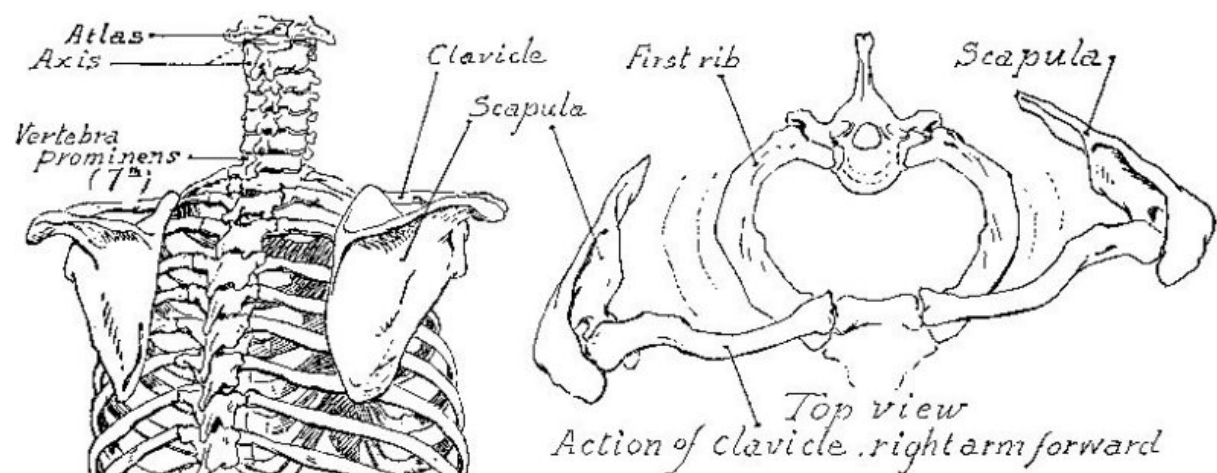
# *The Skeleton*







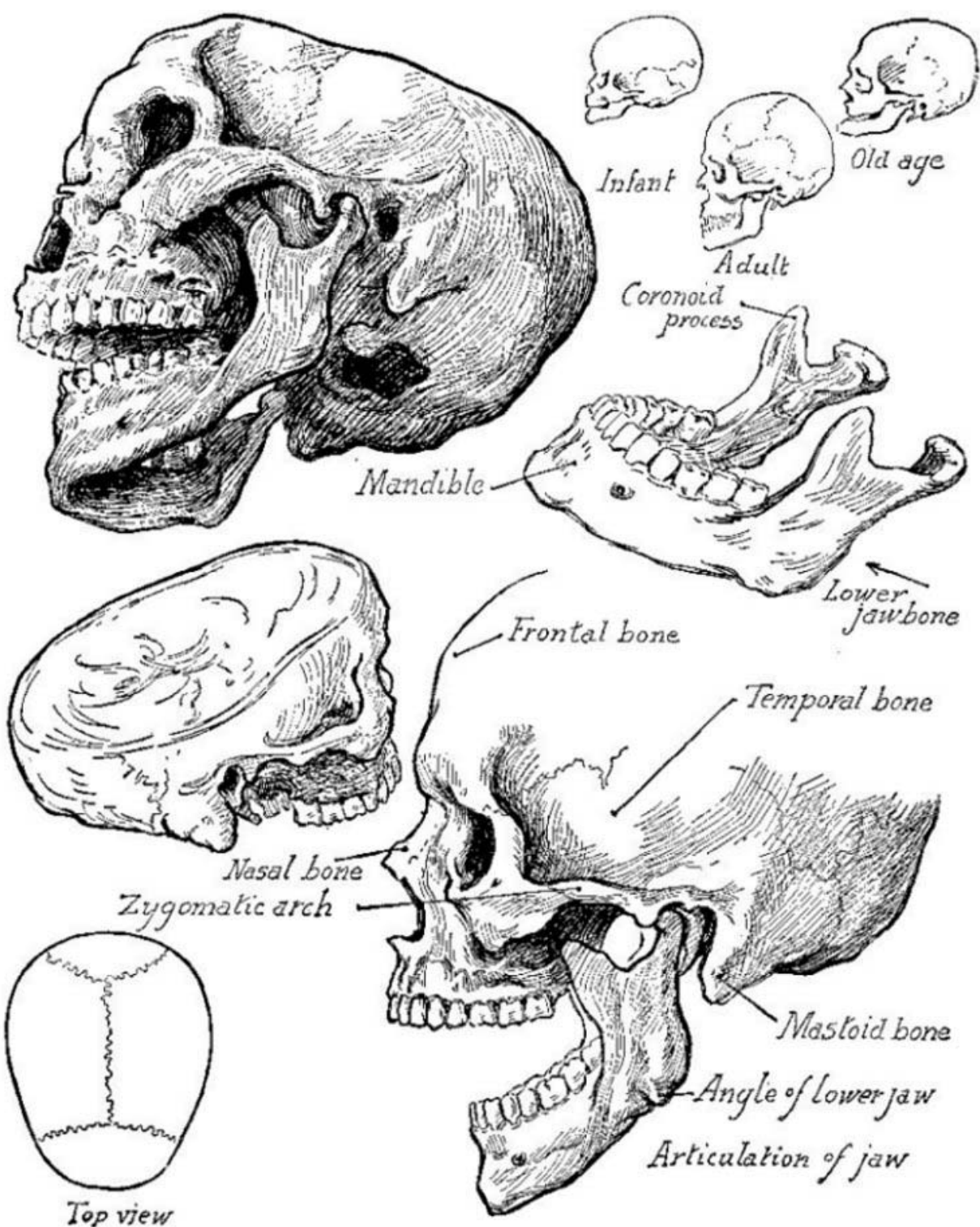






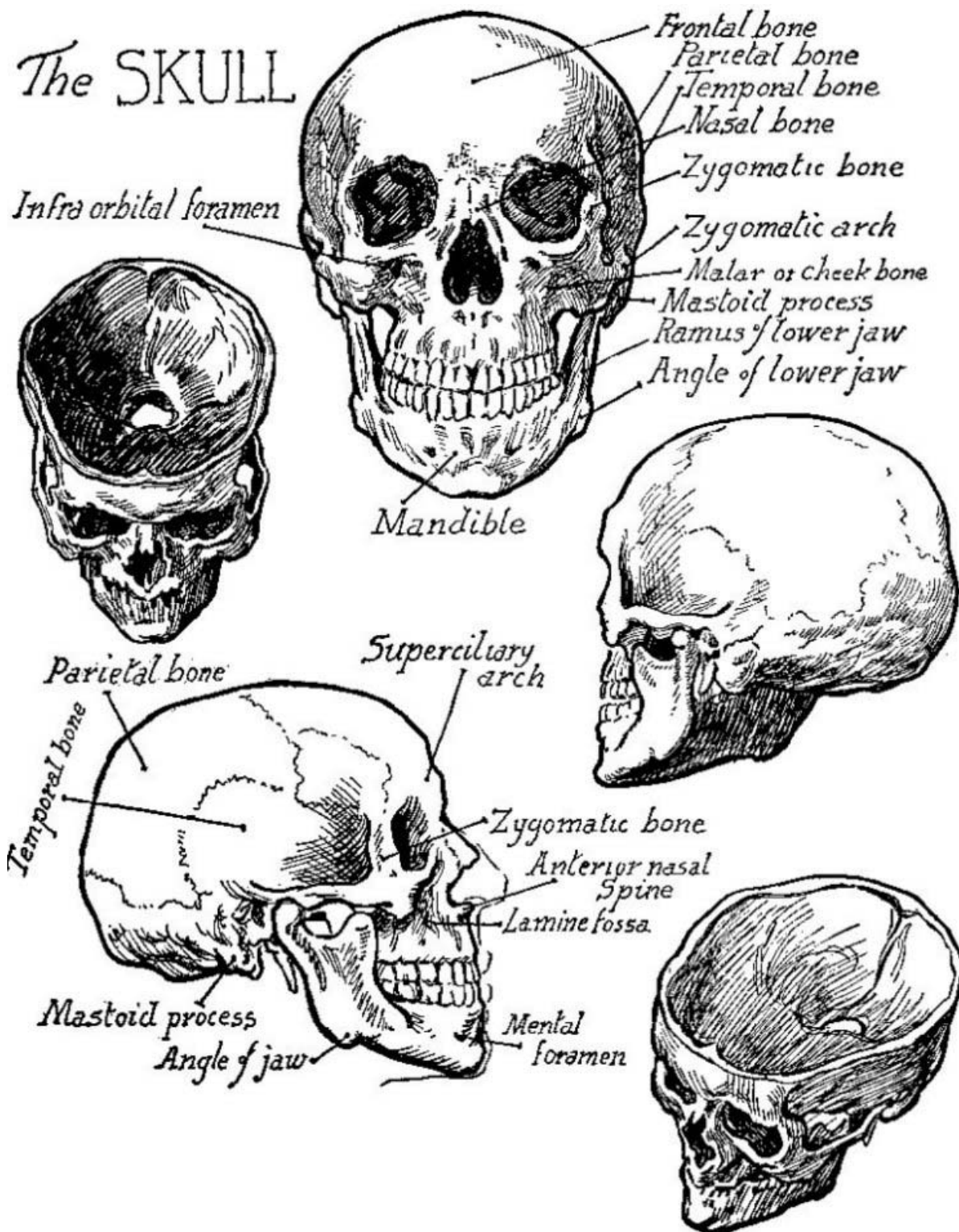
Part III

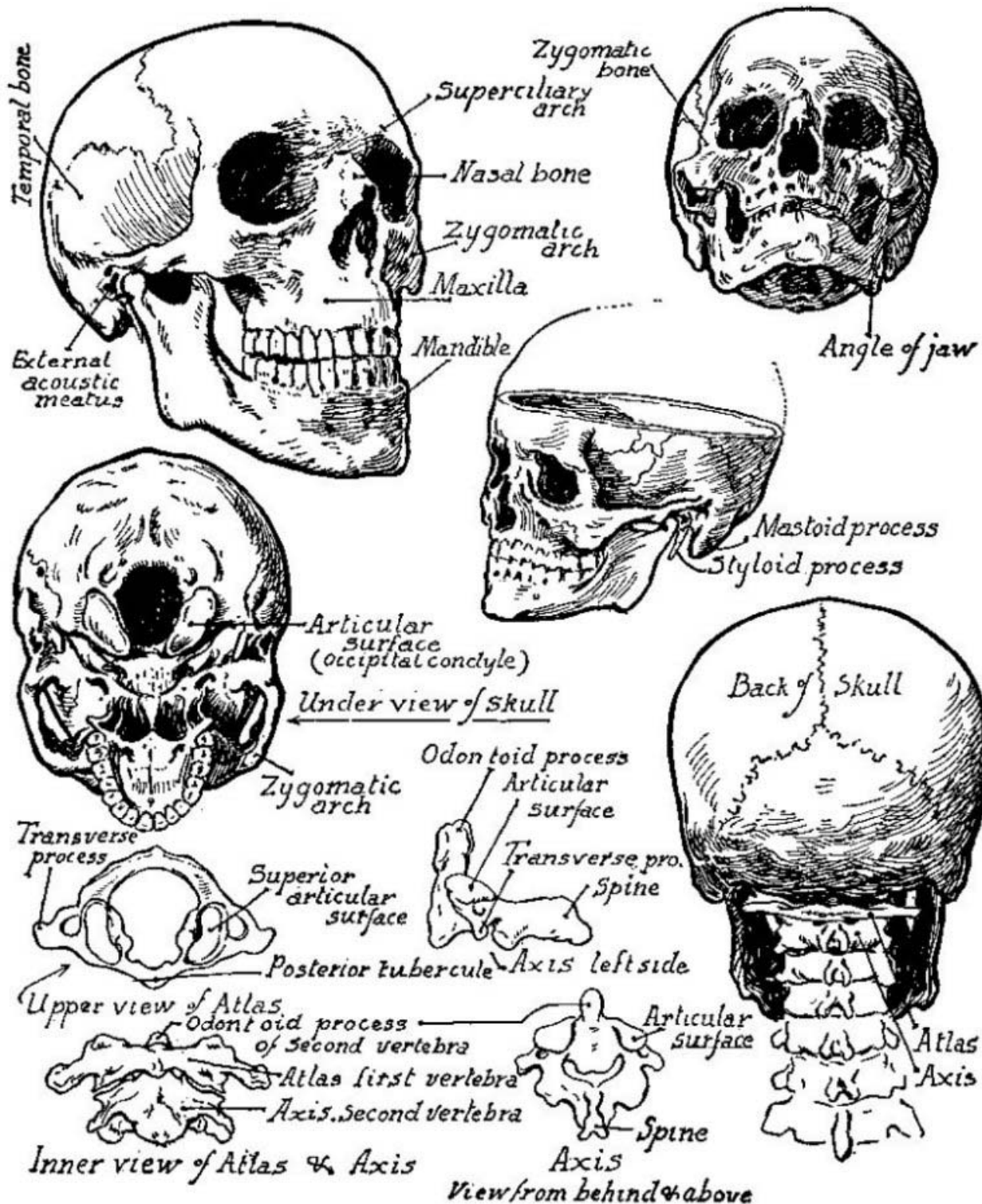
*The Head*  
&  
*Neck*

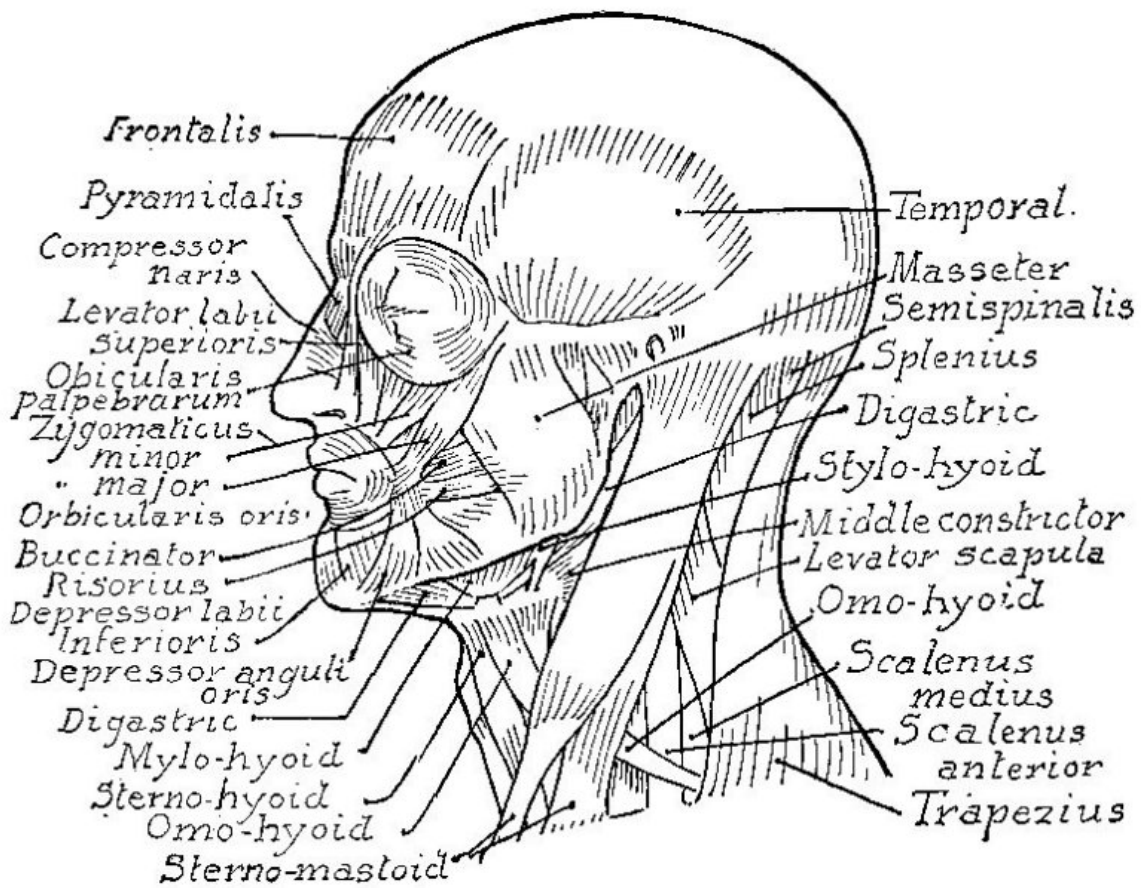
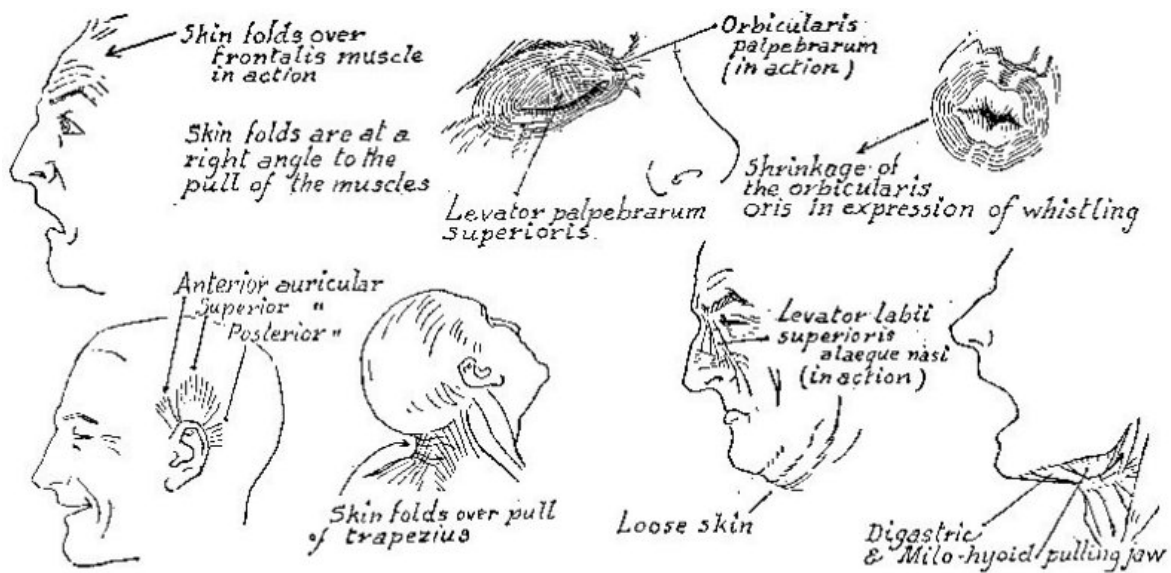


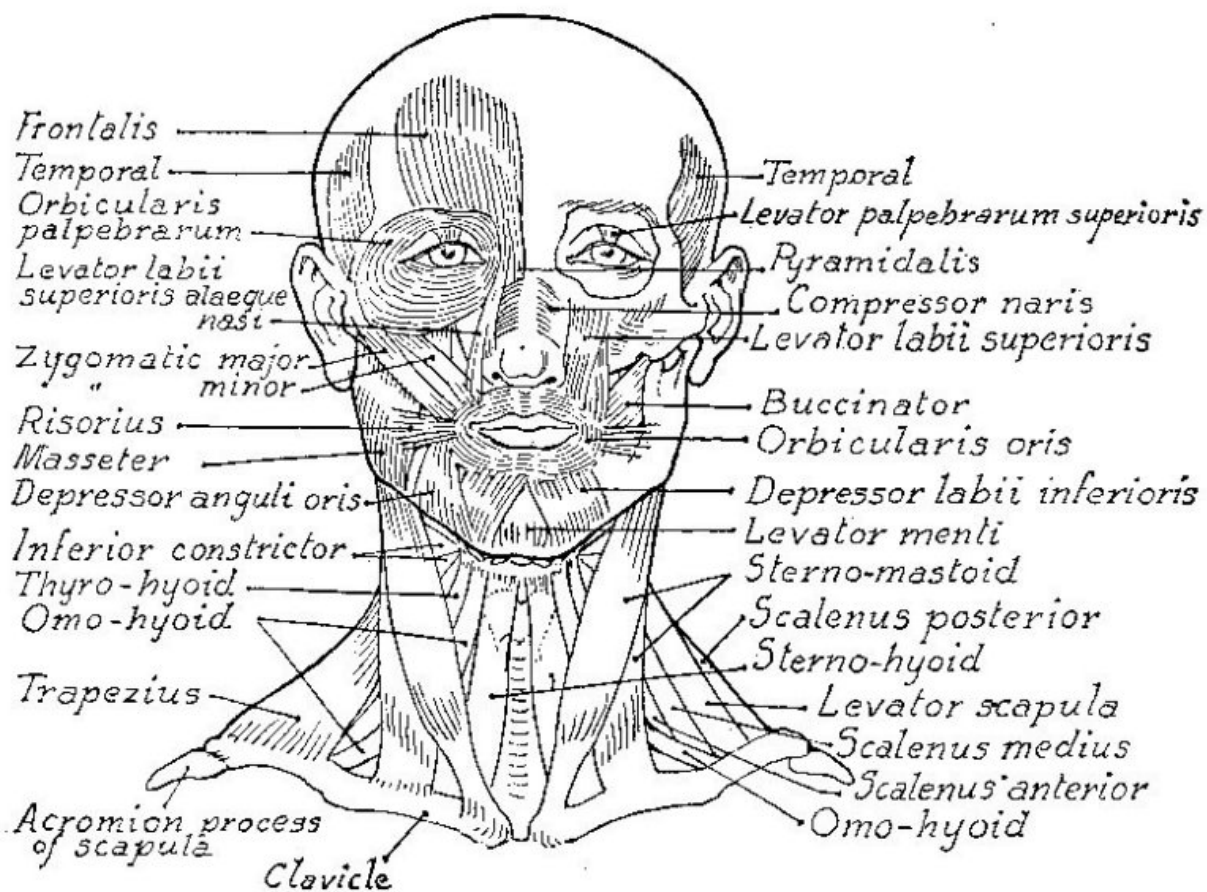
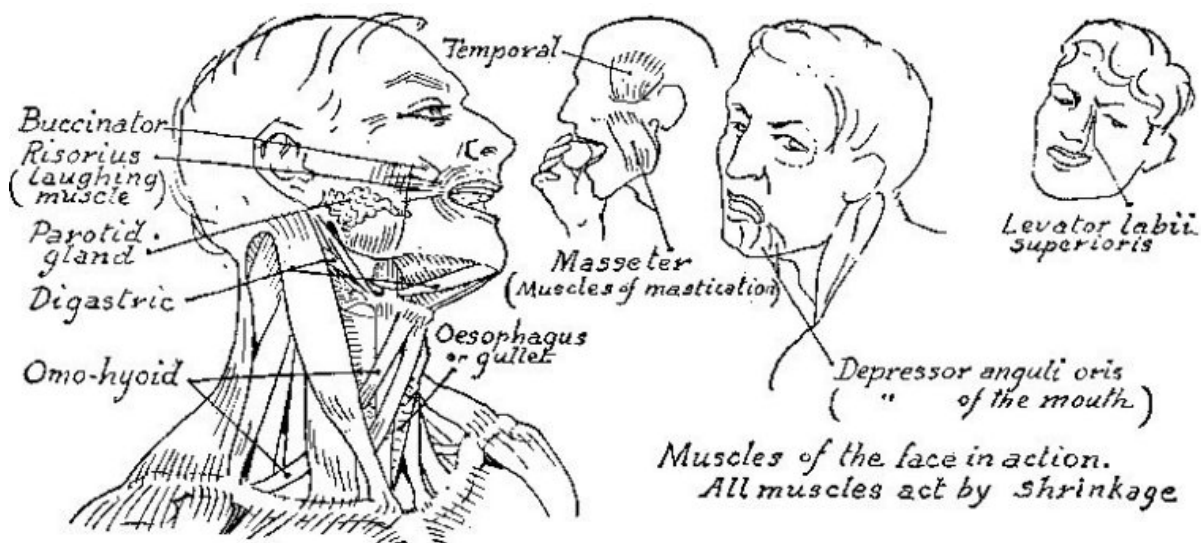


# The SKULL

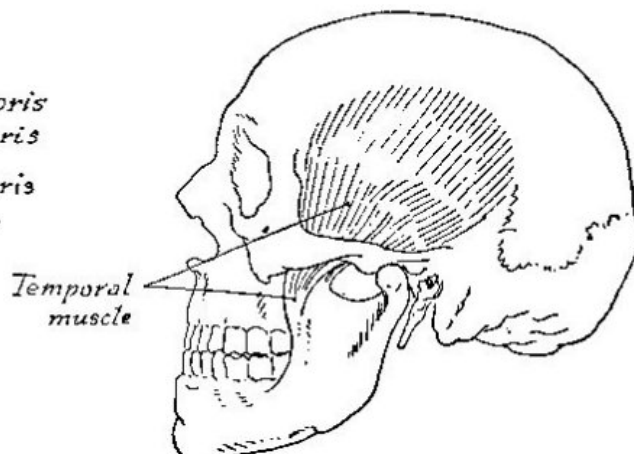
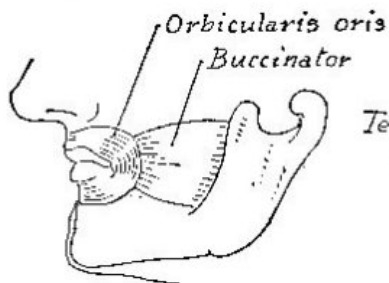
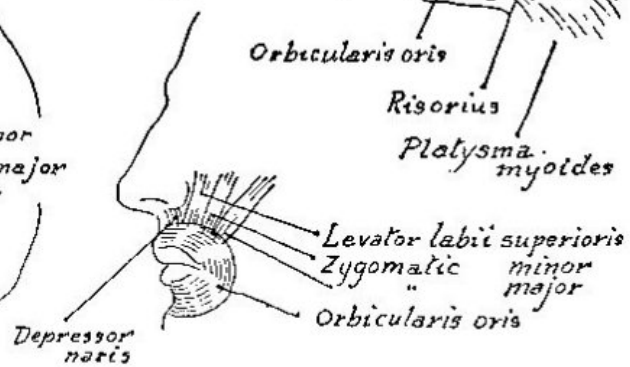
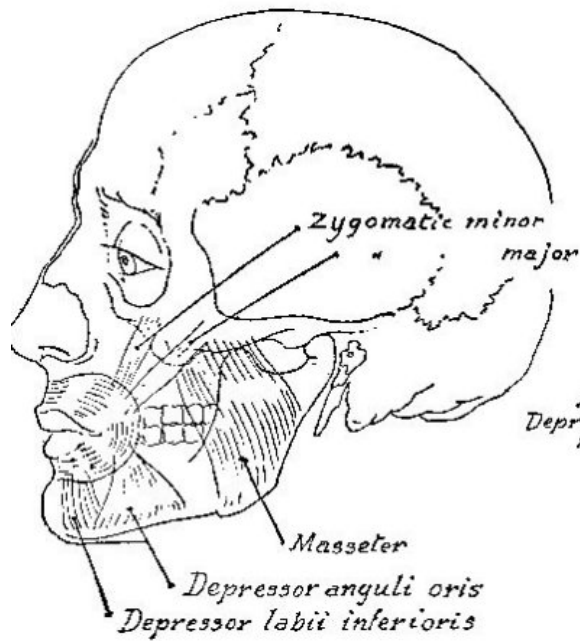
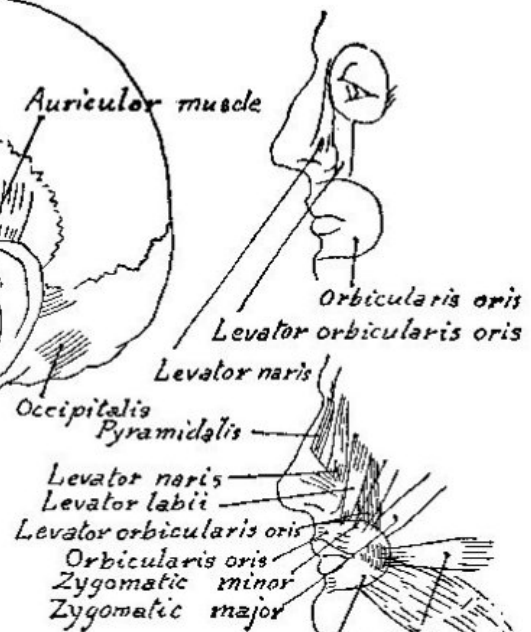
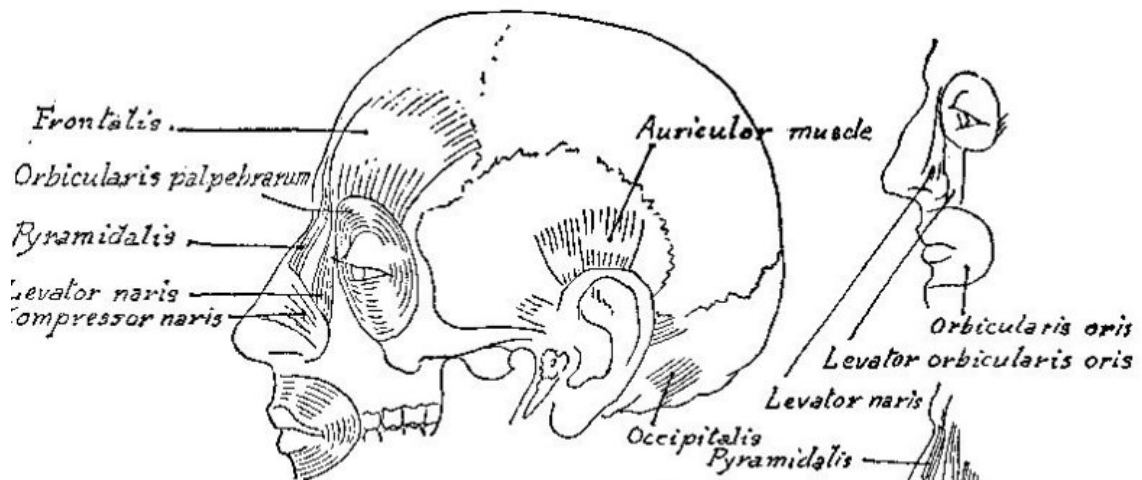


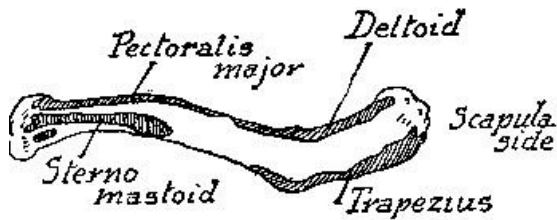




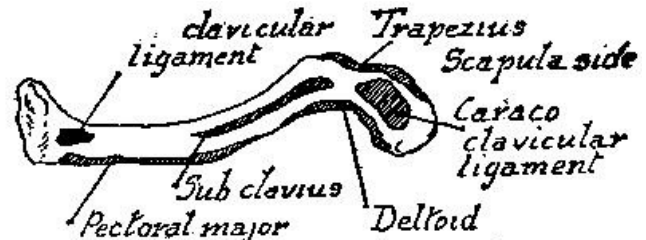


*The underlying and the superficial muscles of the face and neck*

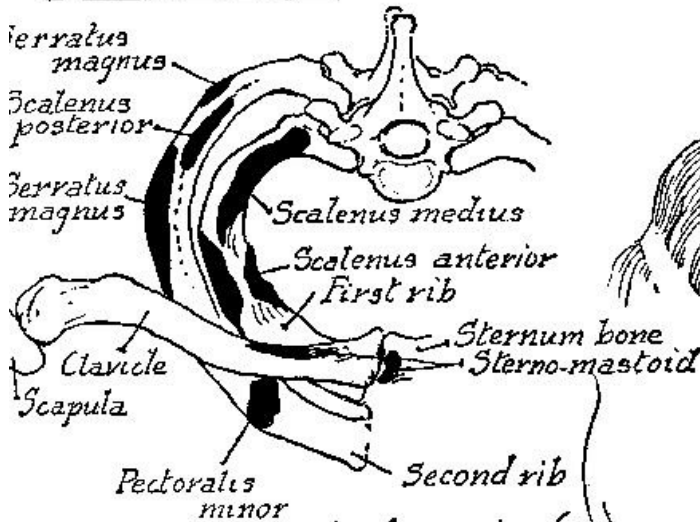




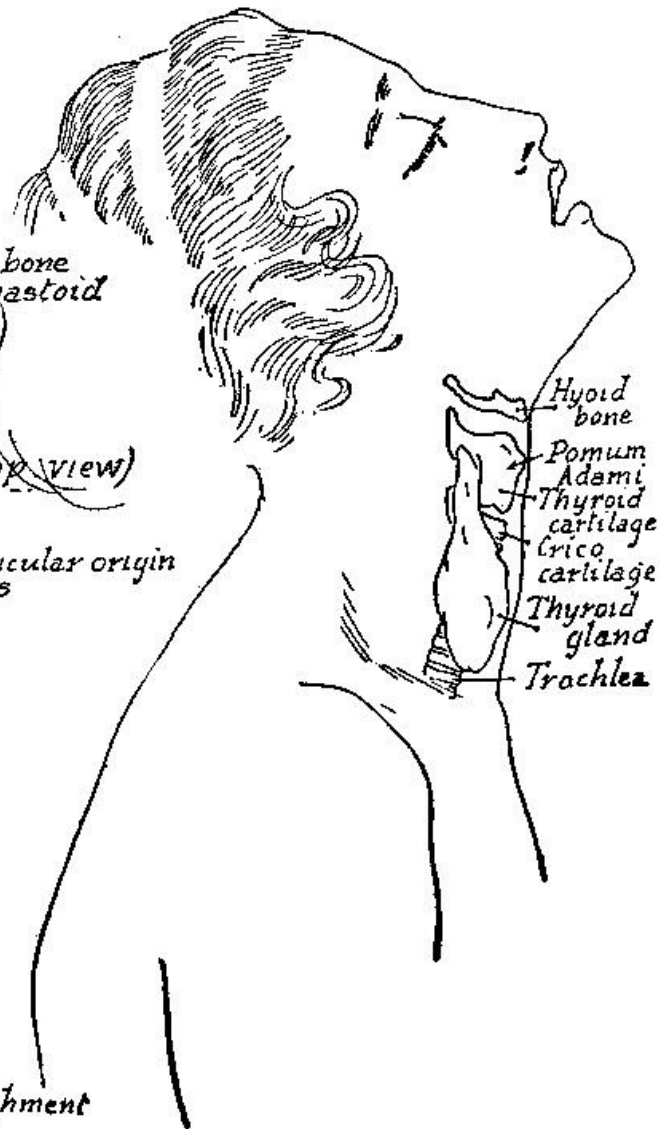
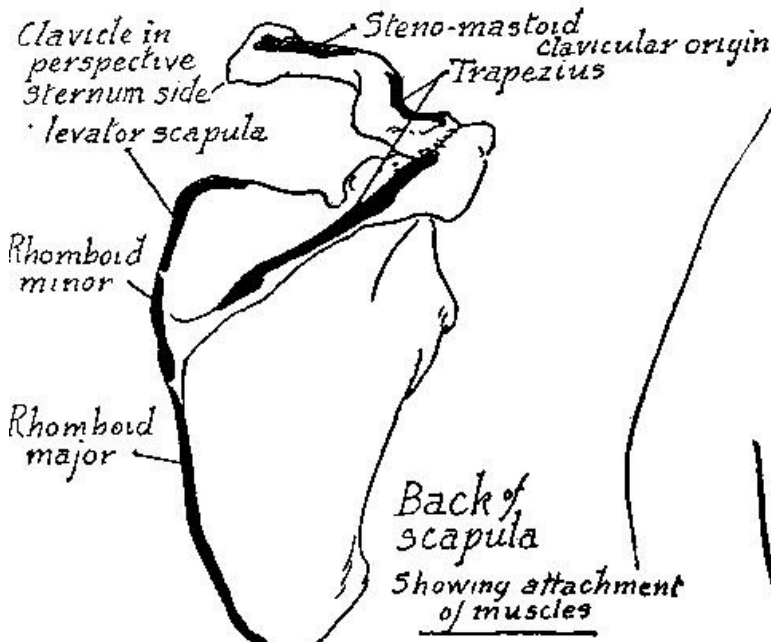
Attachment of muscles on upper surface of clavicle



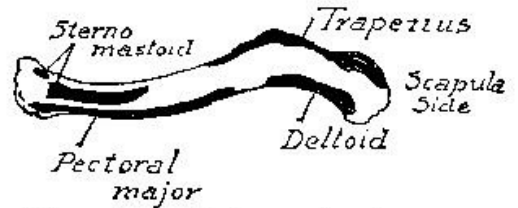
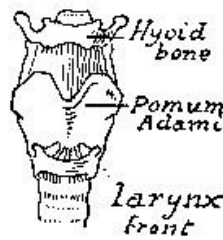
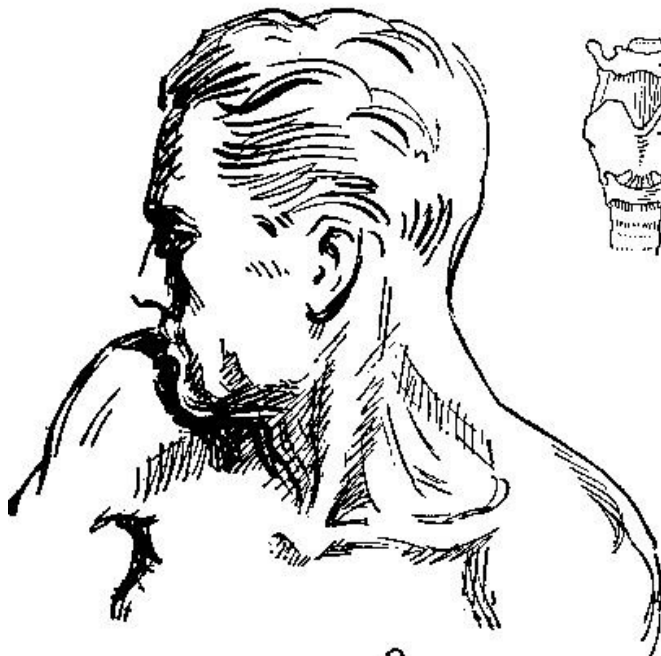
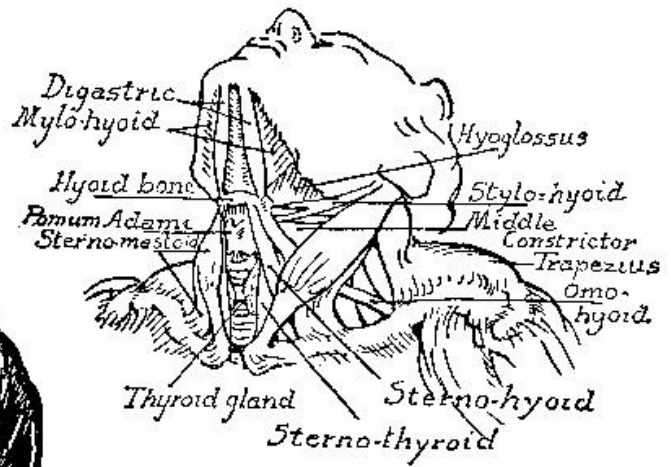
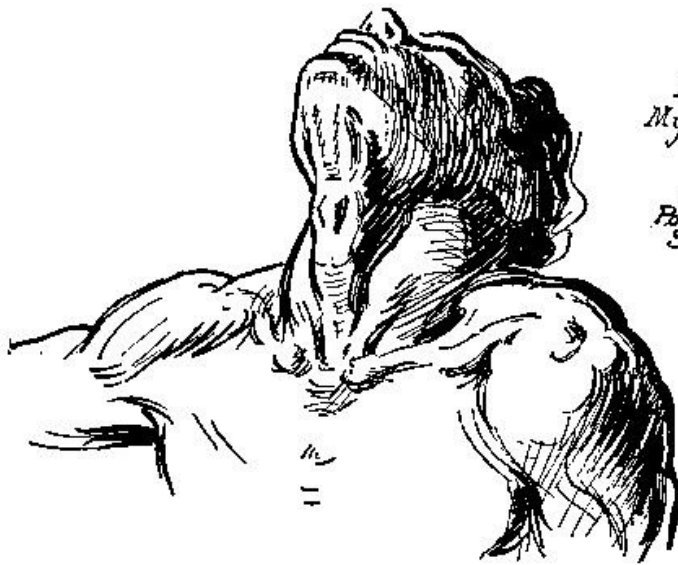Attachment of muscles on under surface of clavicle



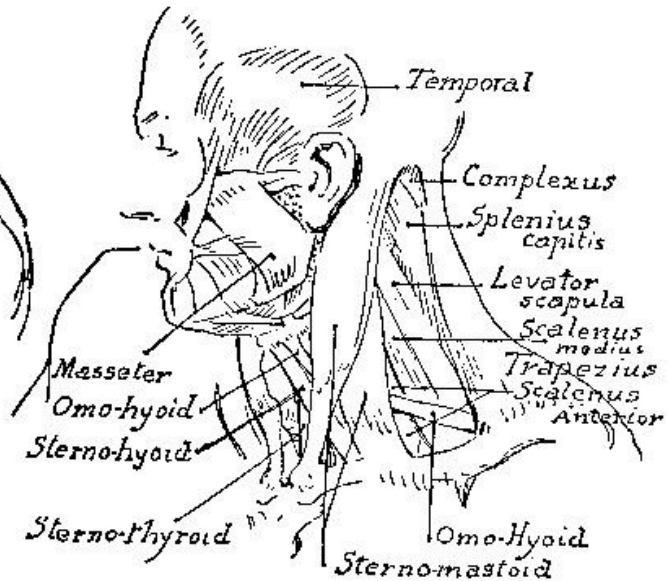
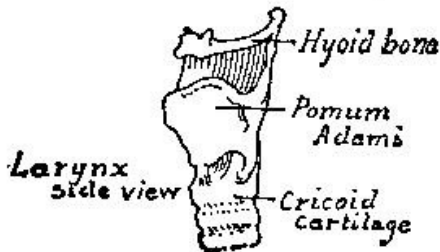
Attachments of muscles (Top view)

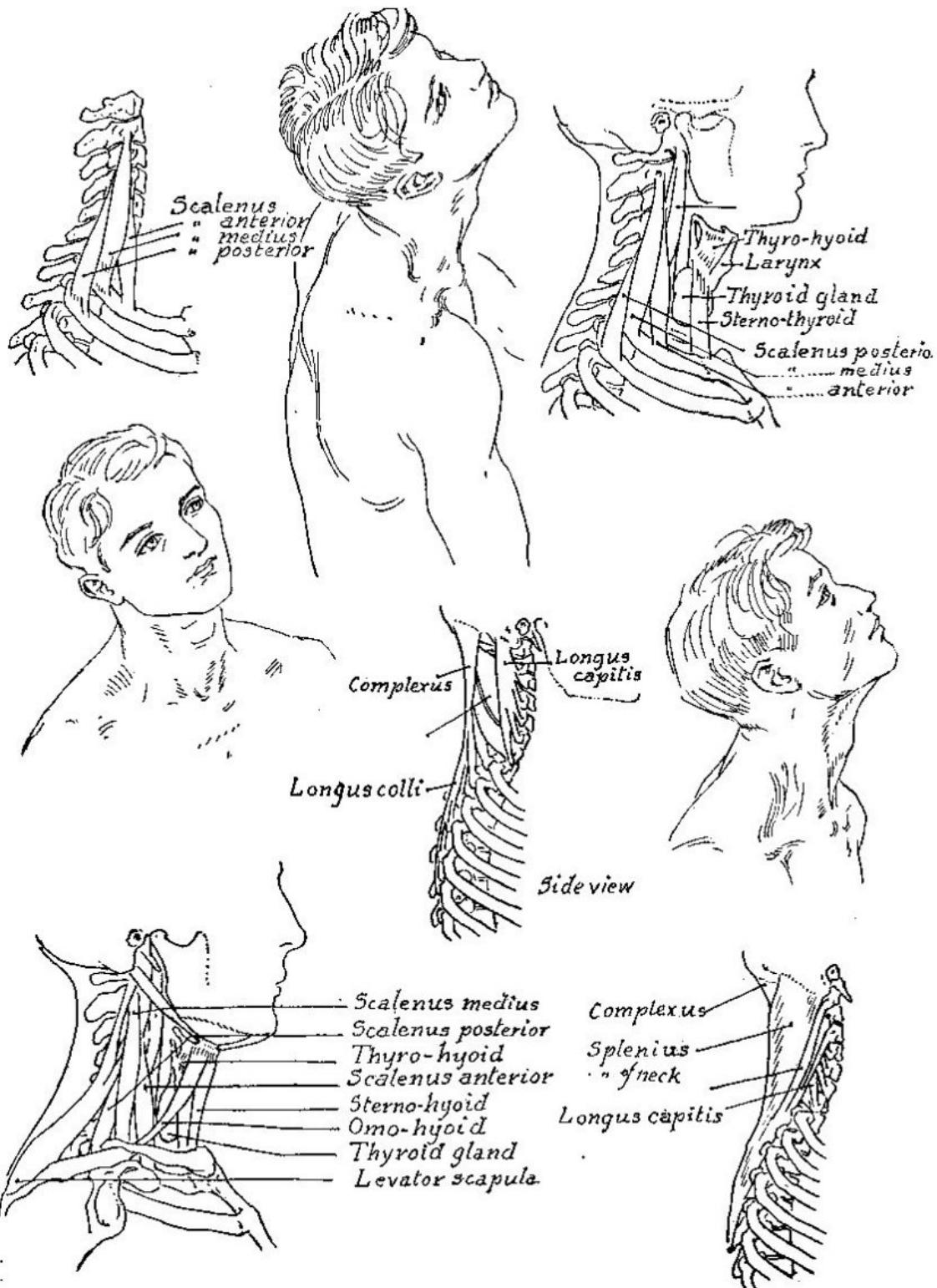




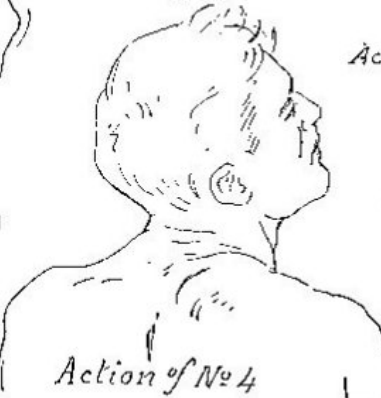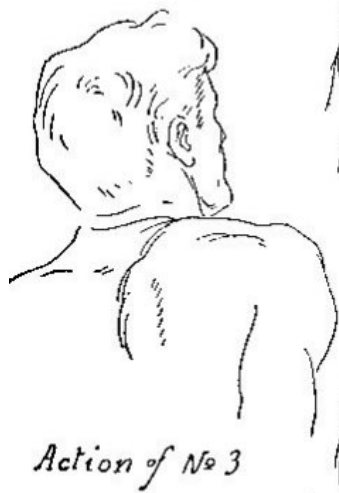
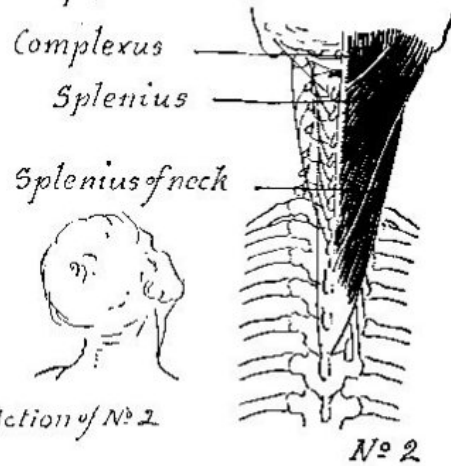
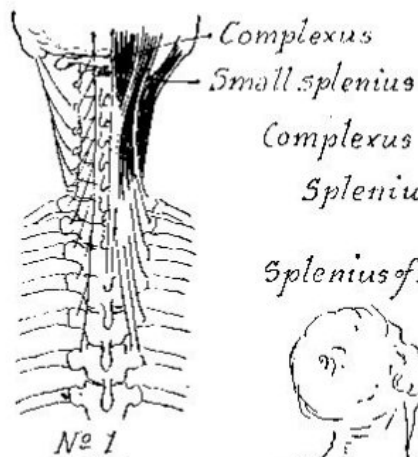

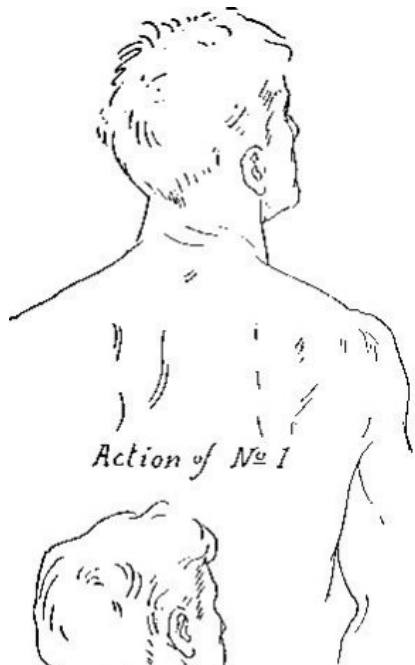
Top view of clavicle showing attachment of muscles

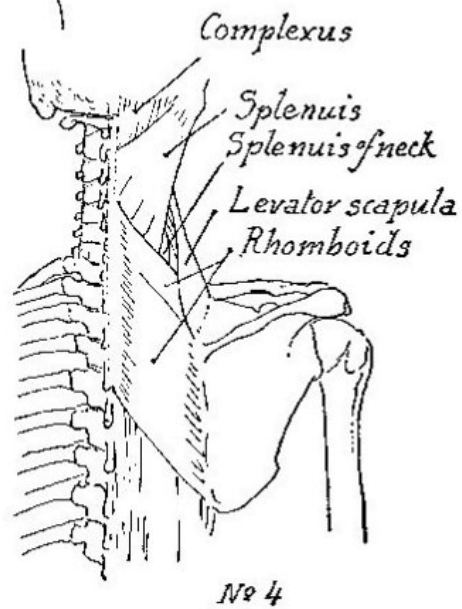
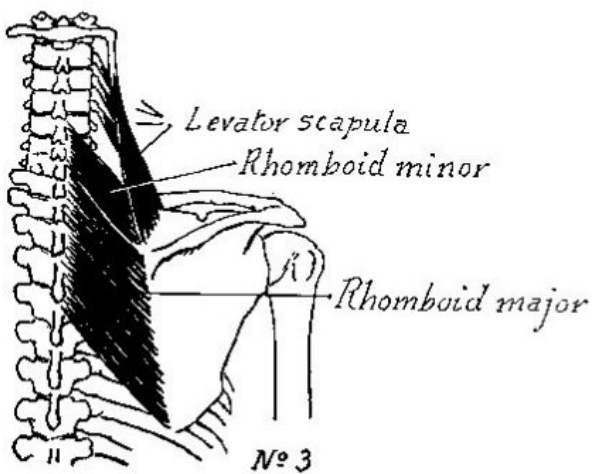


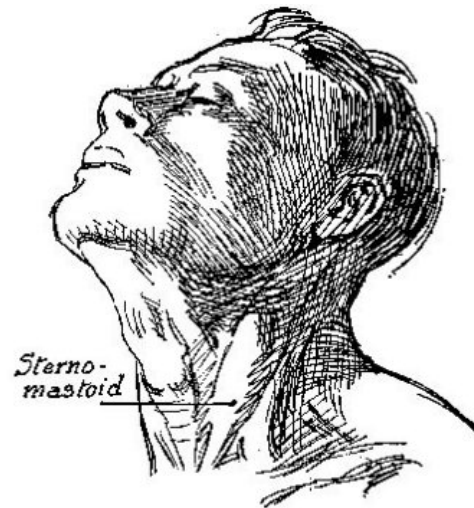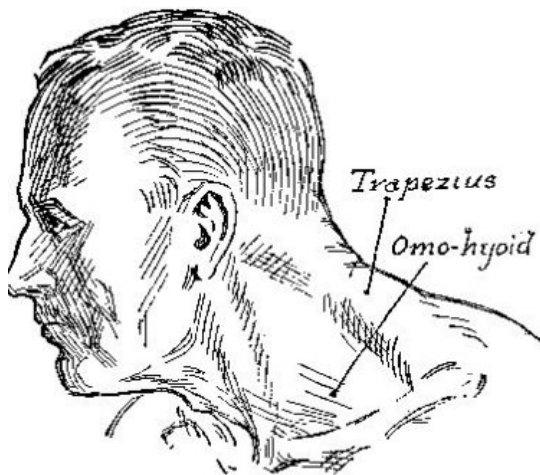




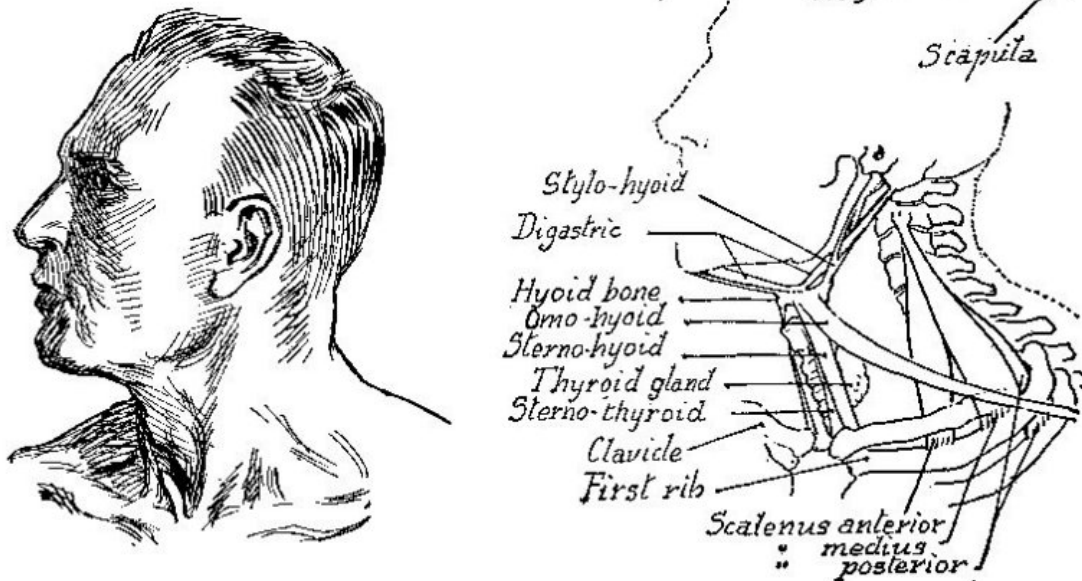
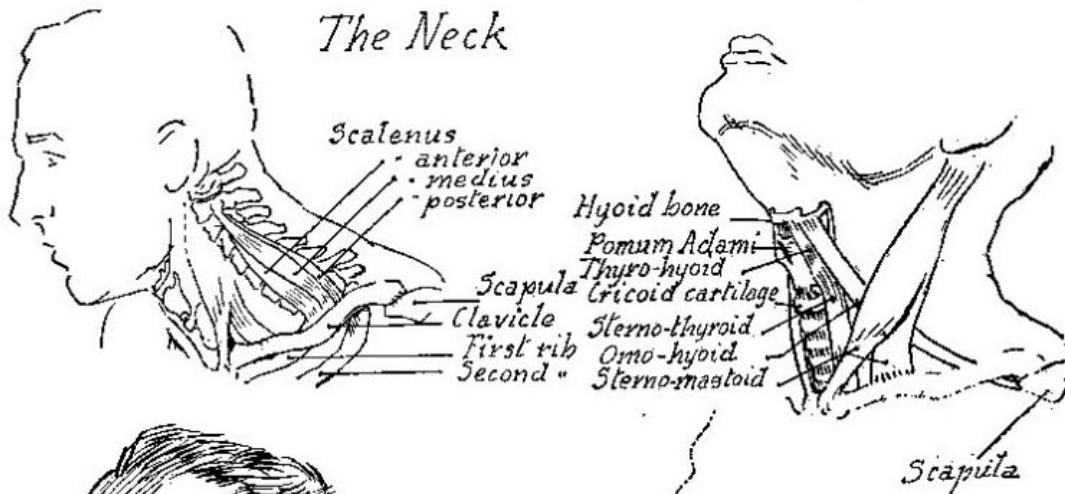


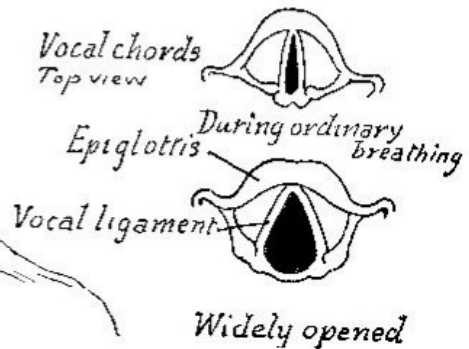
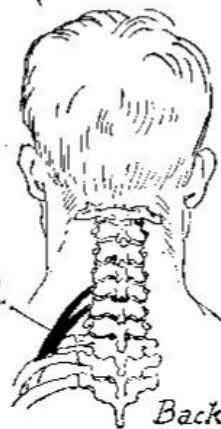
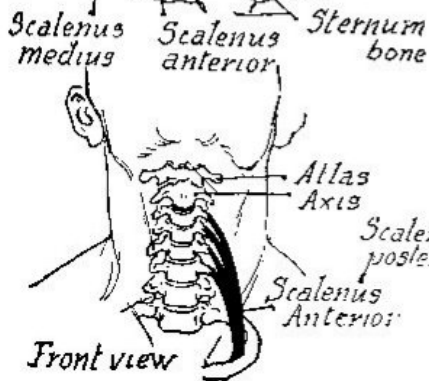
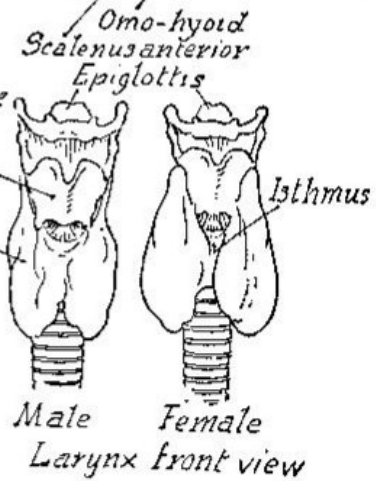
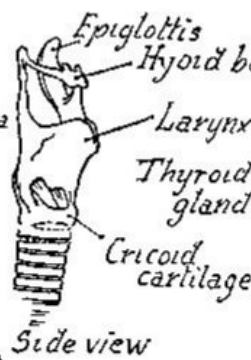
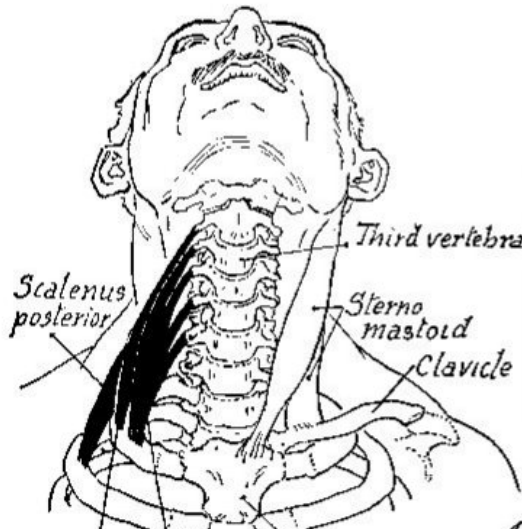
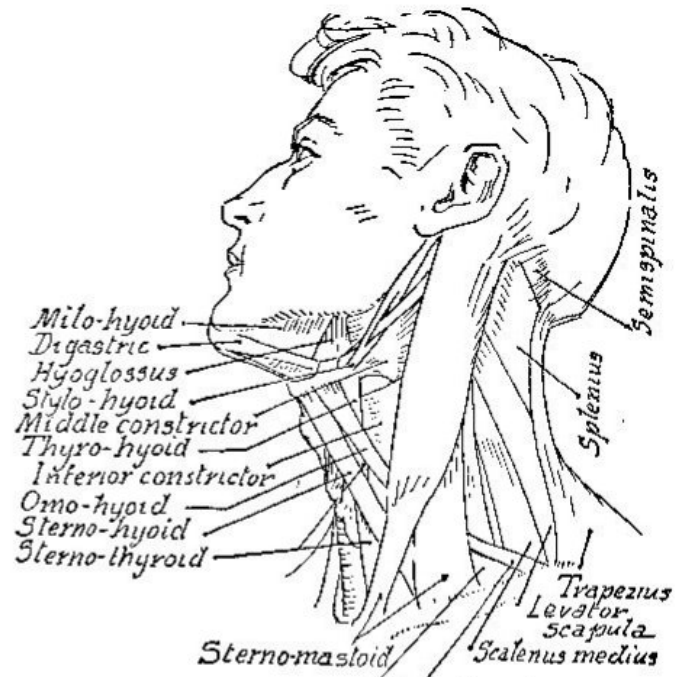
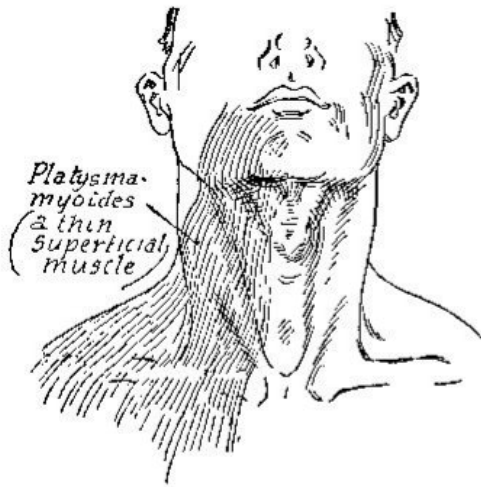
### Muscles of back of neck

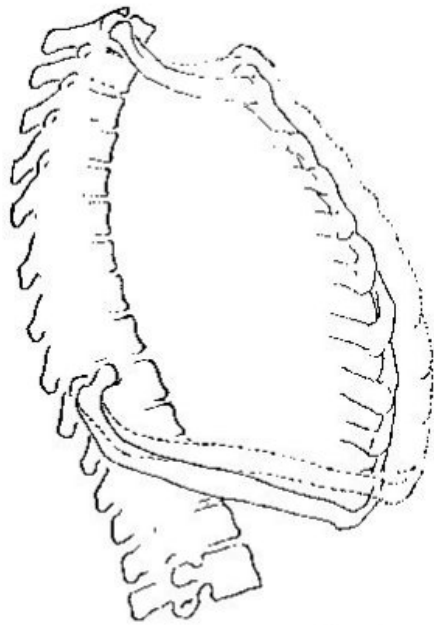




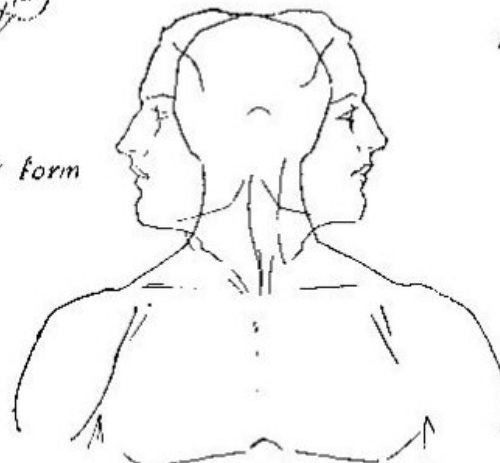
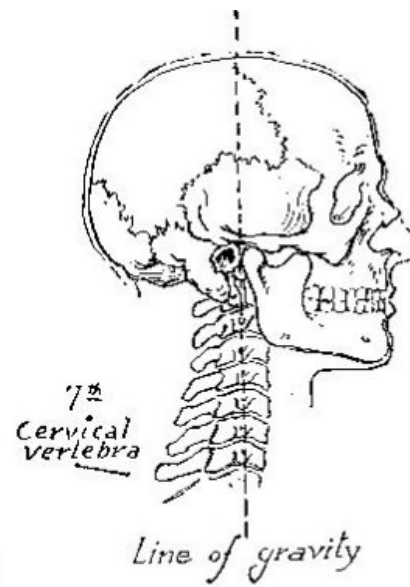
## The Neck



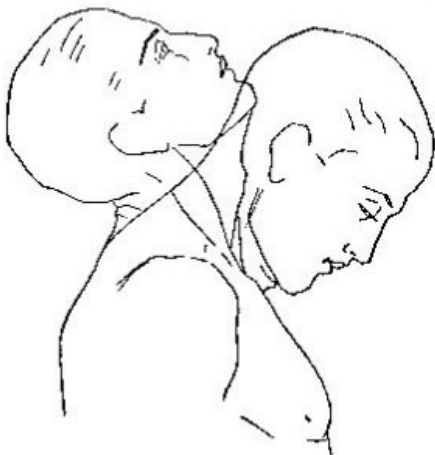




*Modification of chest form  
in breathing*



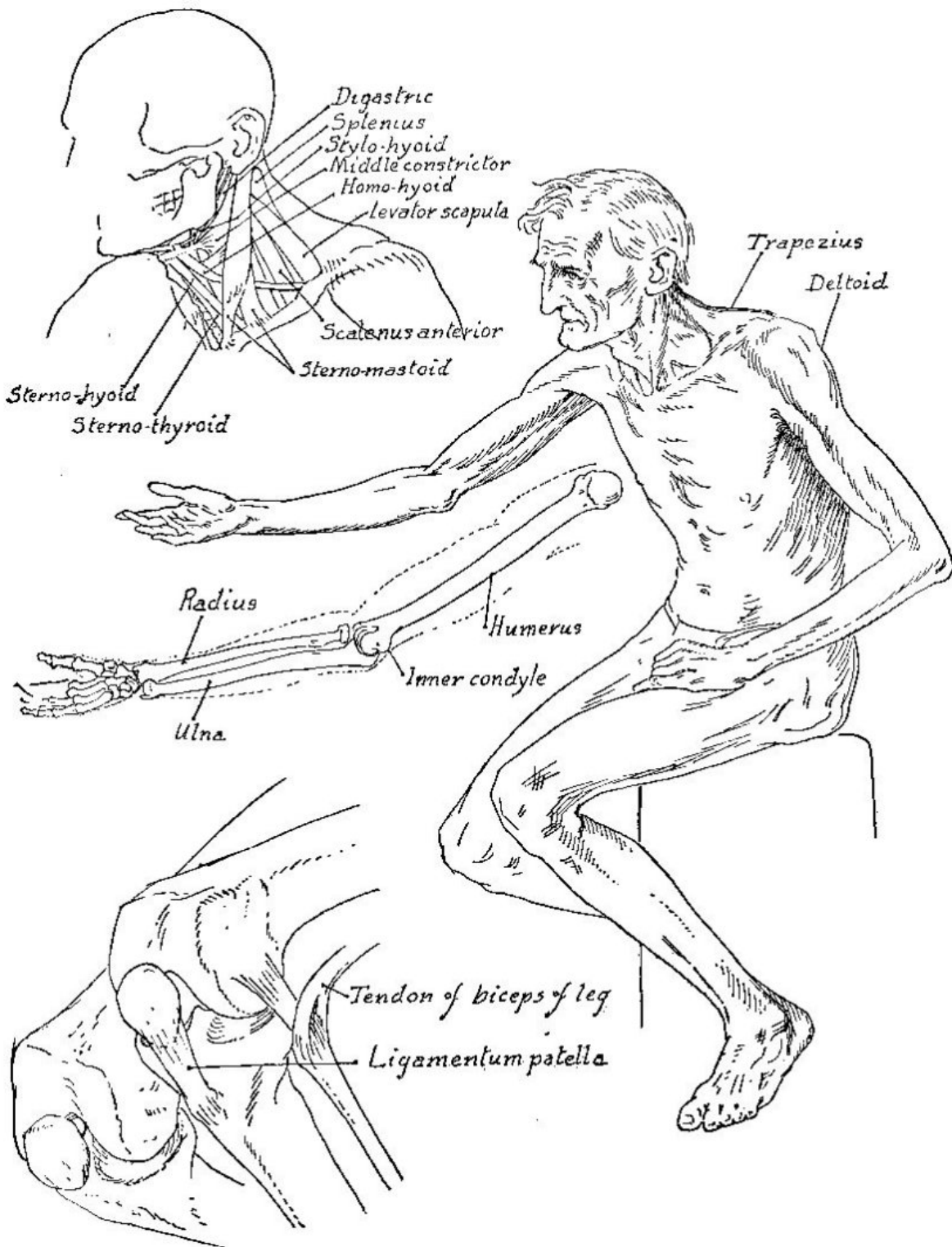
*Relation of head and  
neck to shoulders  
in extreme side  
movements*



*Extent of bending forward and back*



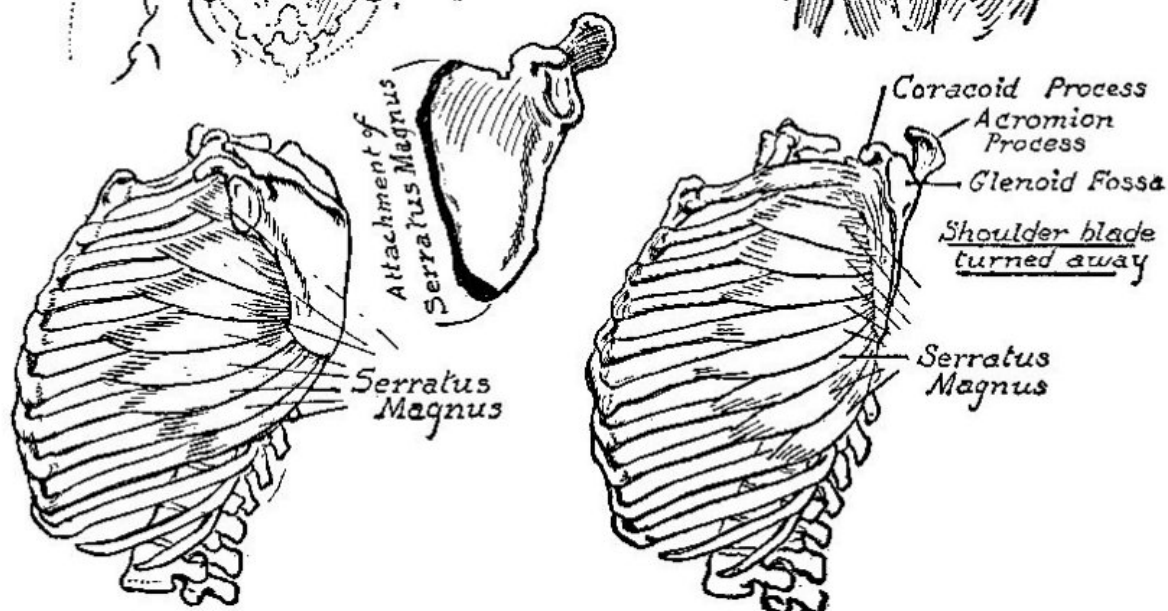
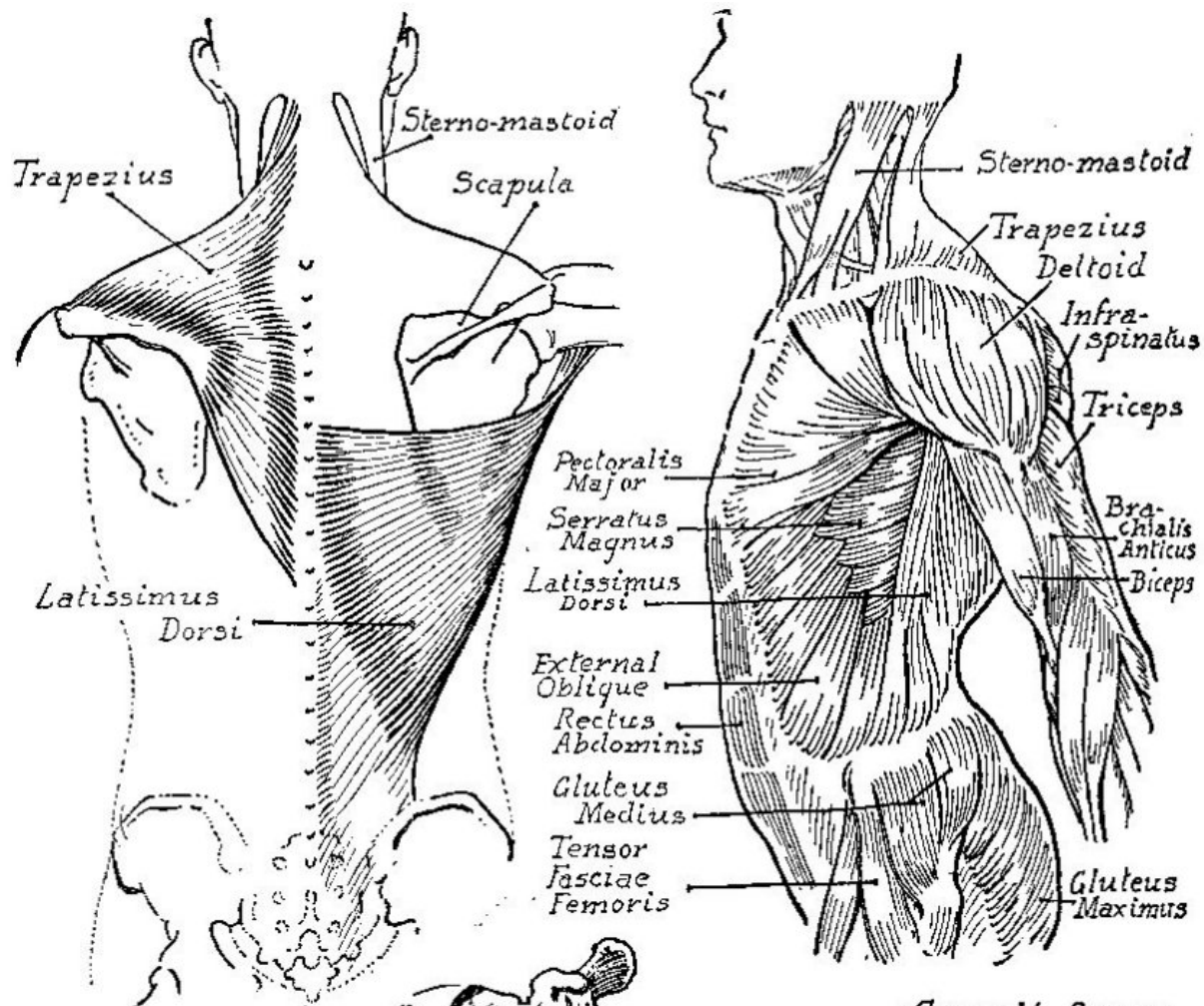
*Flexion of head  
without moving neck*

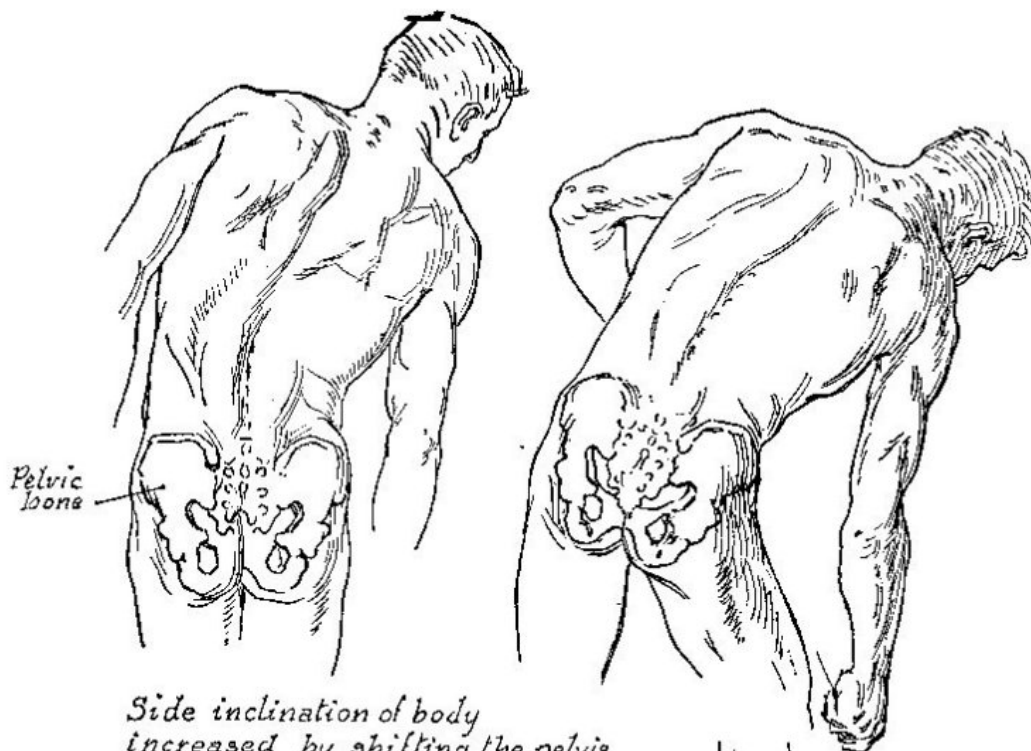




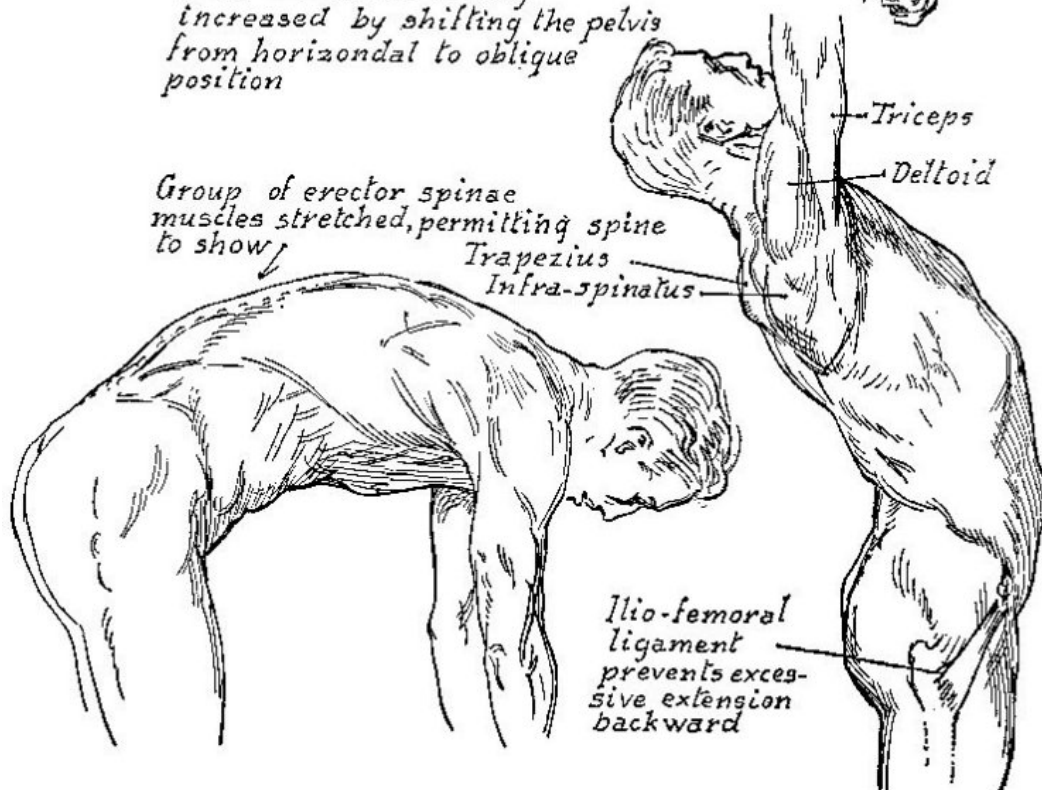
Part IV

## *The Torso*

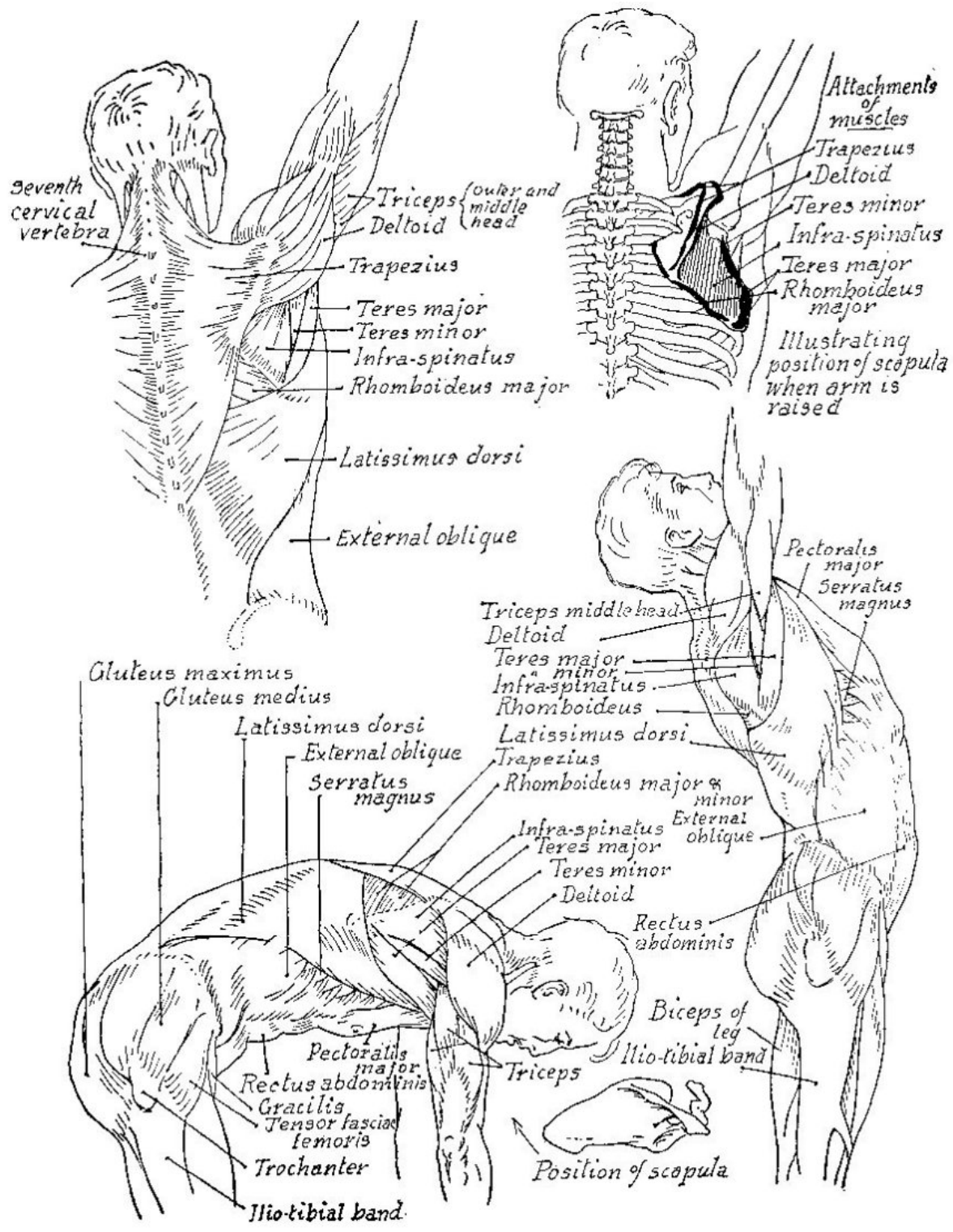


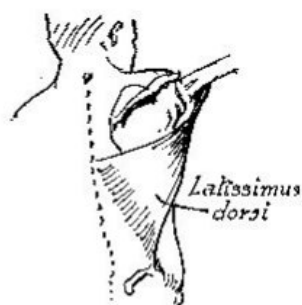
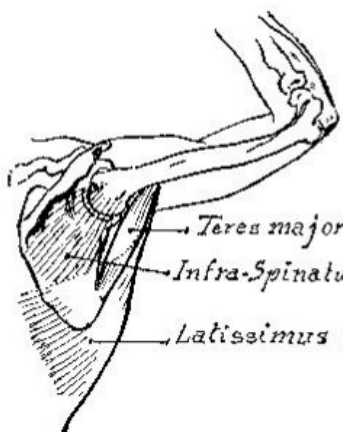
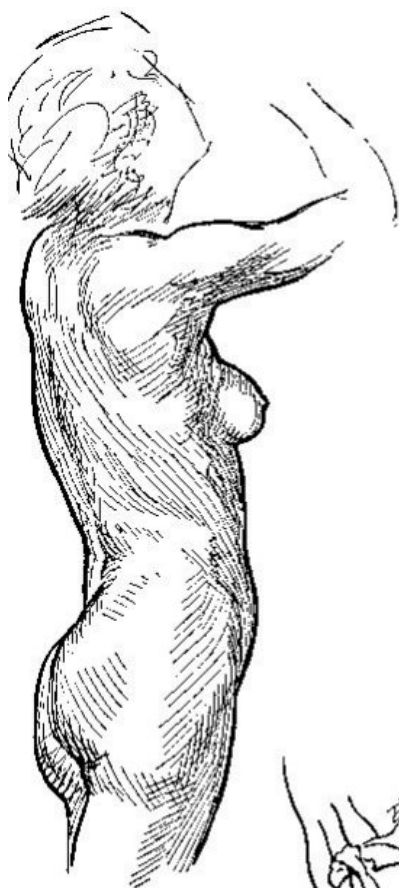


*Side inclination of body  
increased by shifting the pelvis  
from horizontal to oblique  
position*







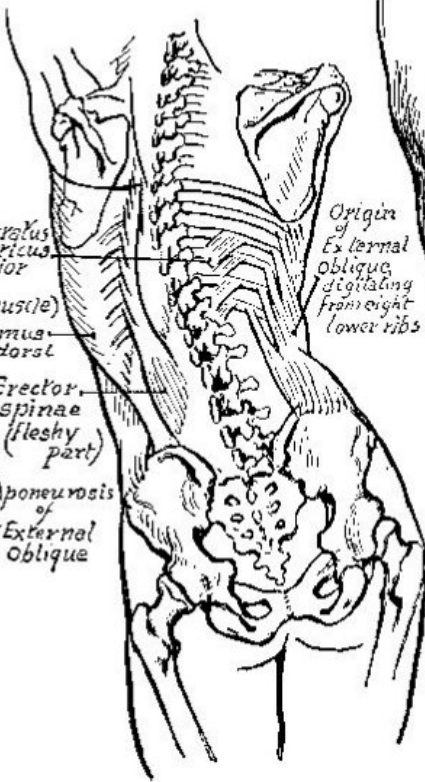


*Teres major*

*Infra-Spinatus and Teres minor*

*Latissimus dorsi*

*Latissimus dorsi*

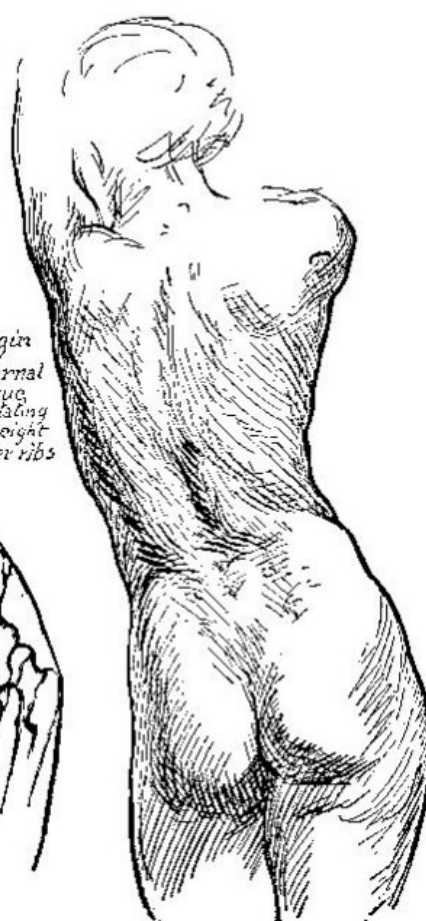
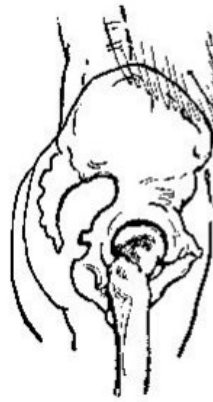
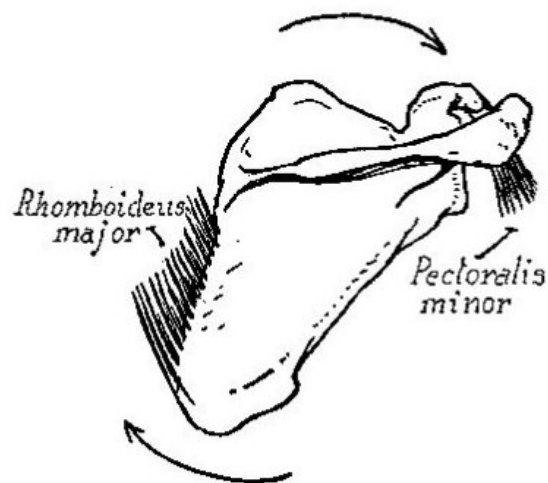
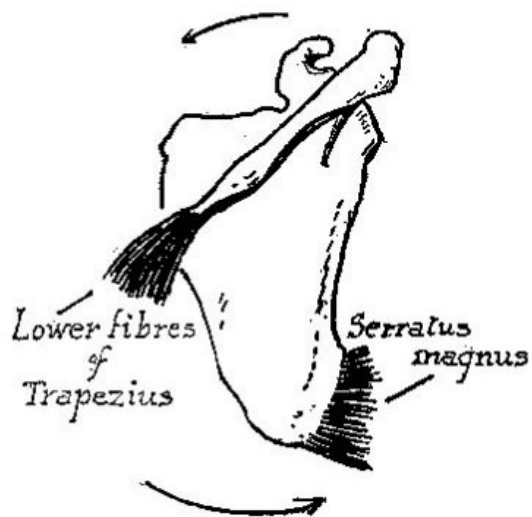
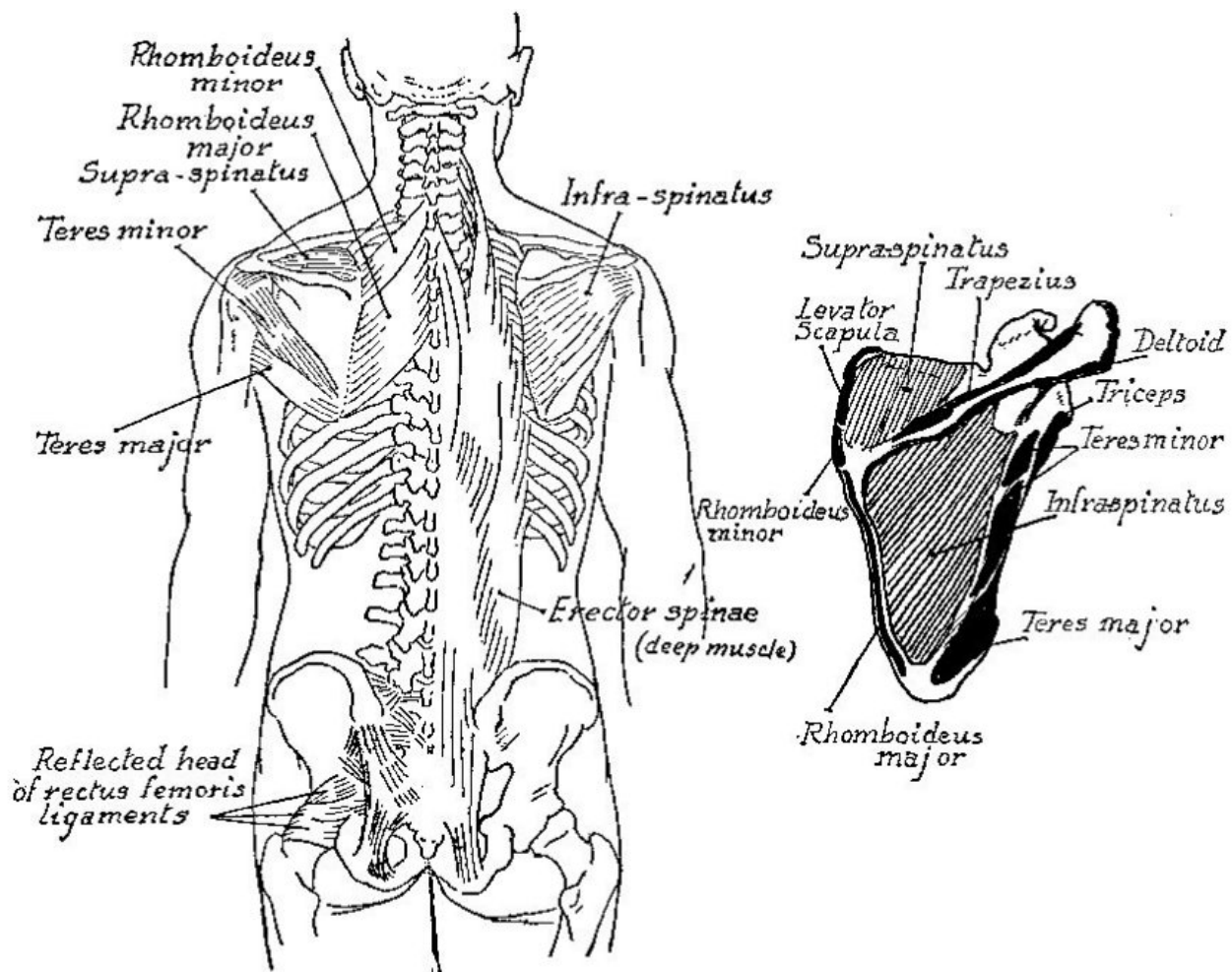
*Serratus posterior inferior (deep muscle)*  
*Latissimus dorsi*

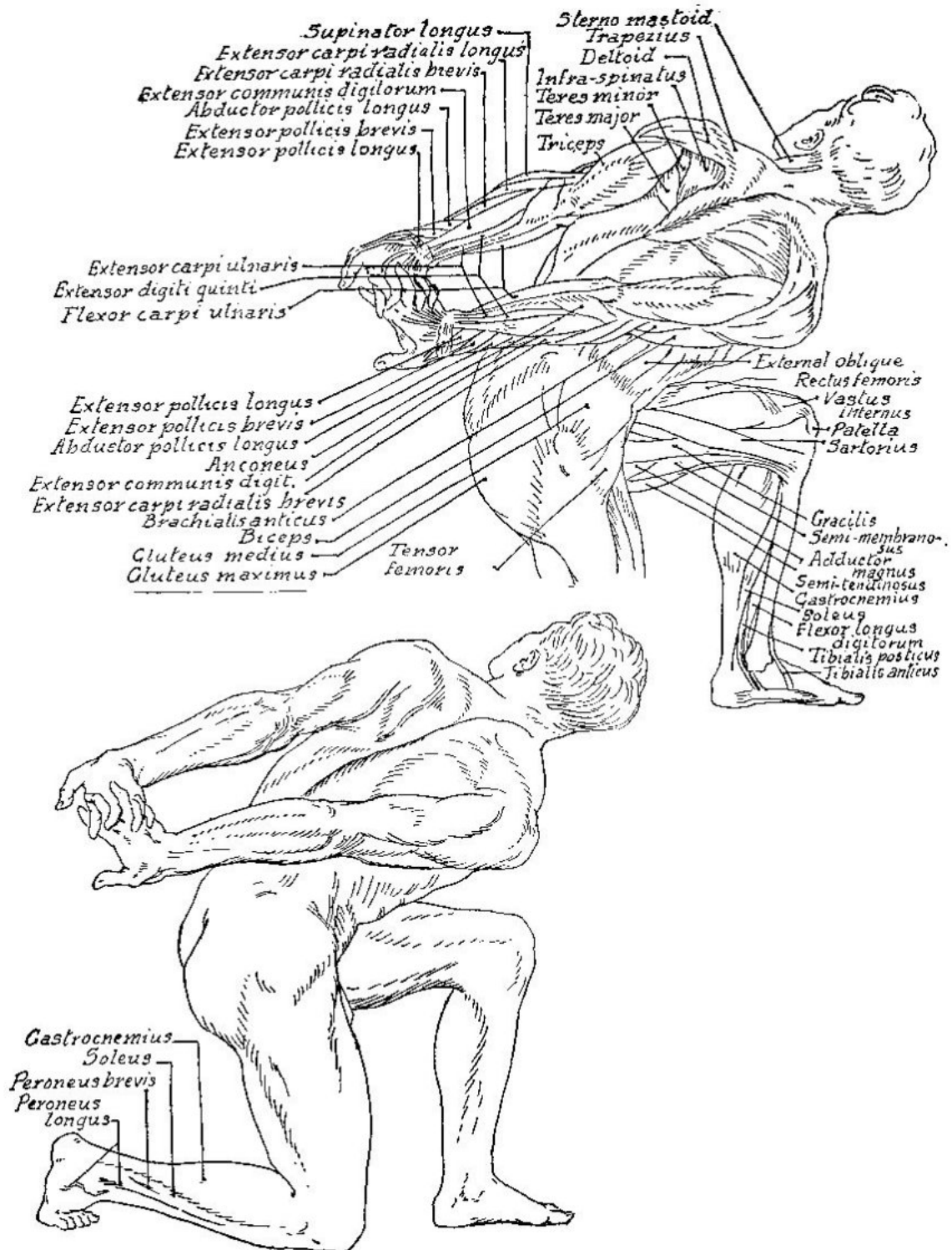
*Erector spinae (fleshy part)*

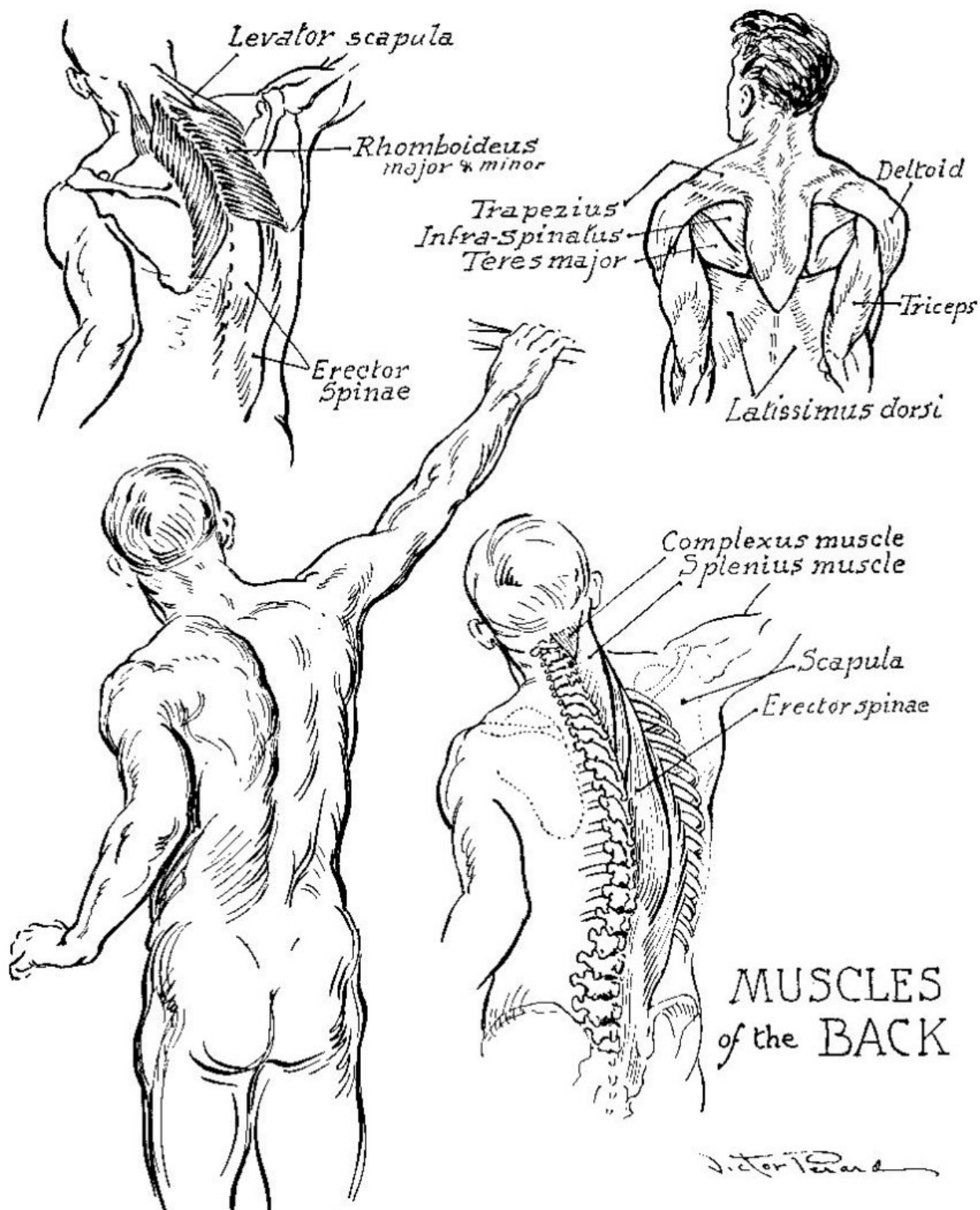
*Aponeurosis of External Oblique*

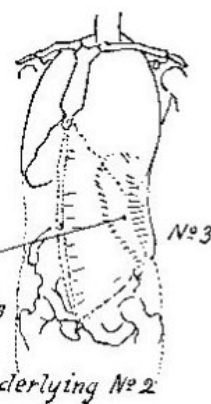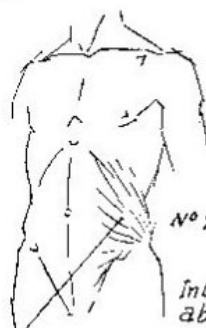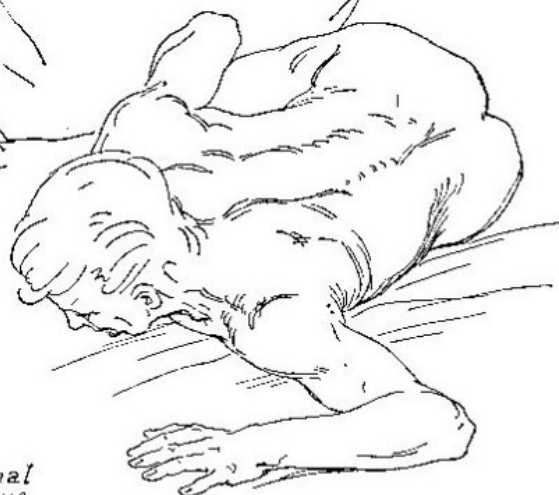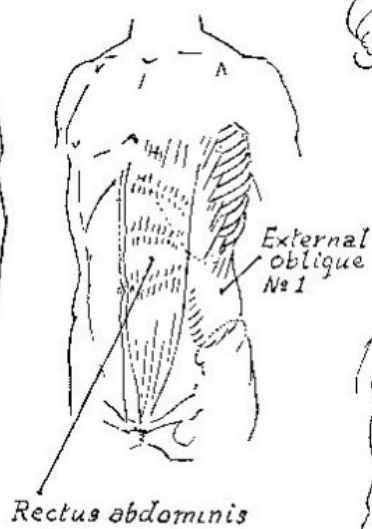
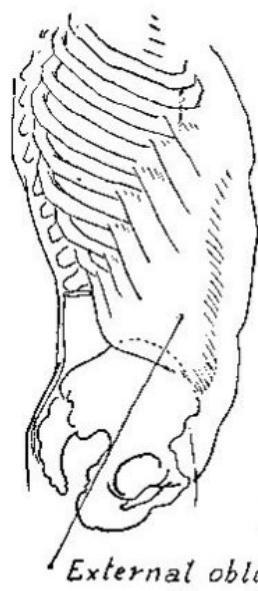
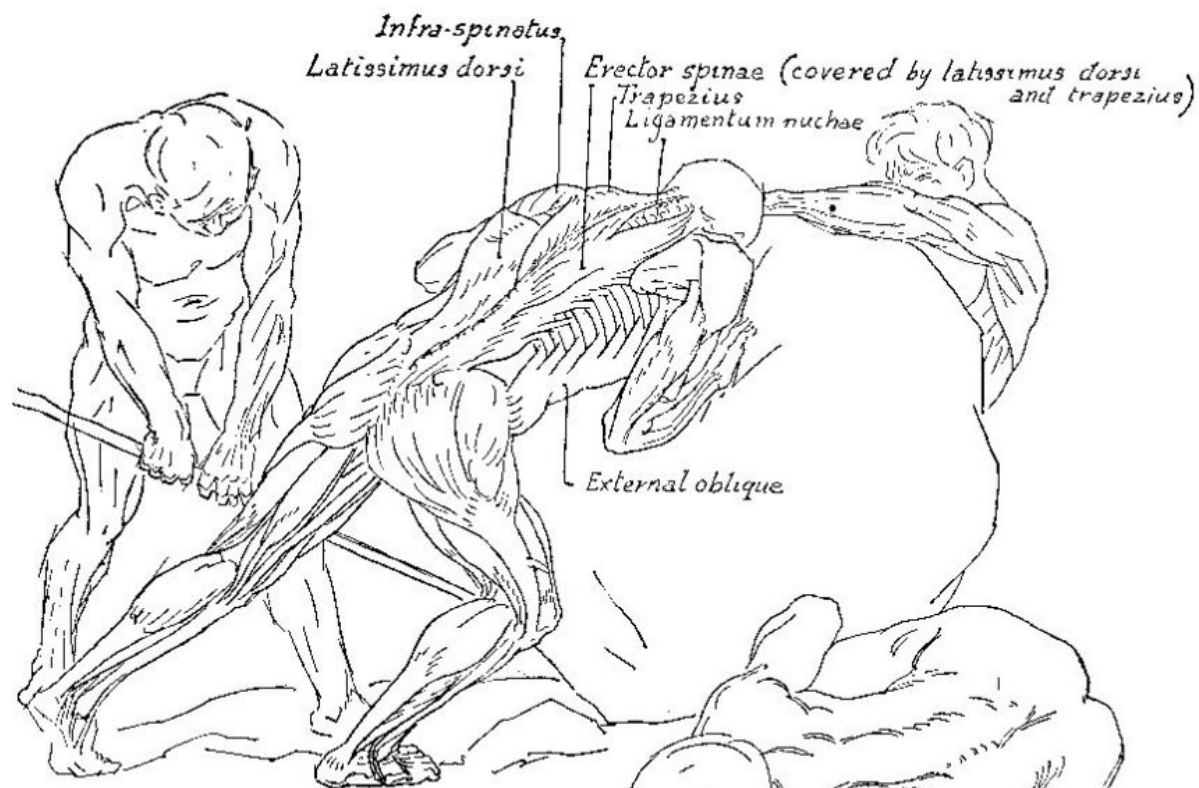
*Origin of External oblique, digitating from eight lower ribs*

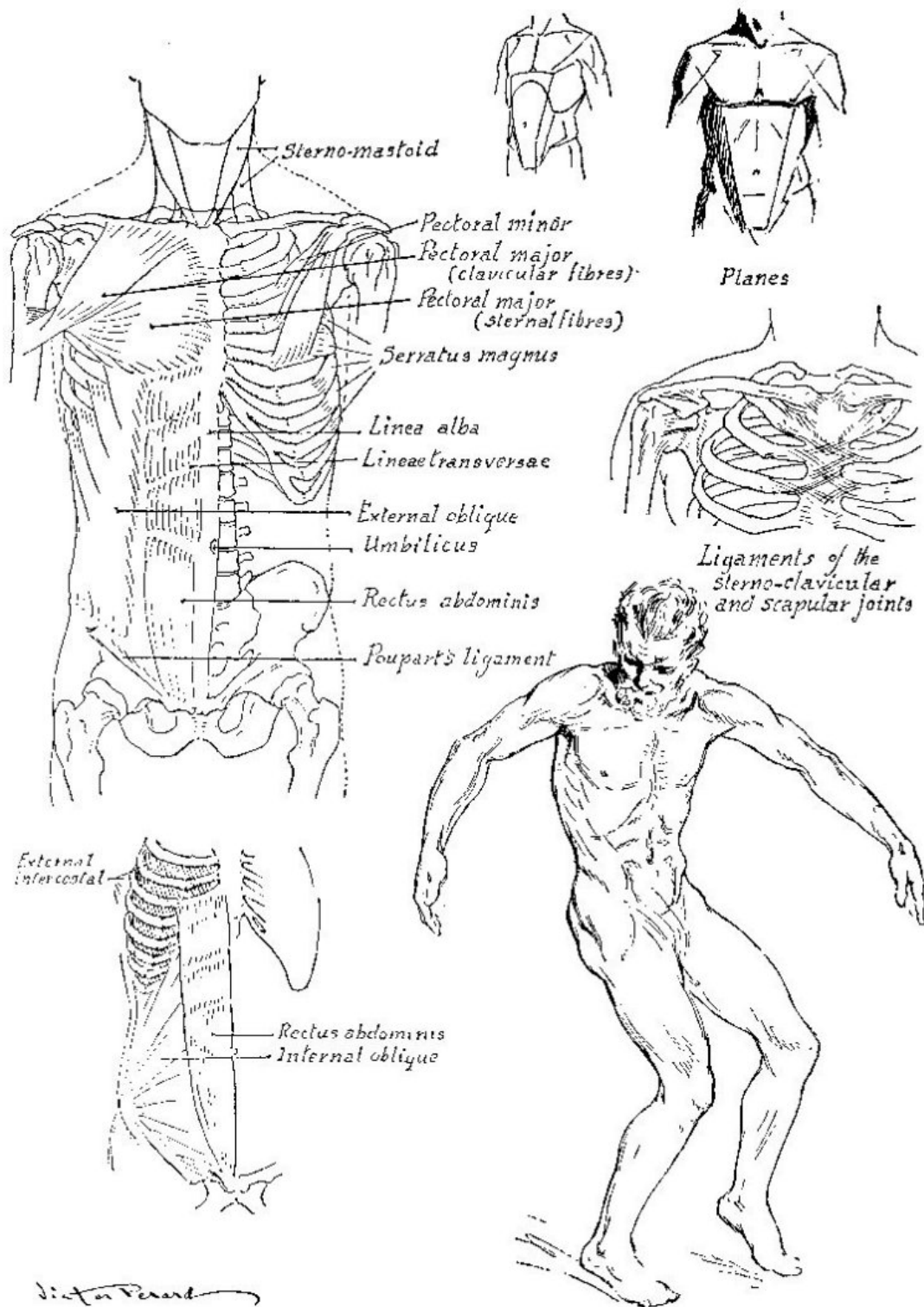




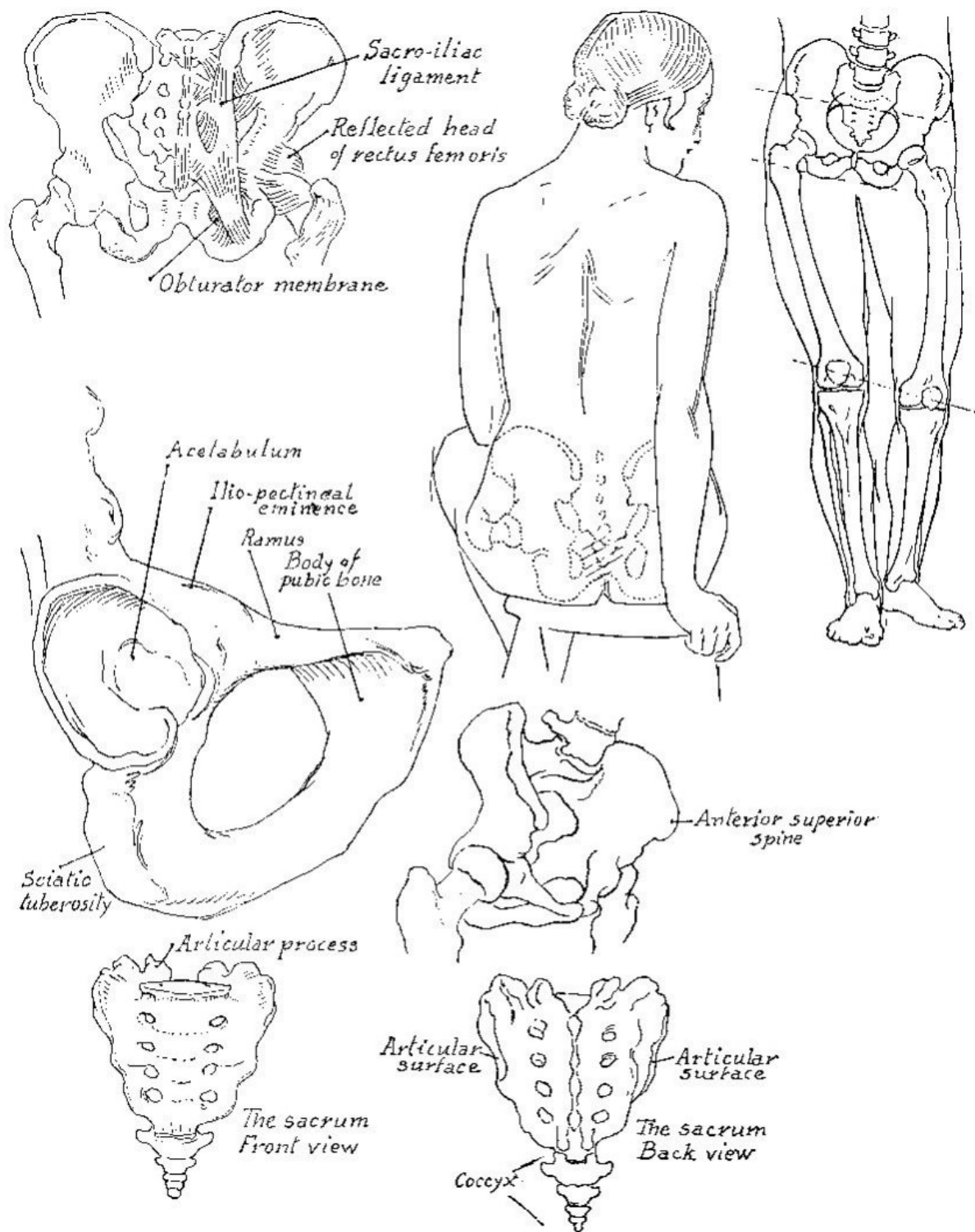




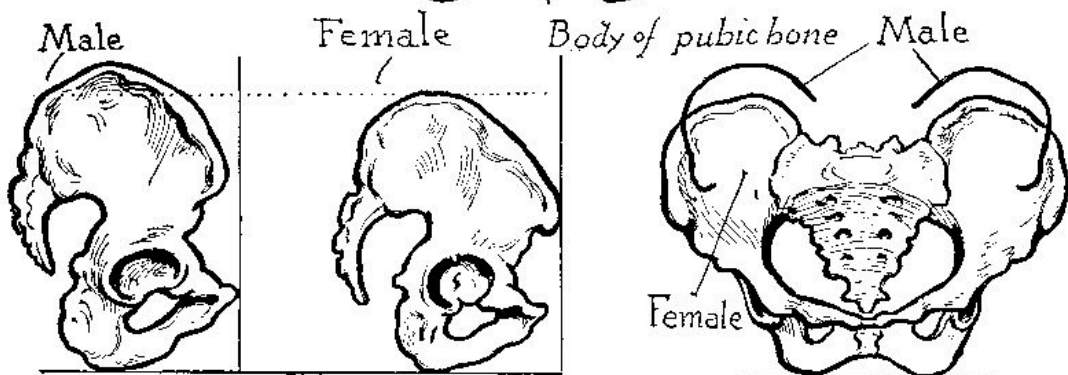
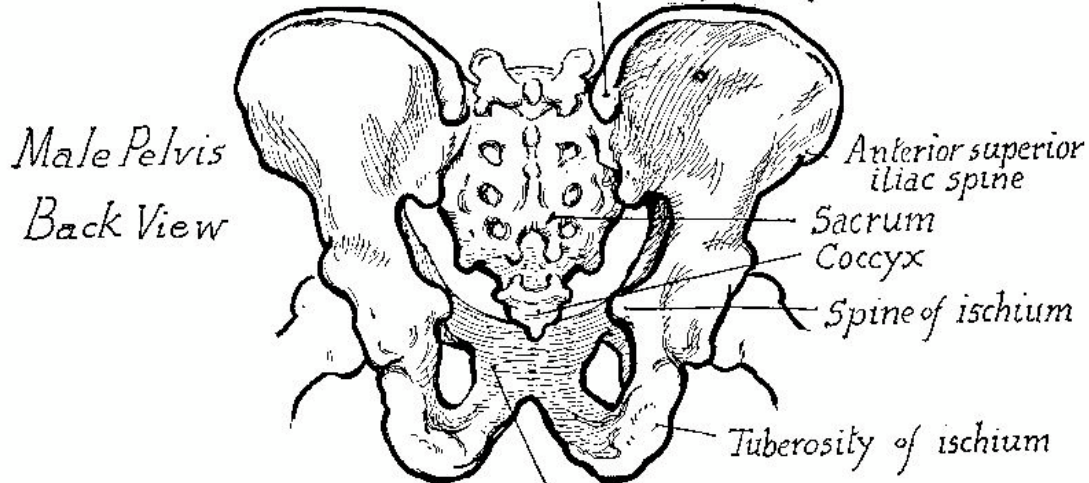
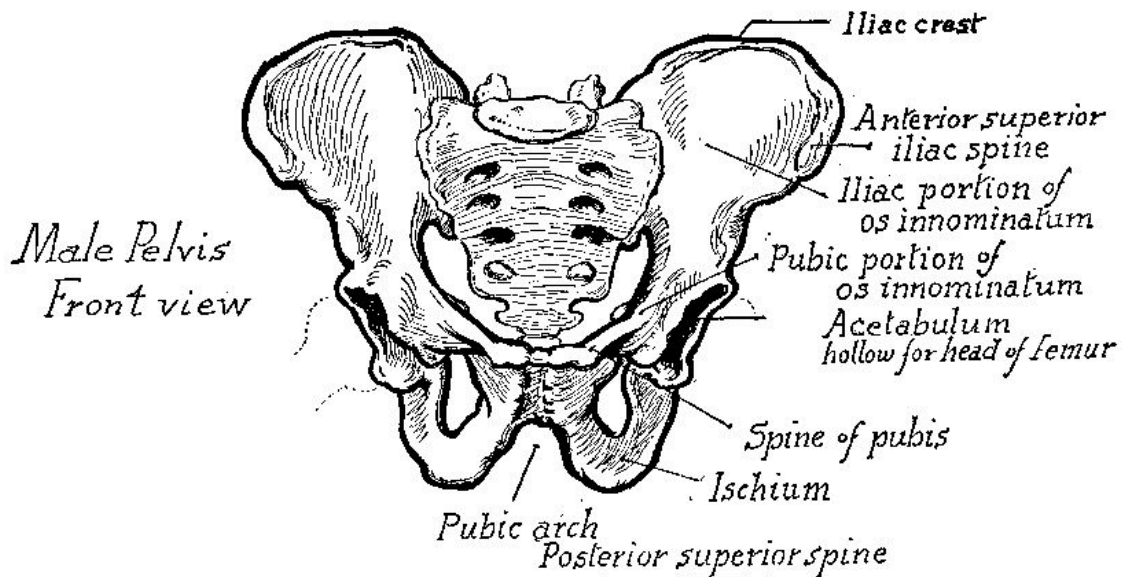






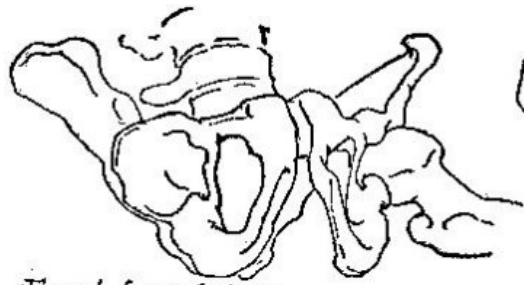




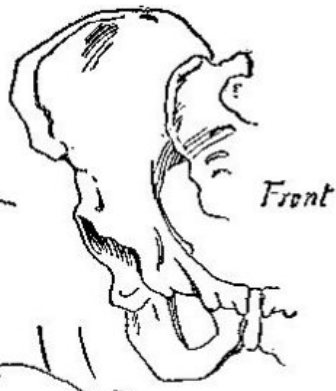


Showing female bone tilted forward

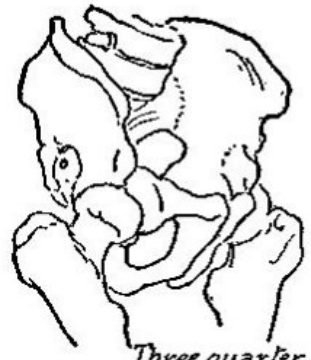Difference of height and breadth



*Front from below*



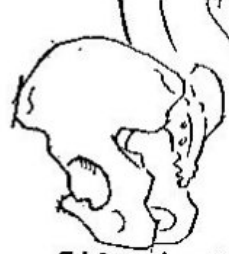*Front*



*Three quarter front*



*Front*



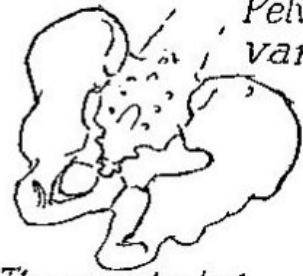*Side & back*



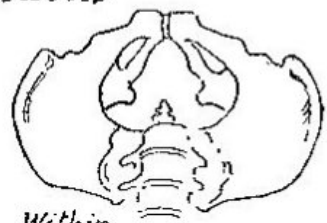*Side view*



*Three quarter view within*



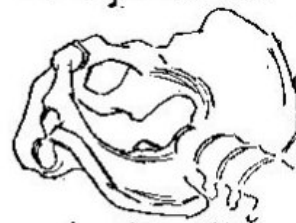*Three quarter back*



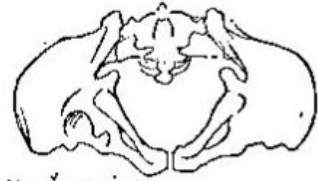*Within*



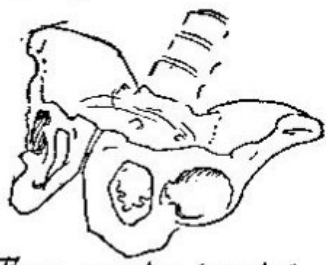
*Lying down*



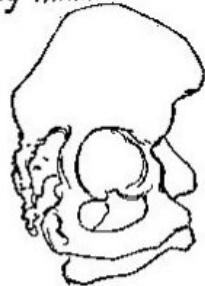*Looking within*



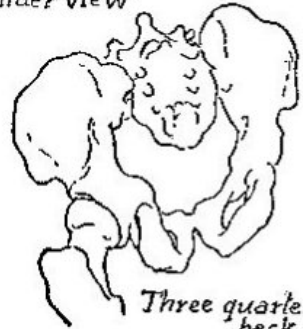*Under view*



*Three quarter from below*

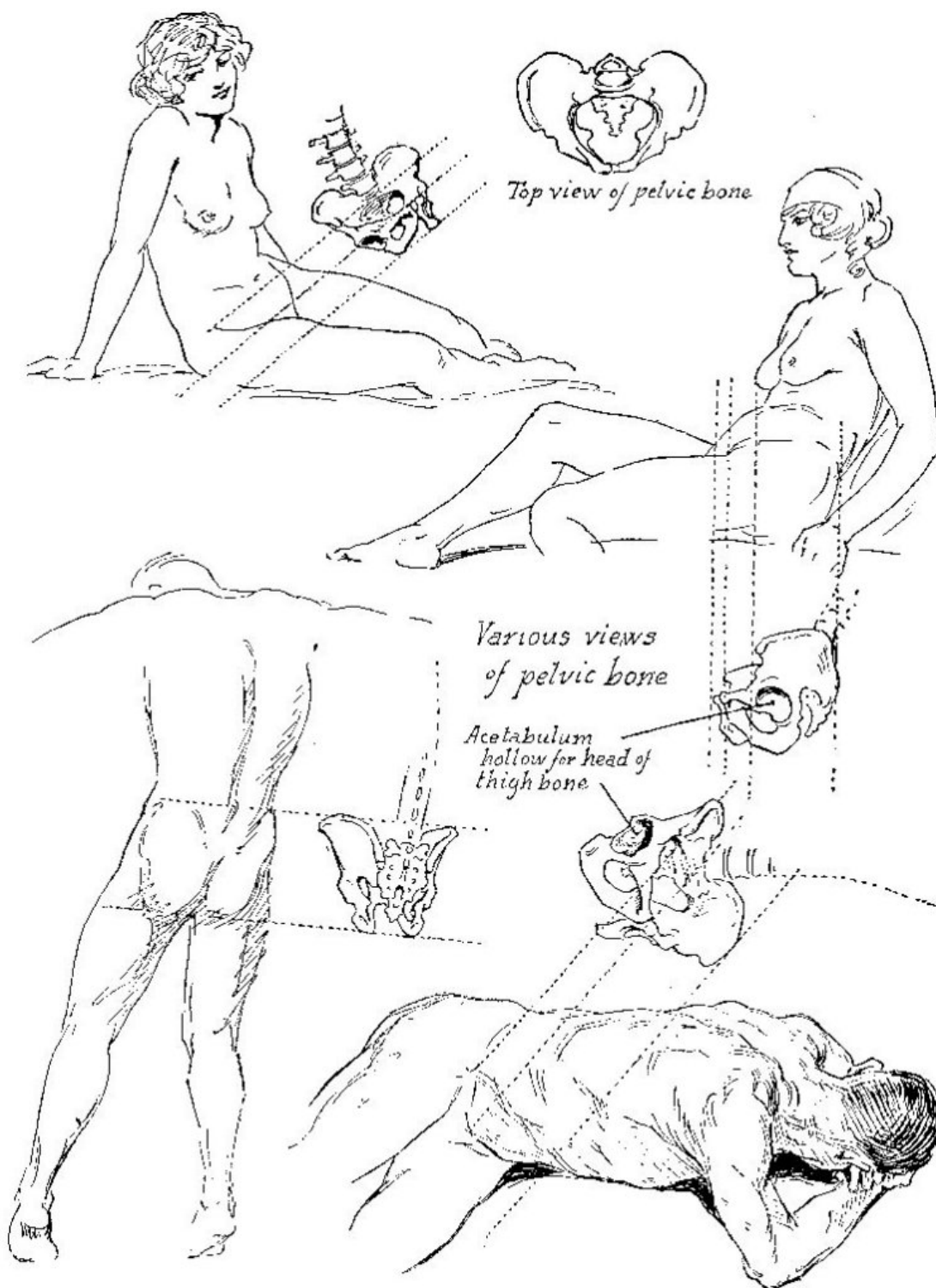


*Side*

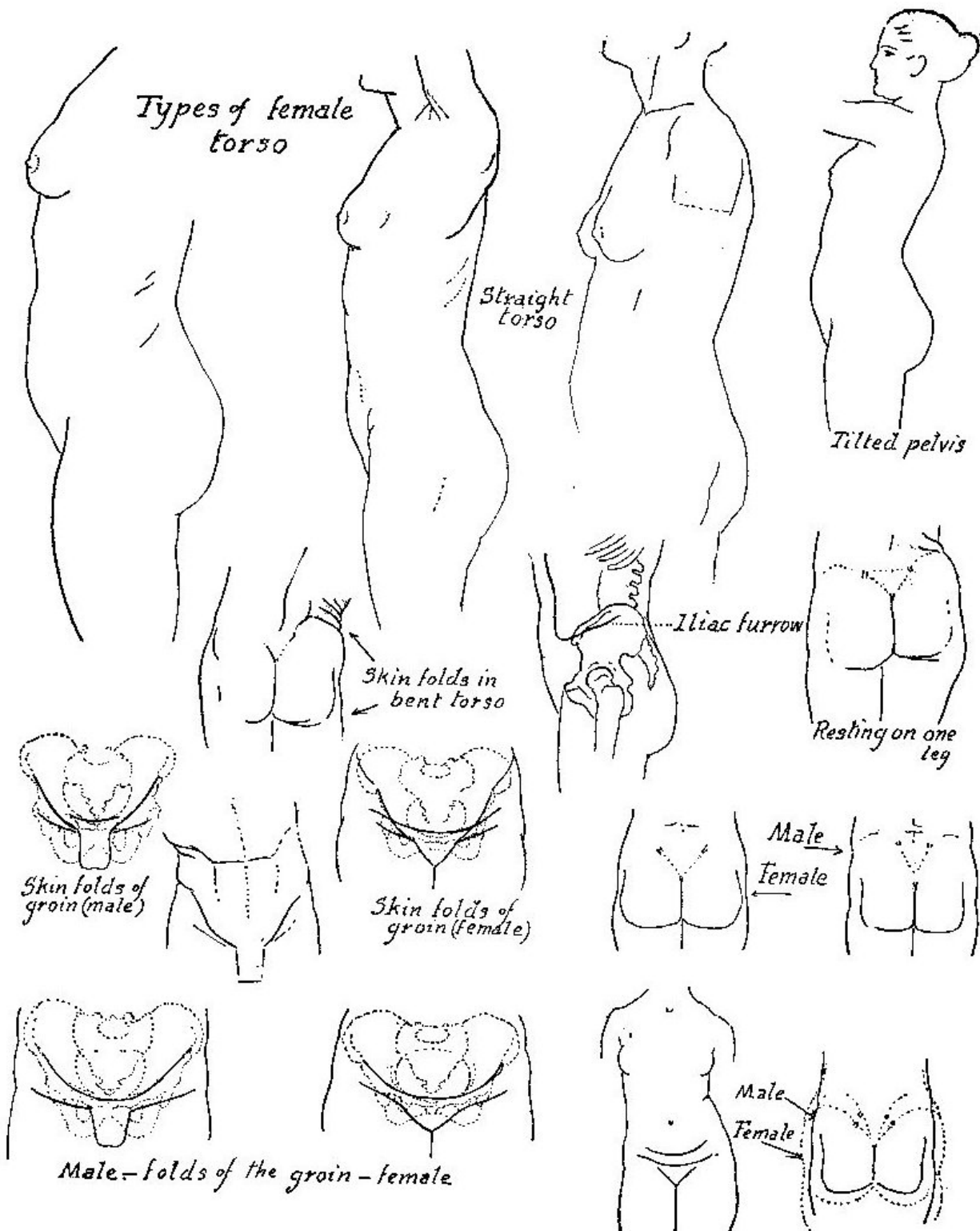


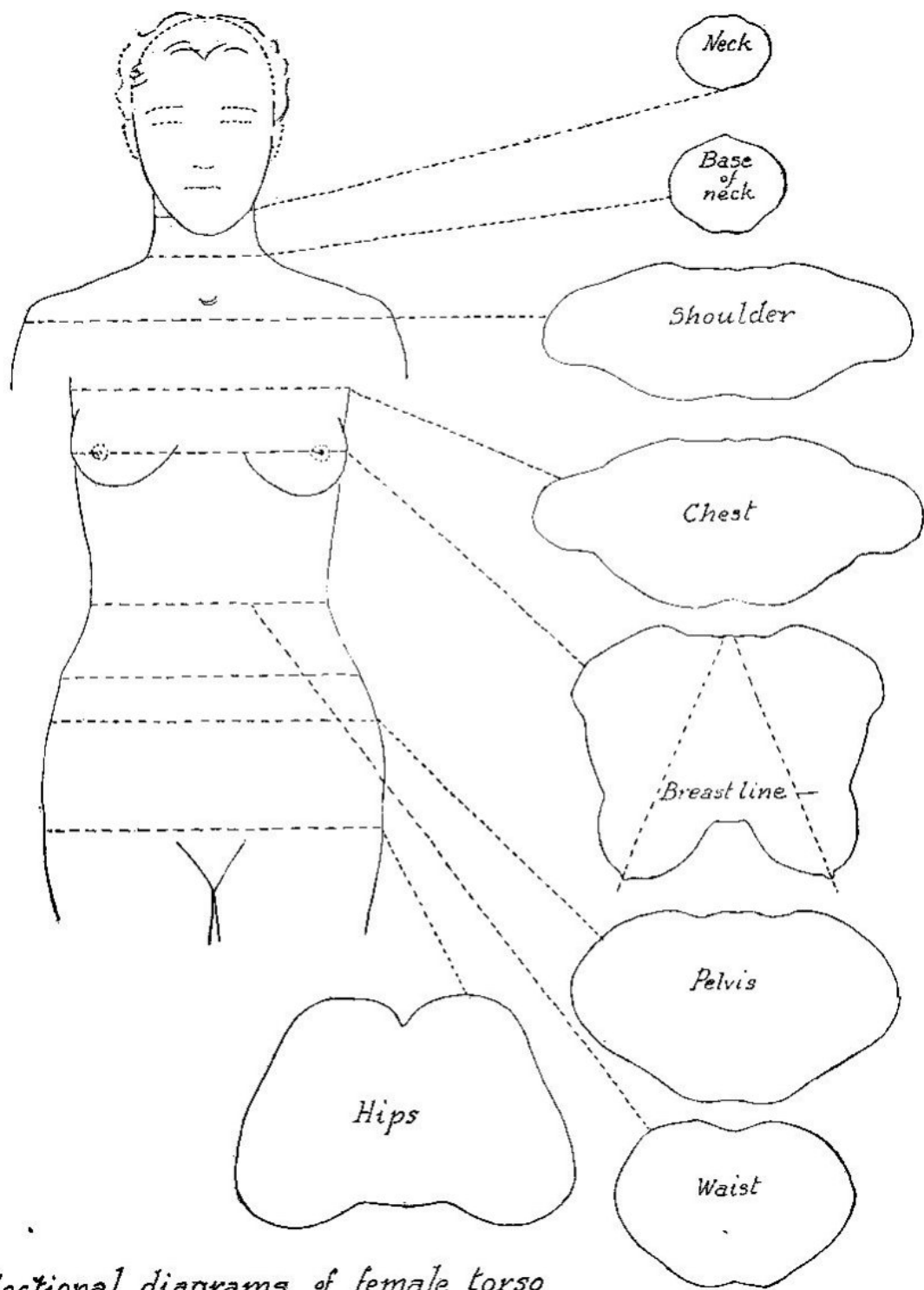
*Three quarter back*

*Pelvic bone in various positions*

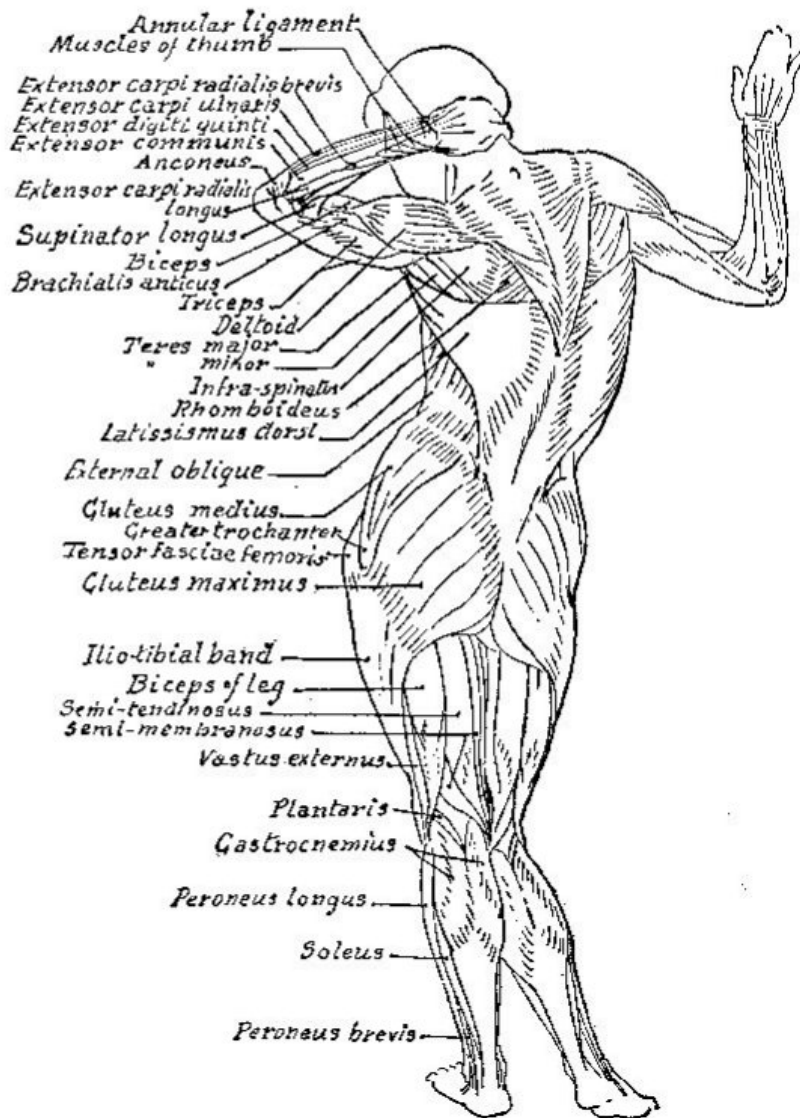
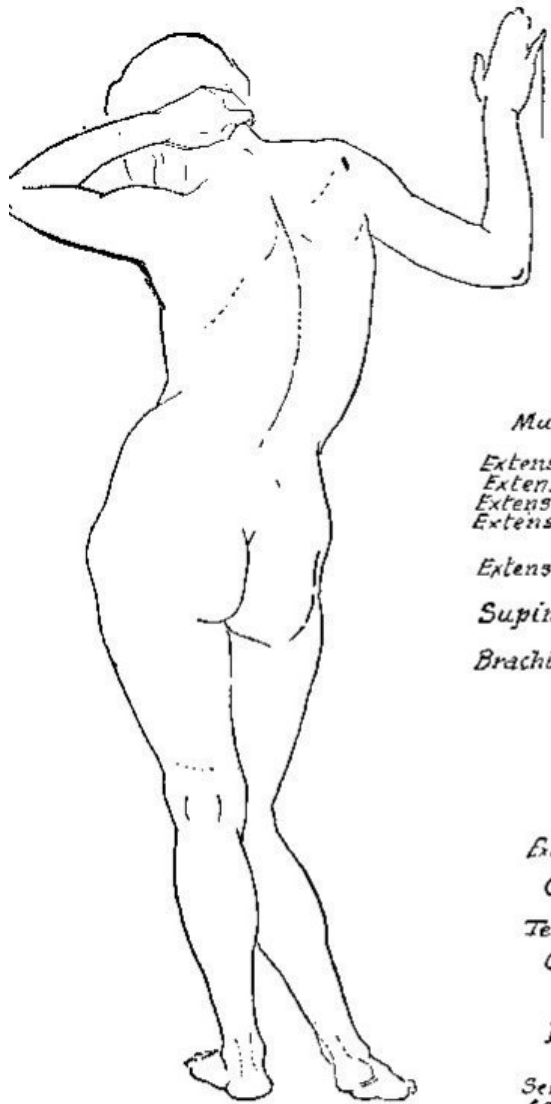


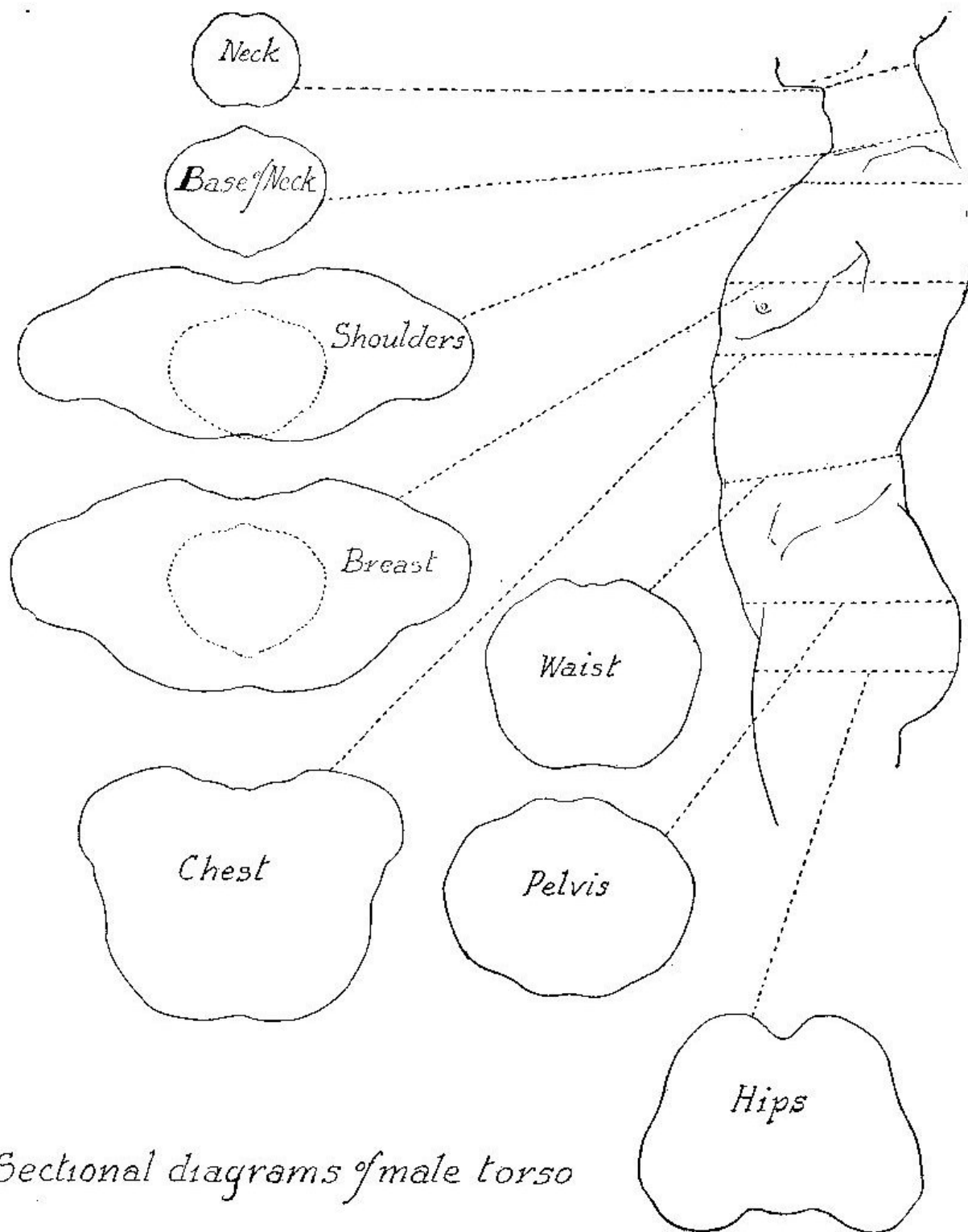
Victor T. Ford





*Sectional diagrams of female torso*



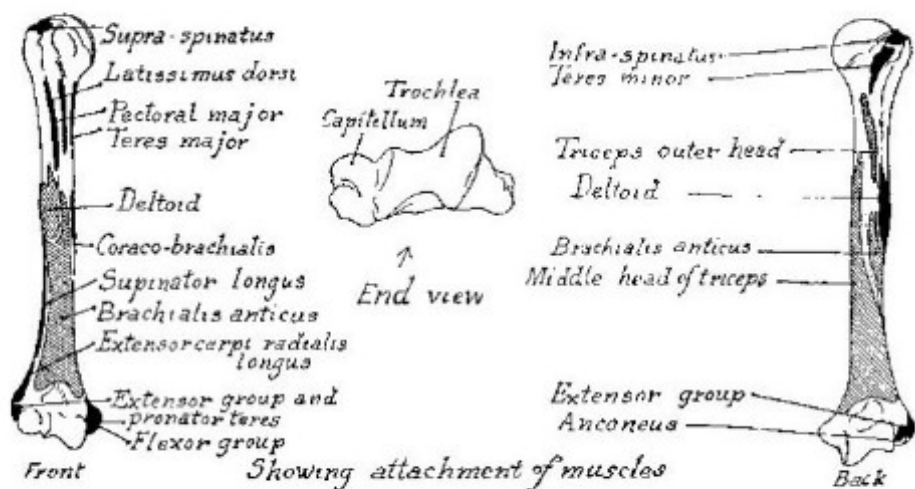
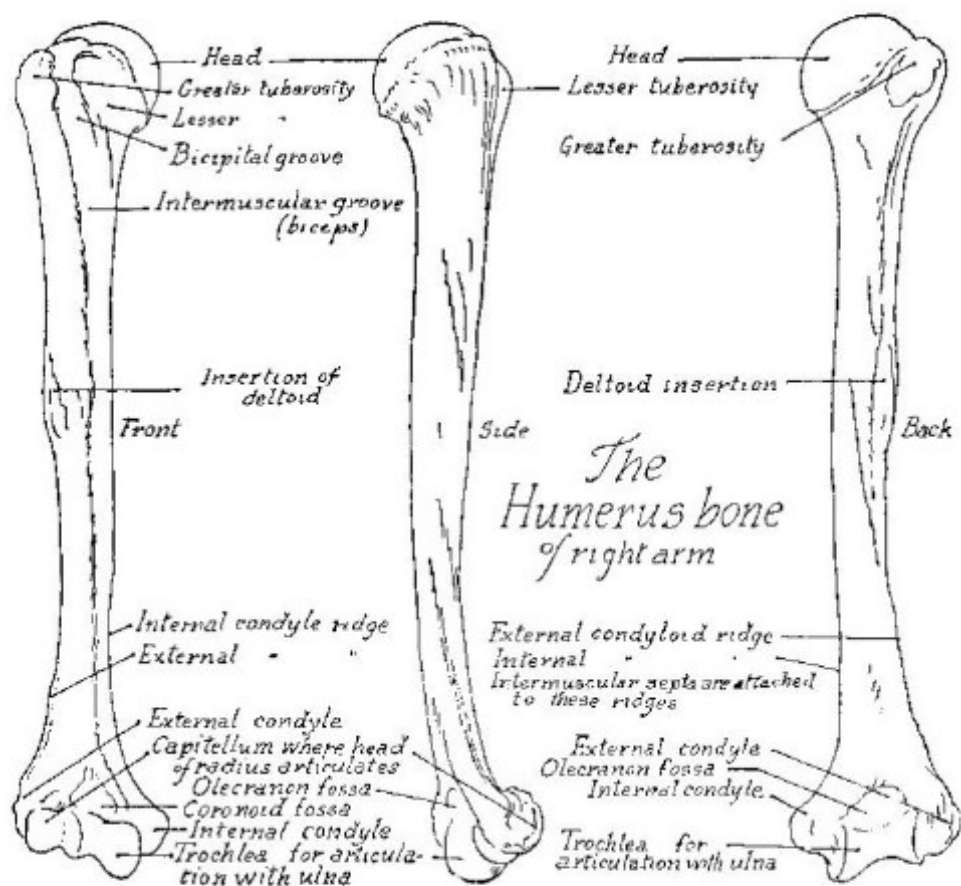


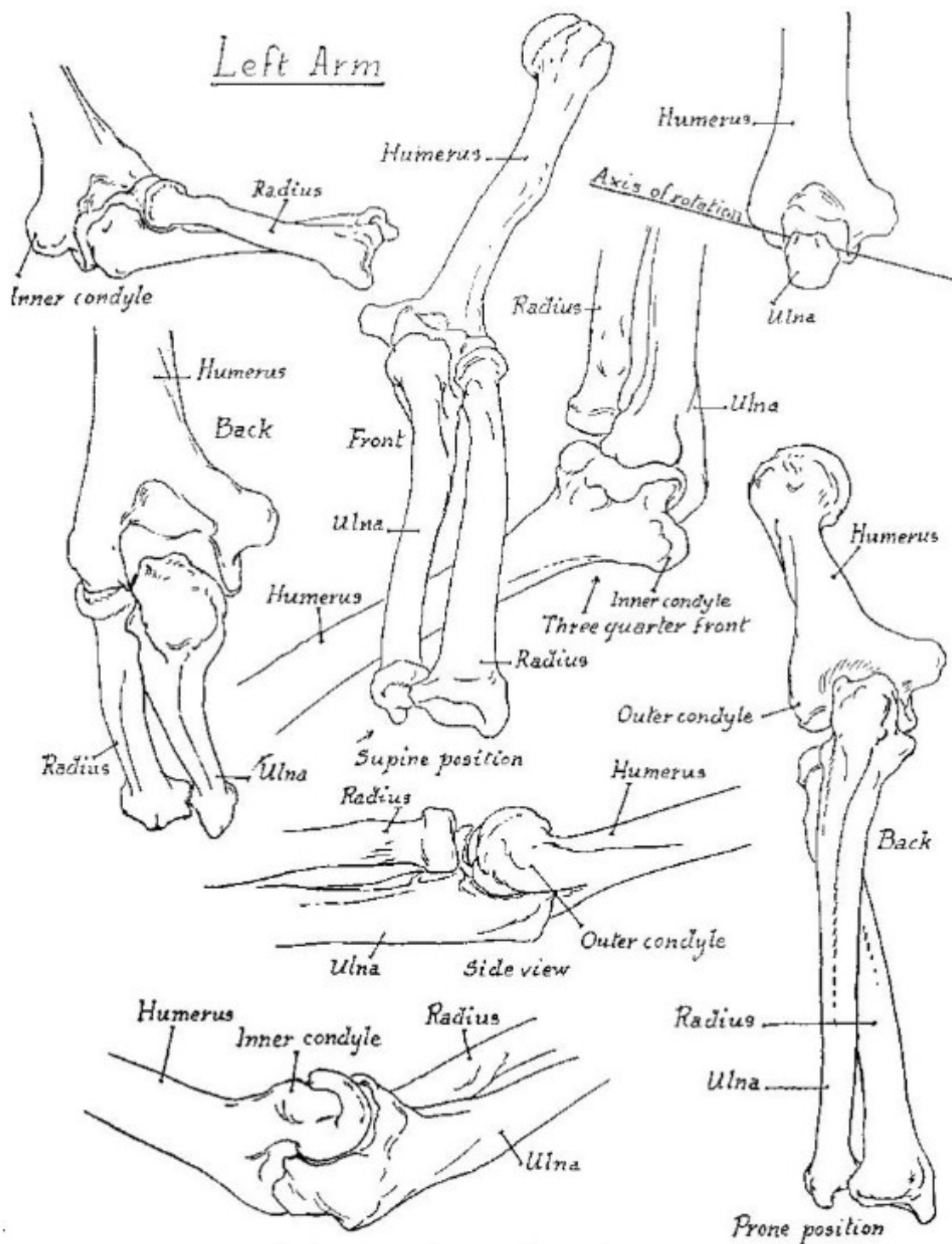


Part V

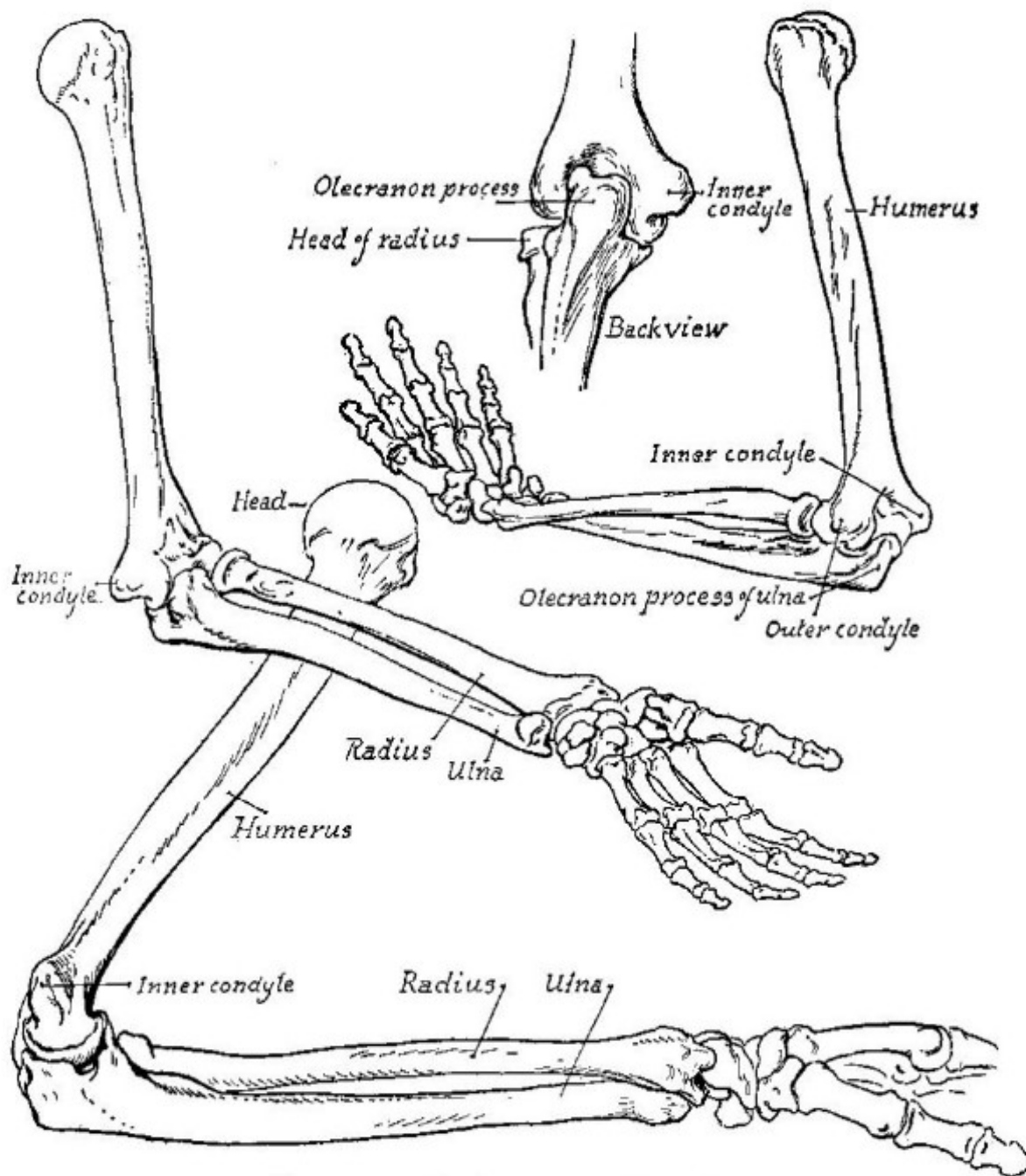
## *The Arm*



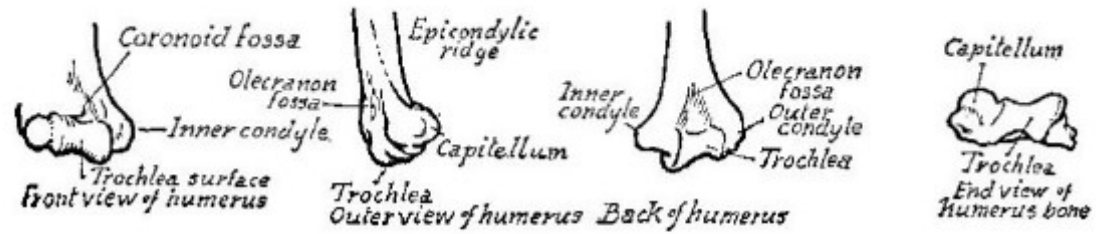
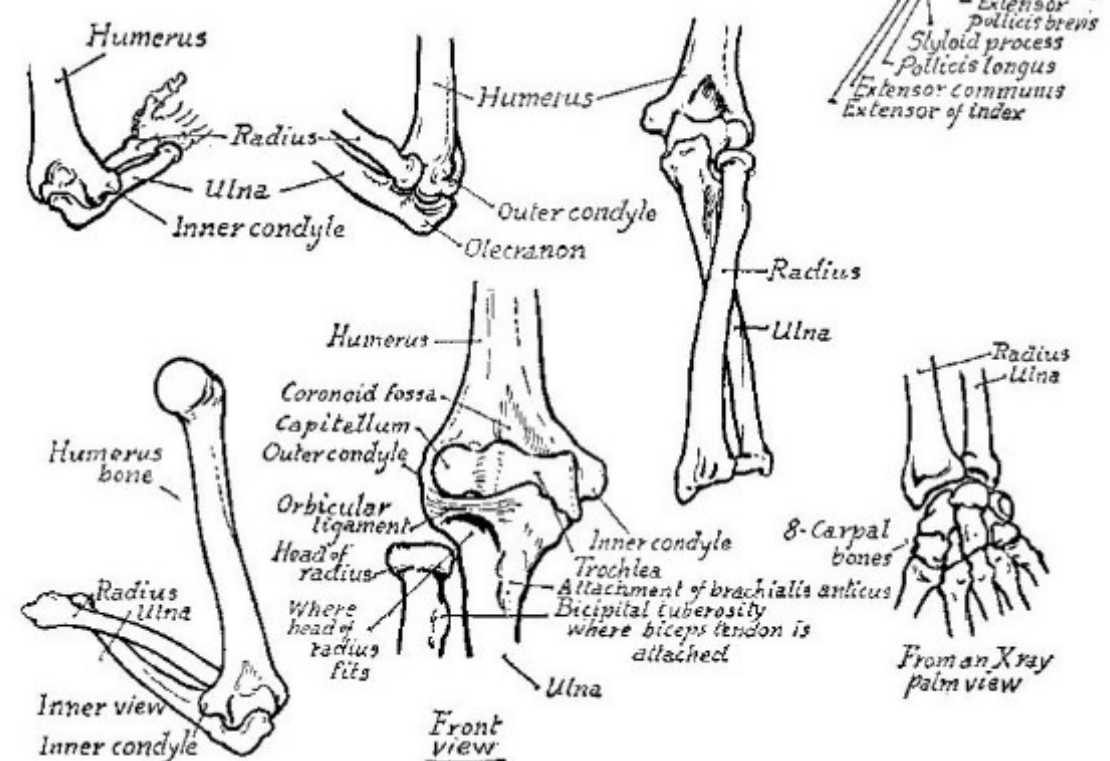
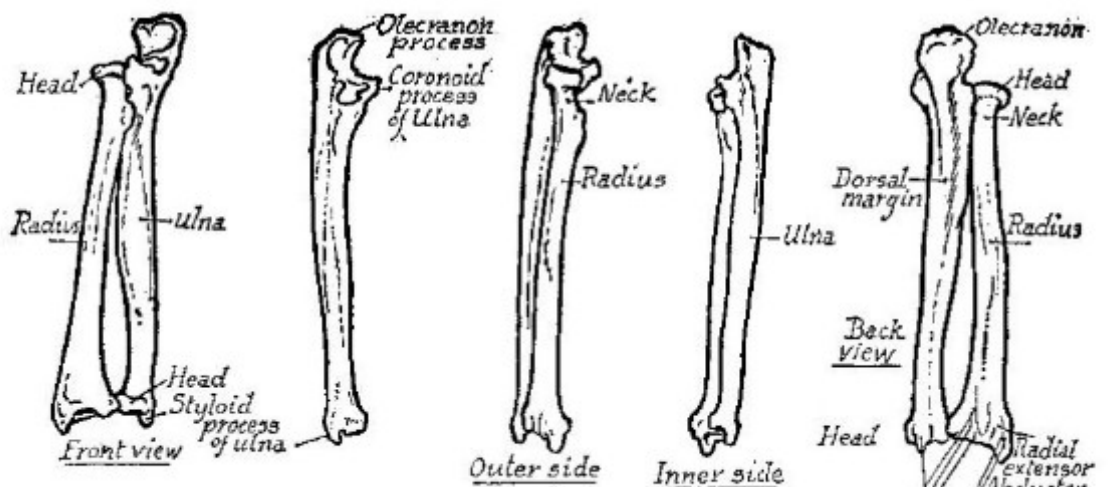


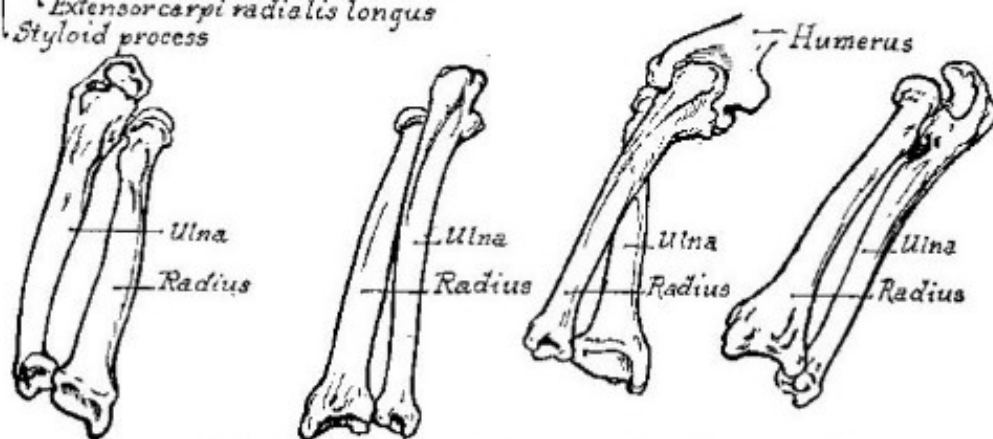
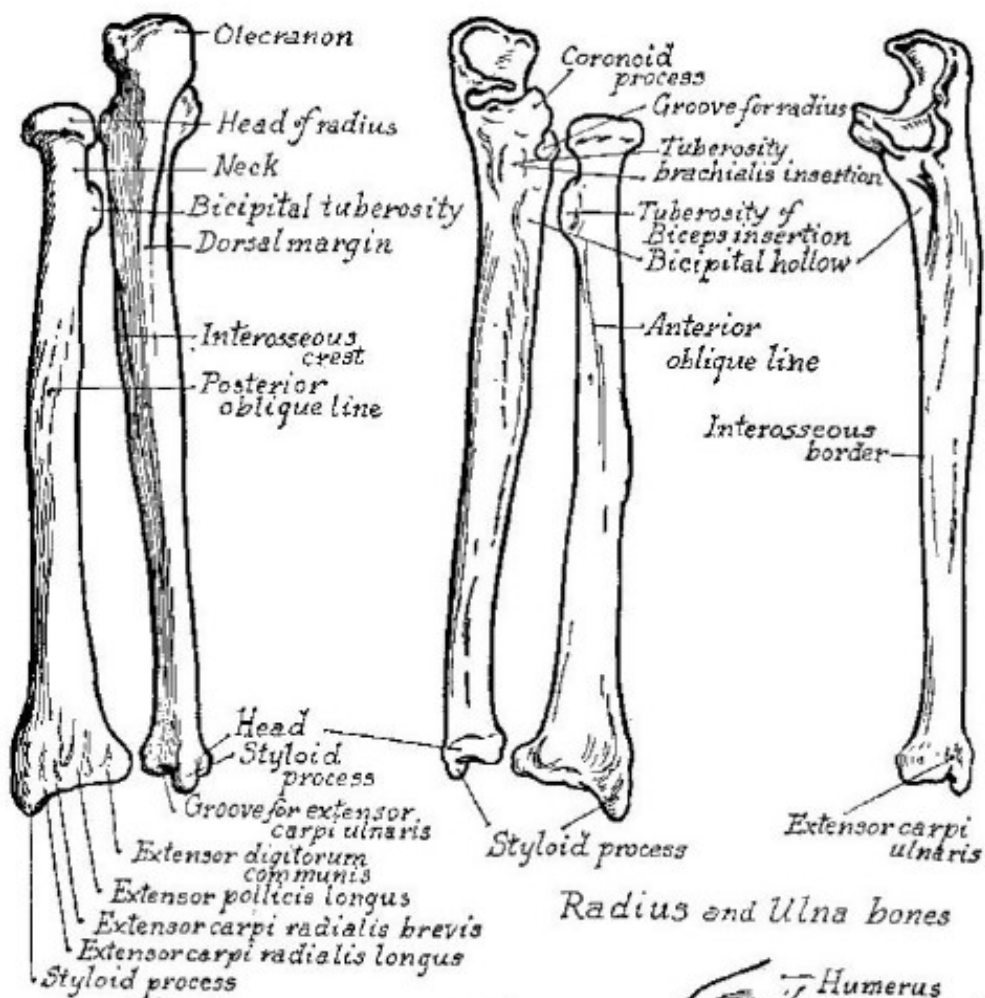


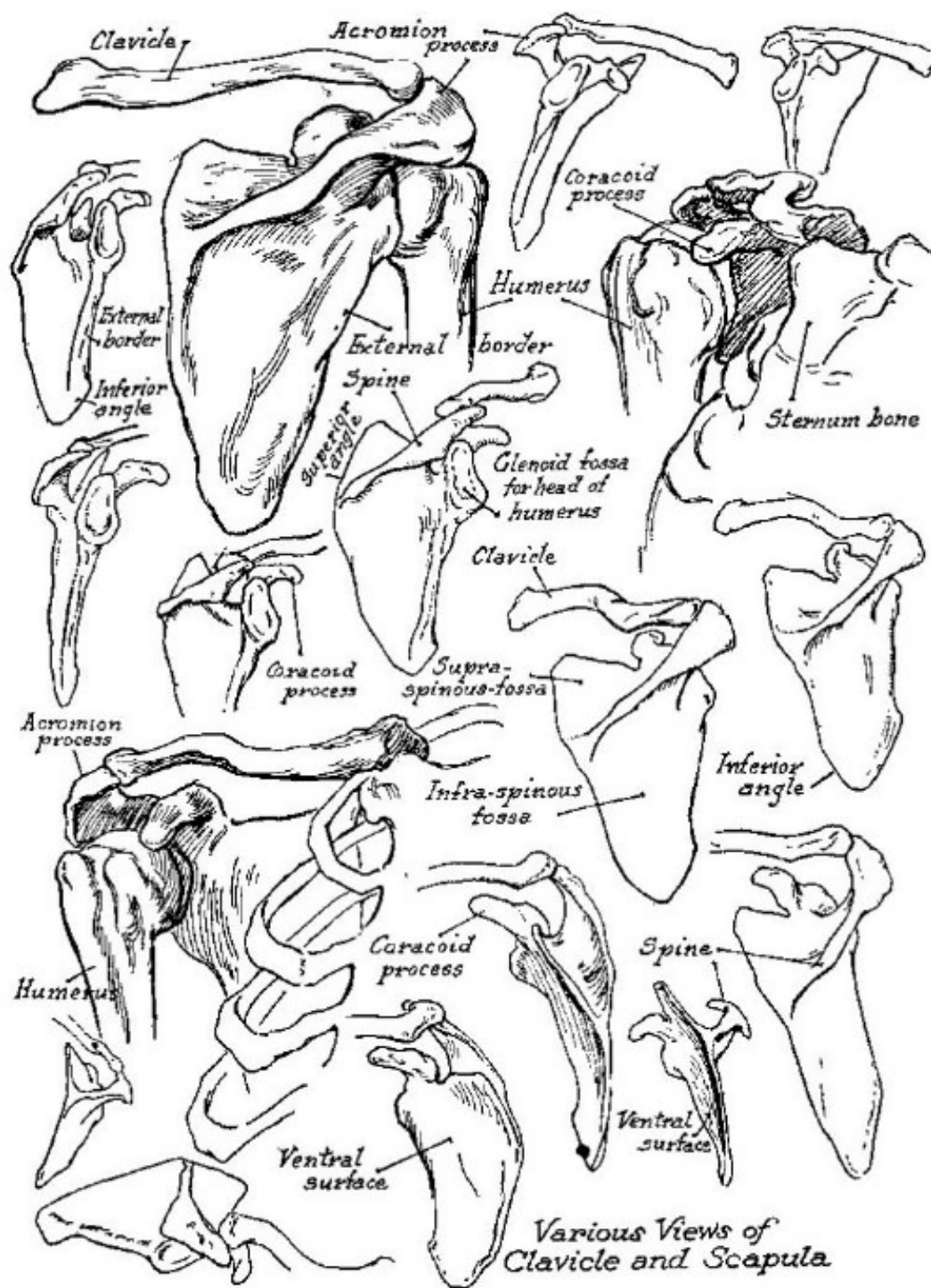
Various positions of arm bones

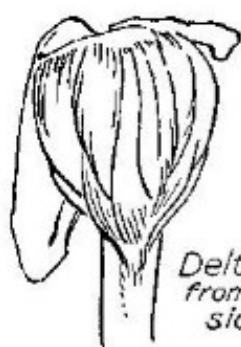


*Bones of Arm and Hand*

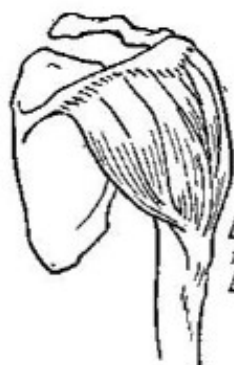



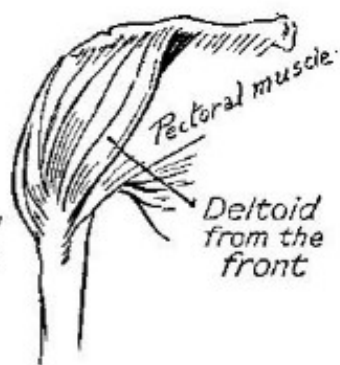




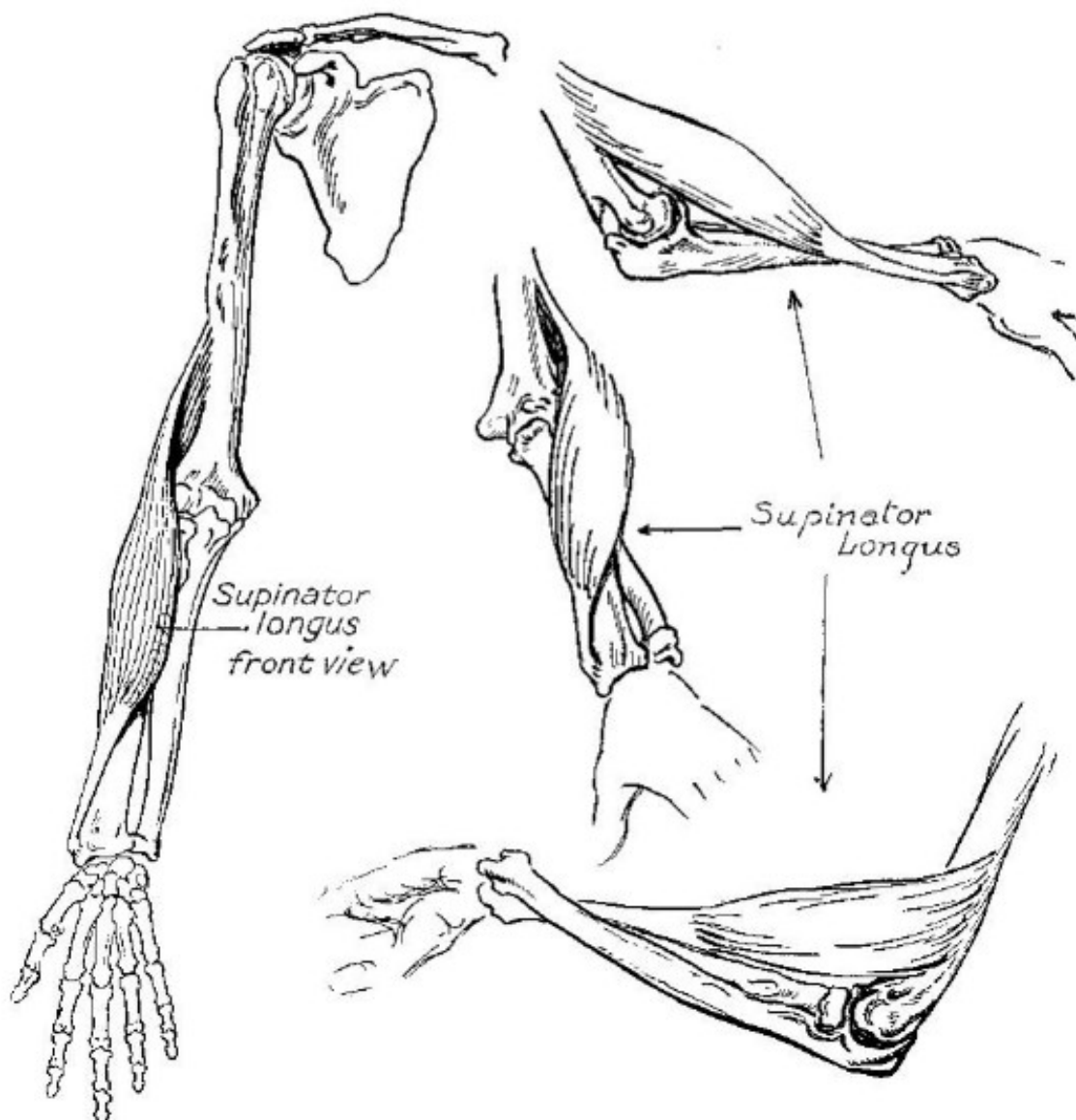
*Deltoid  
from the  
side*

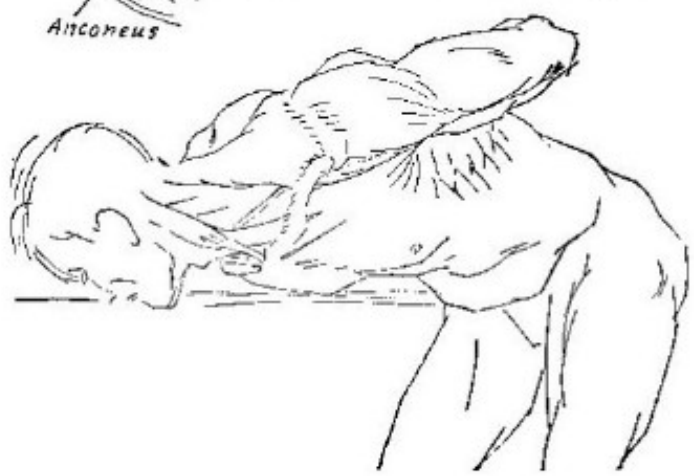
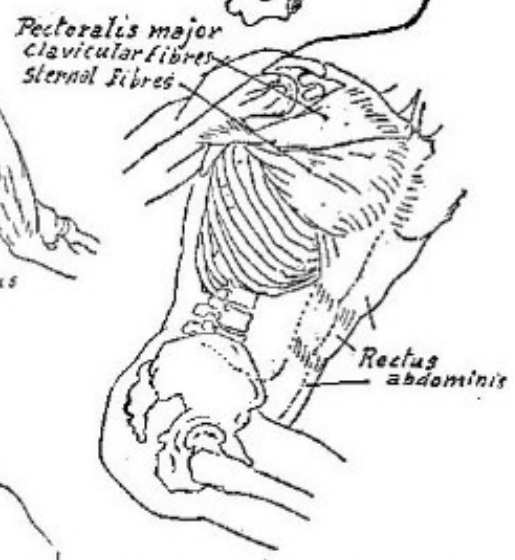
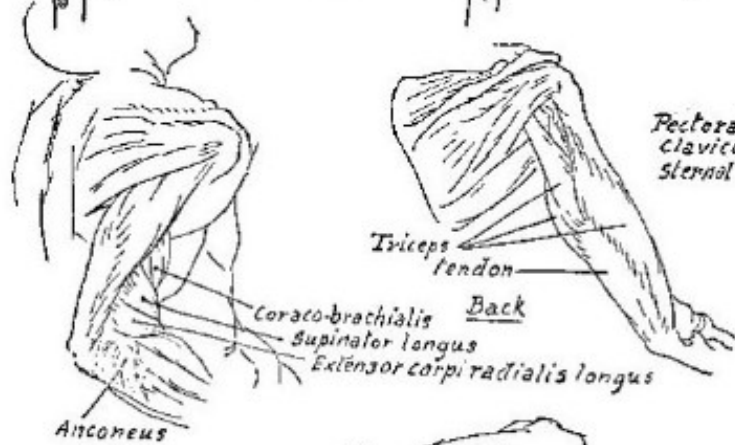
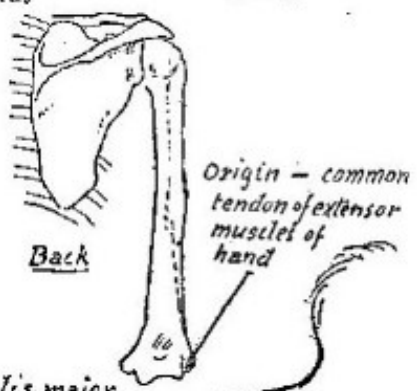
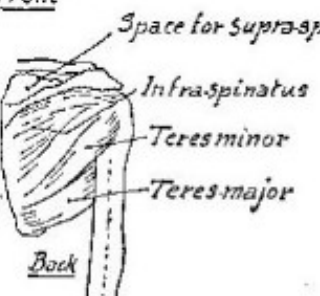
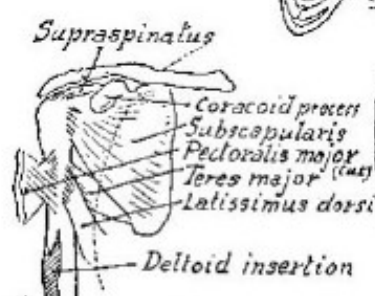
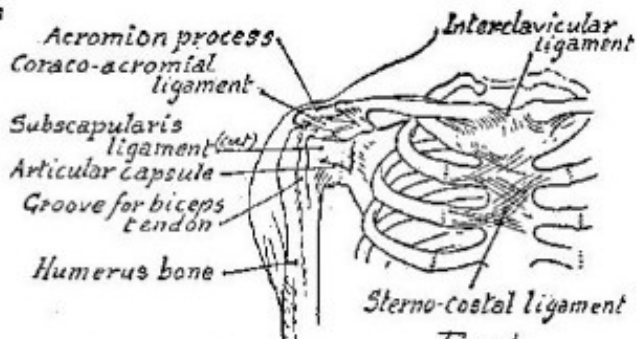
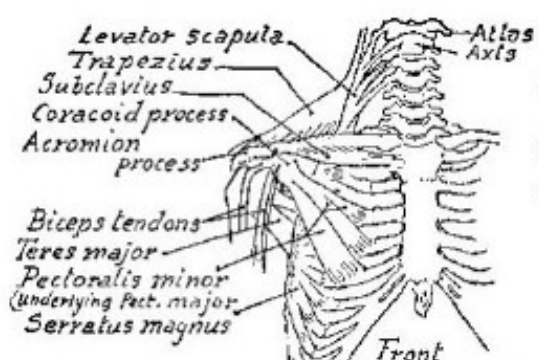


*Deltoid  
from the  
back*



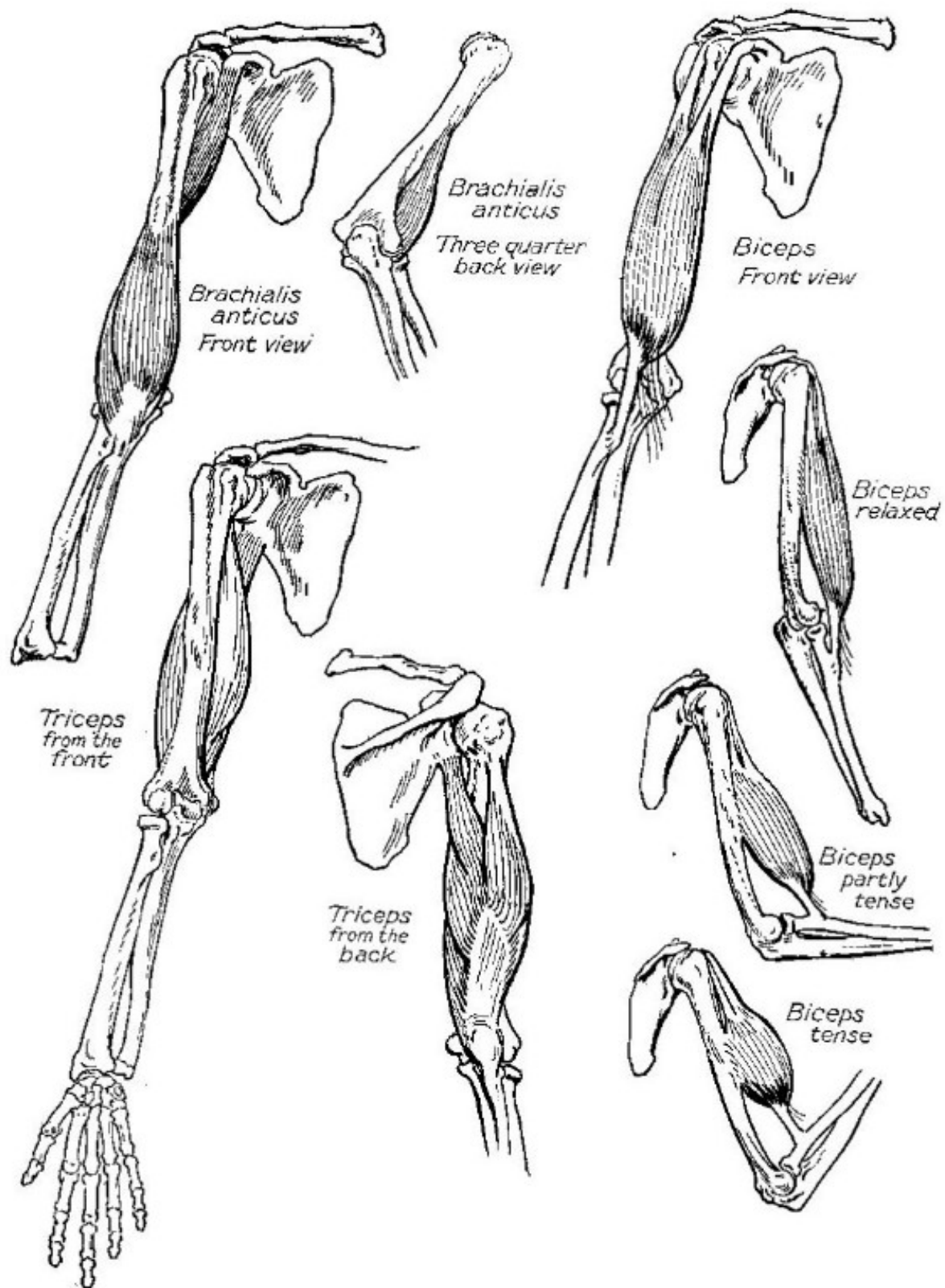
*Pectoral muscle*  
*Deltoid  
from the  
front*

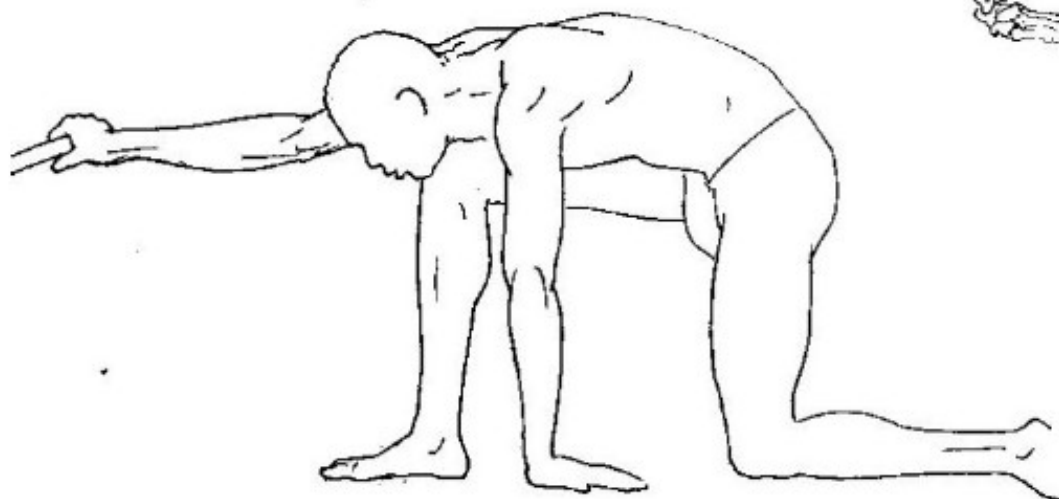
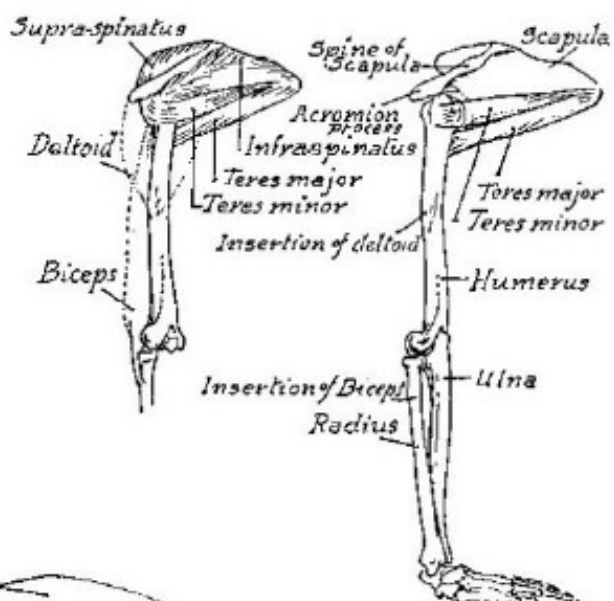
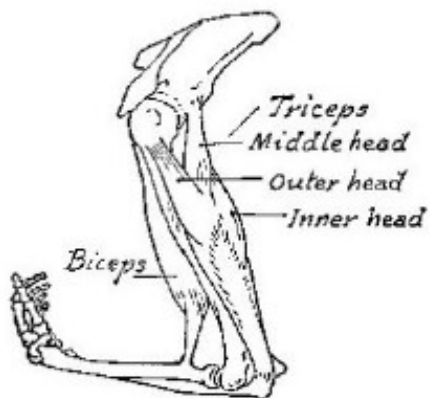
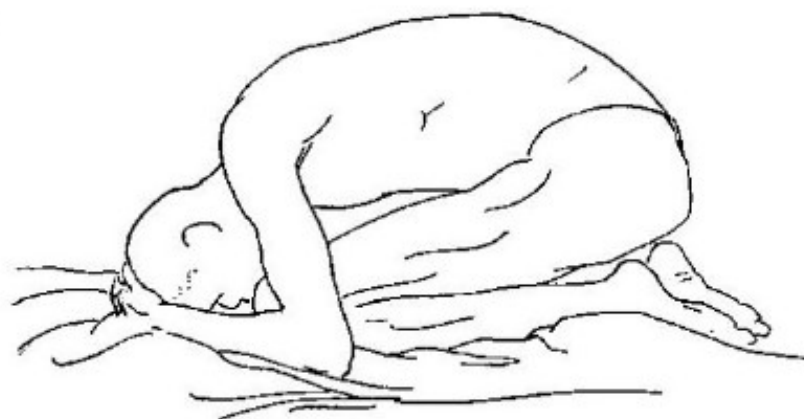
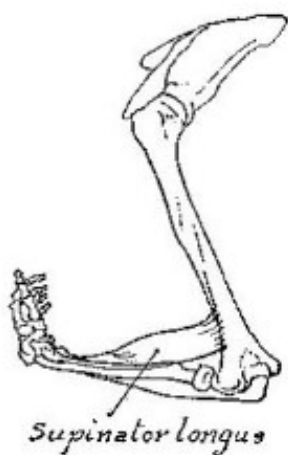

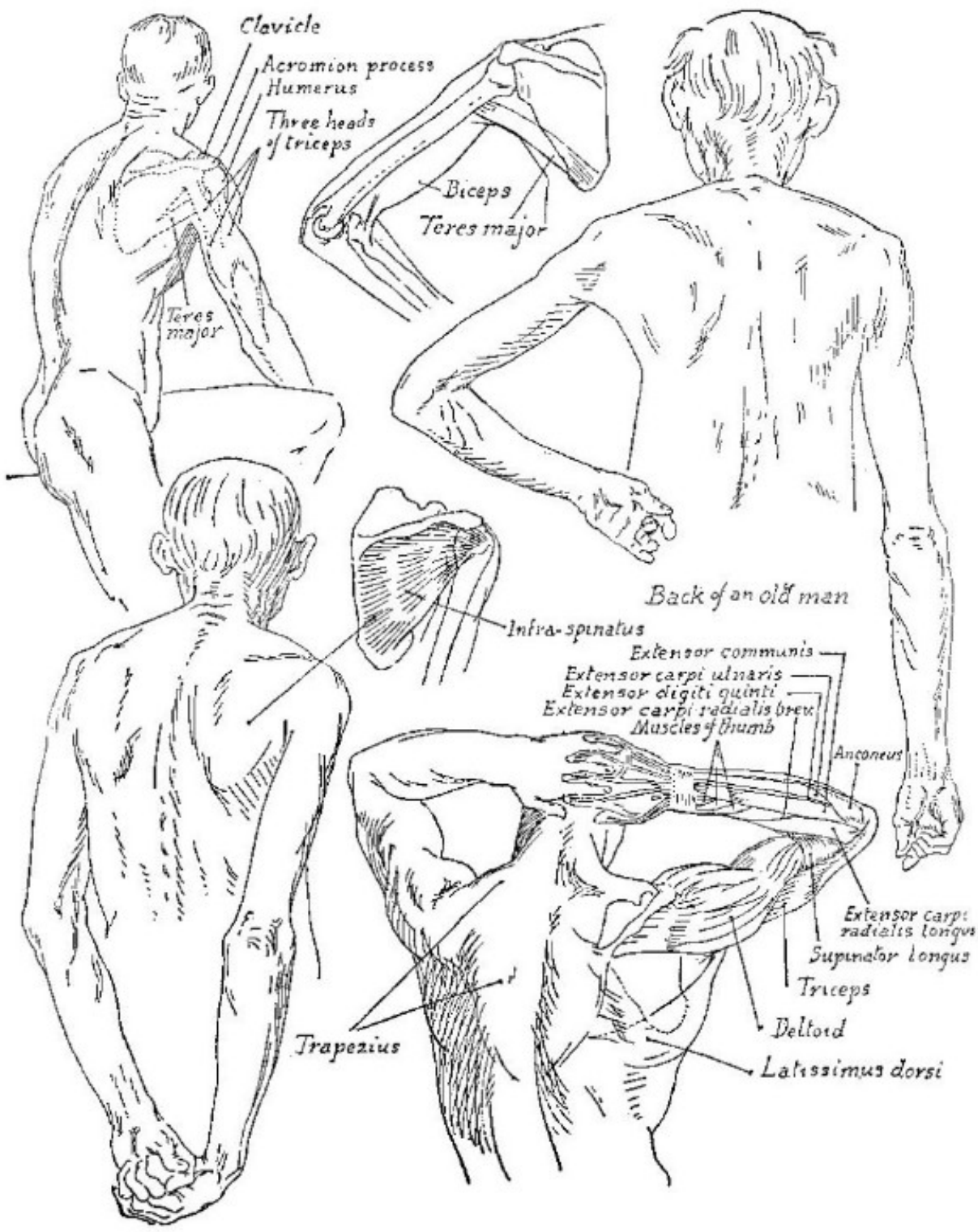


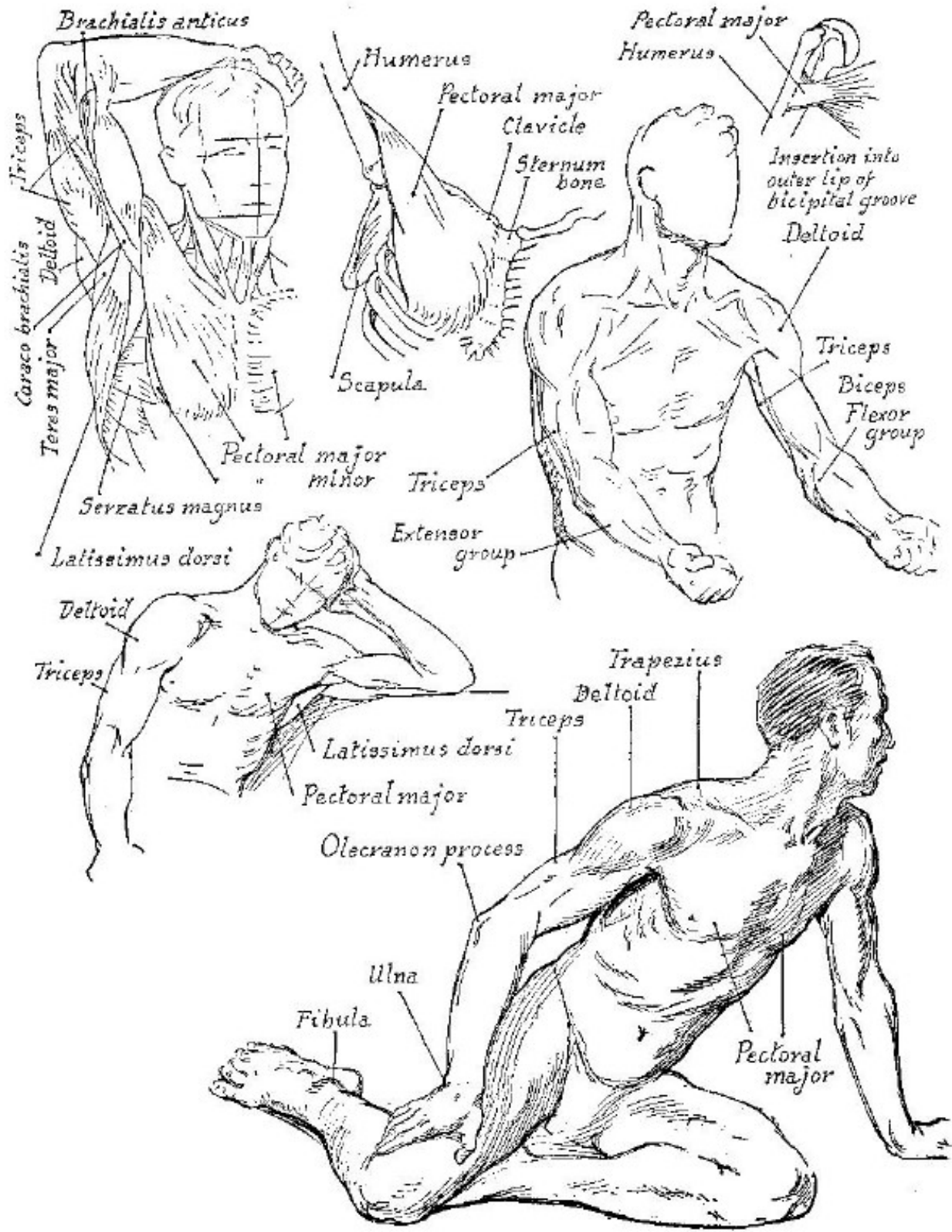
Studies of shoulder girdle, grouped for comparison

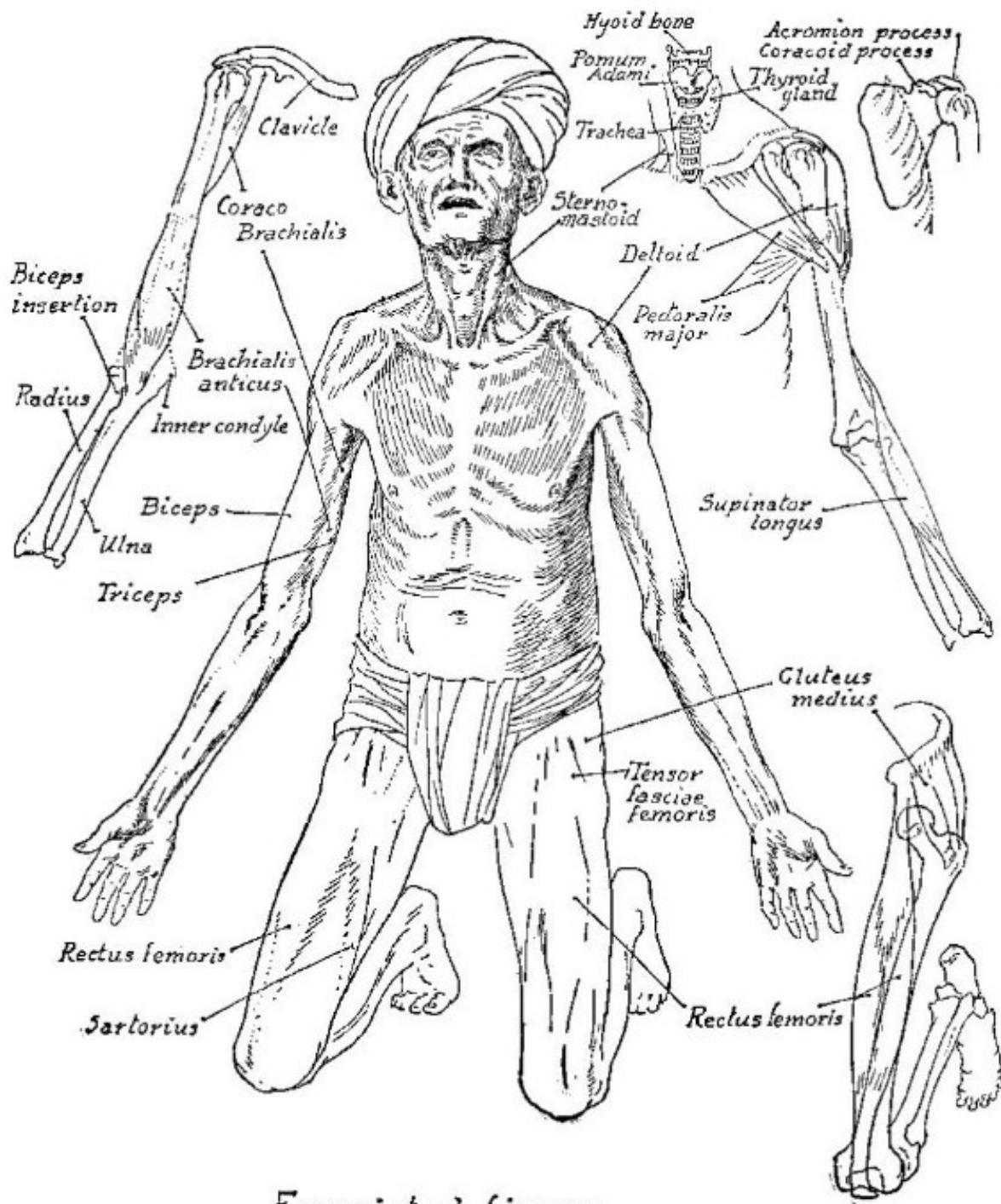




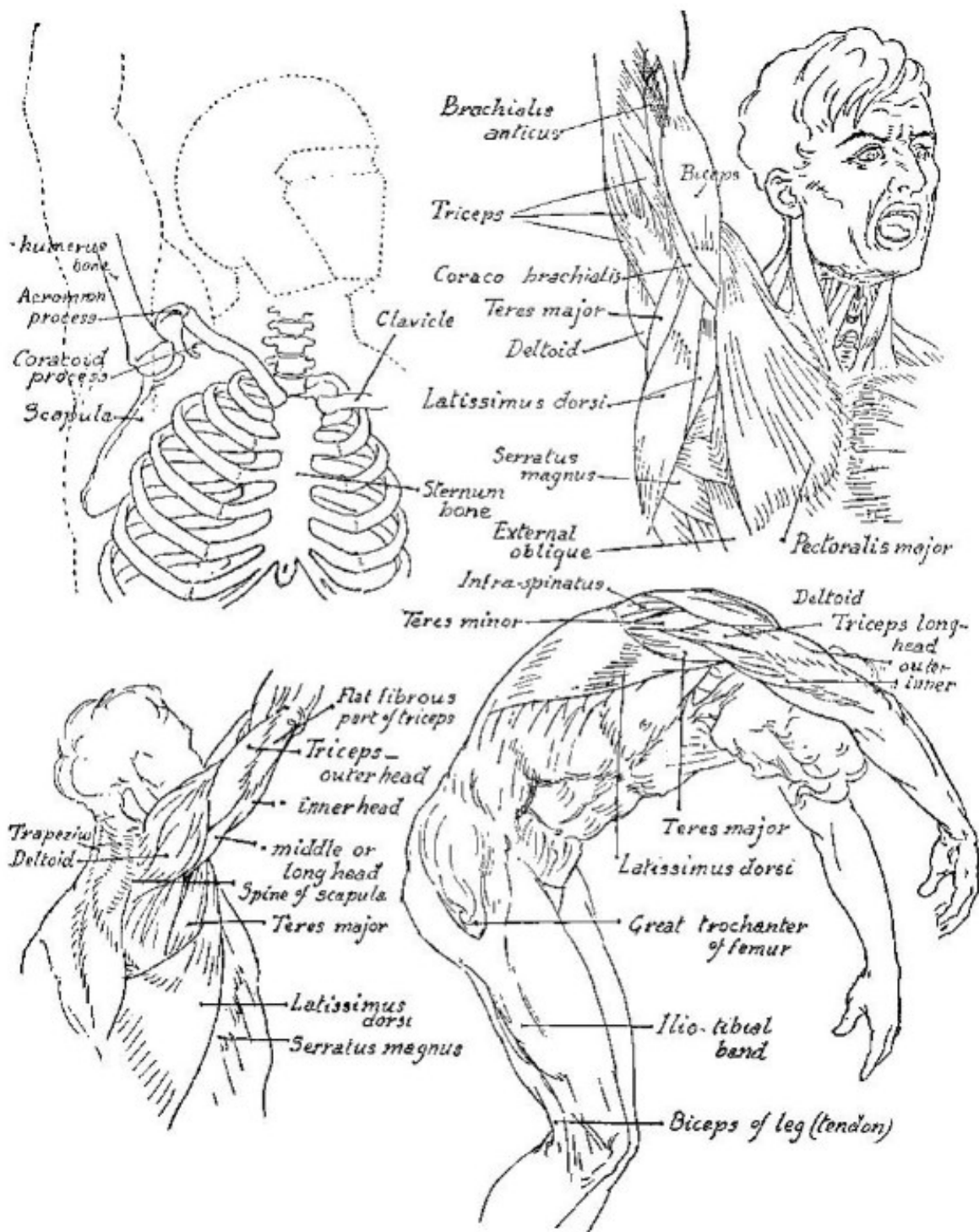


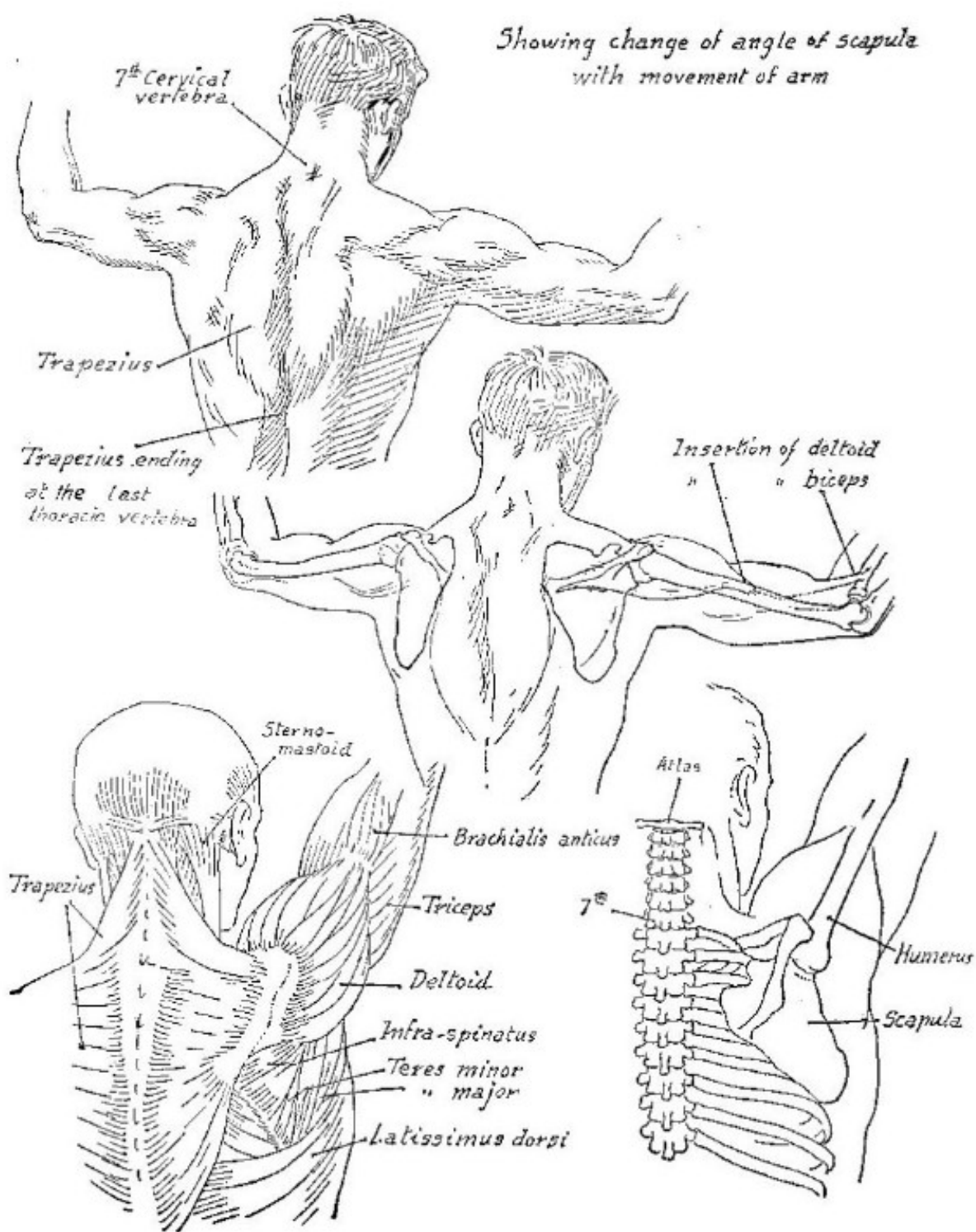




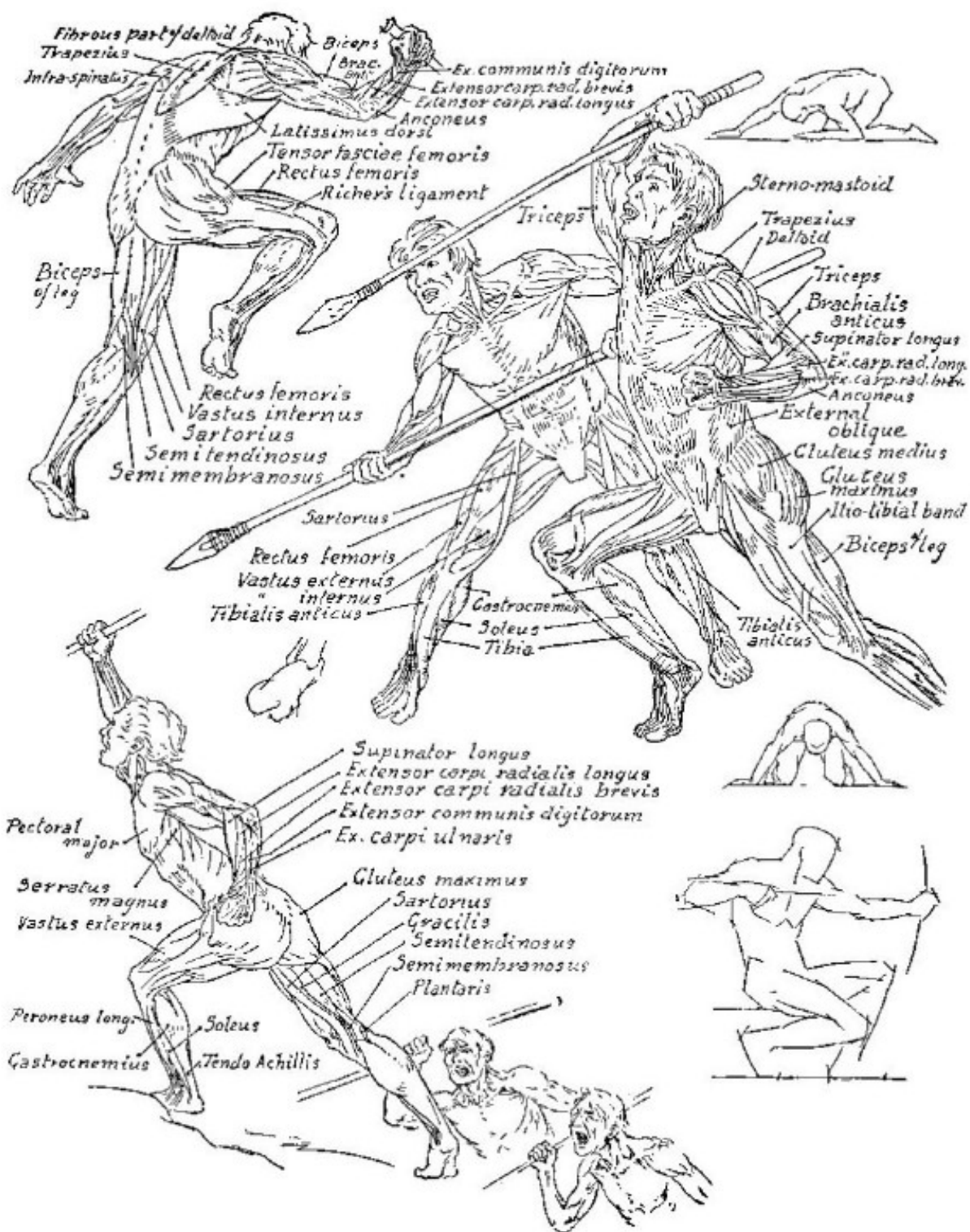


*Emaciated figure*

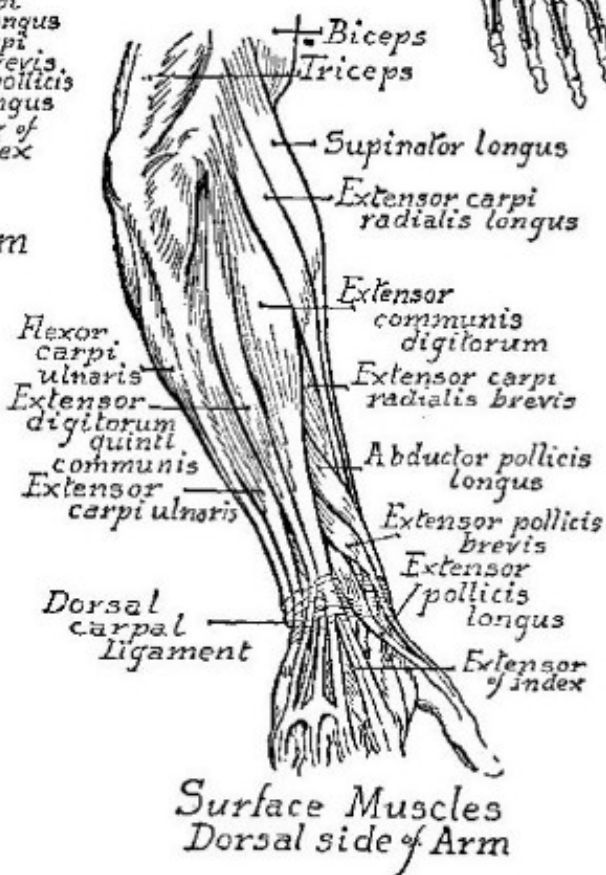
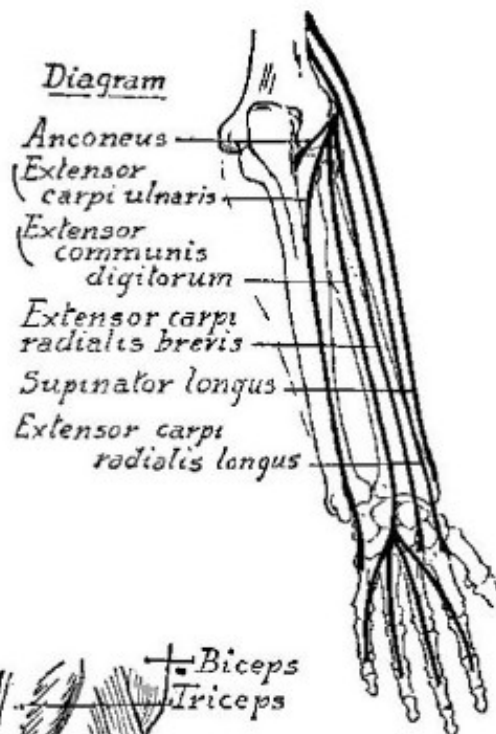
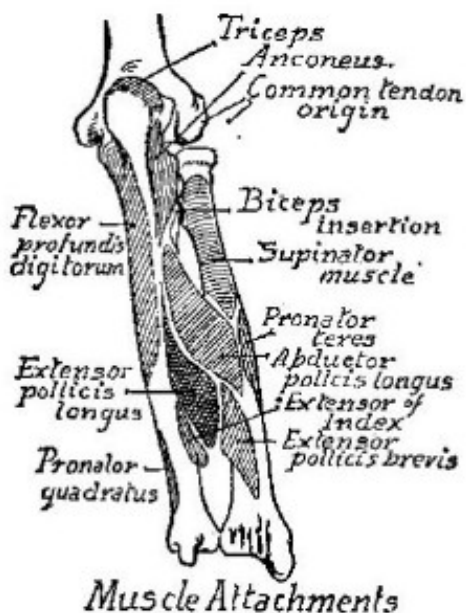
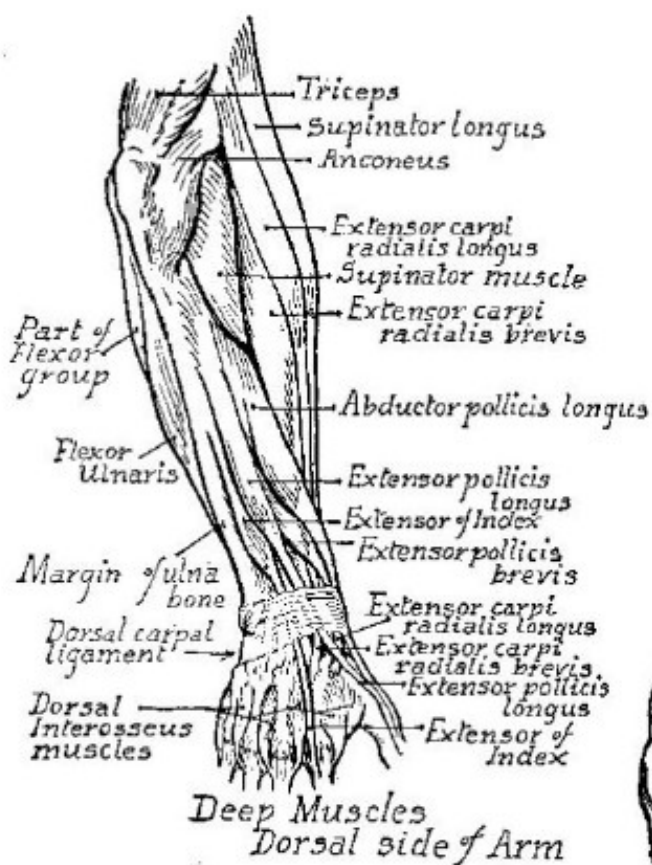


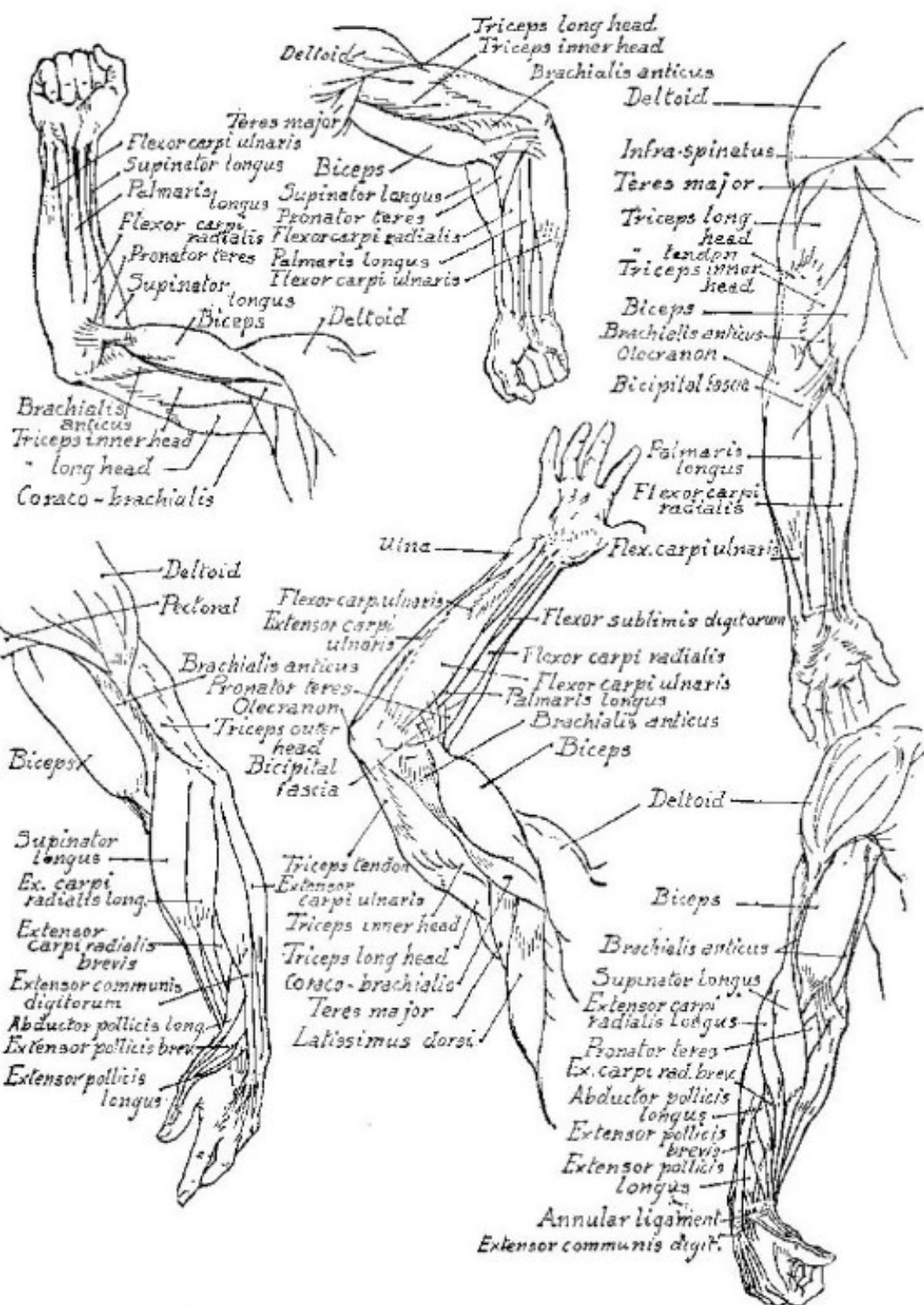


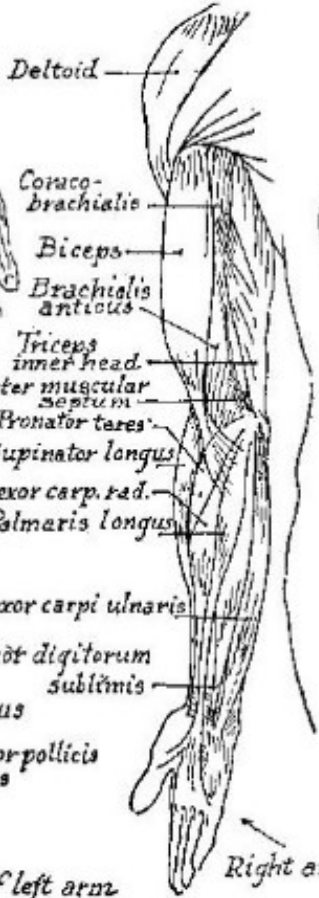
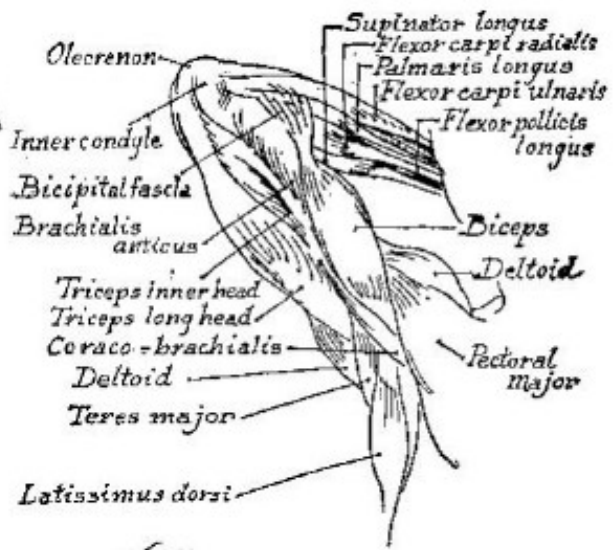
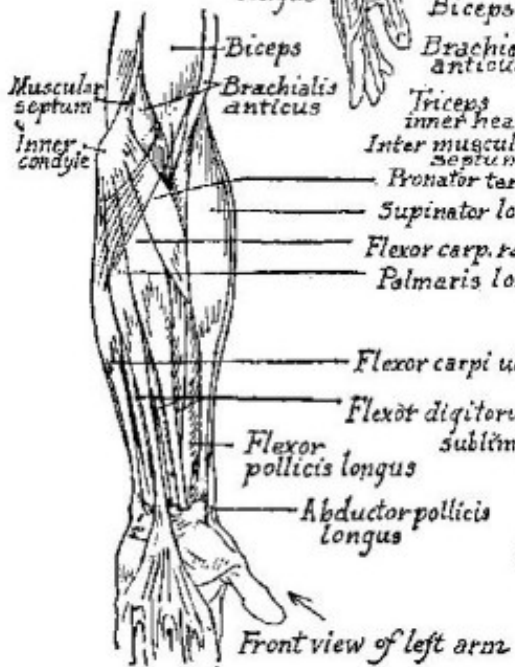
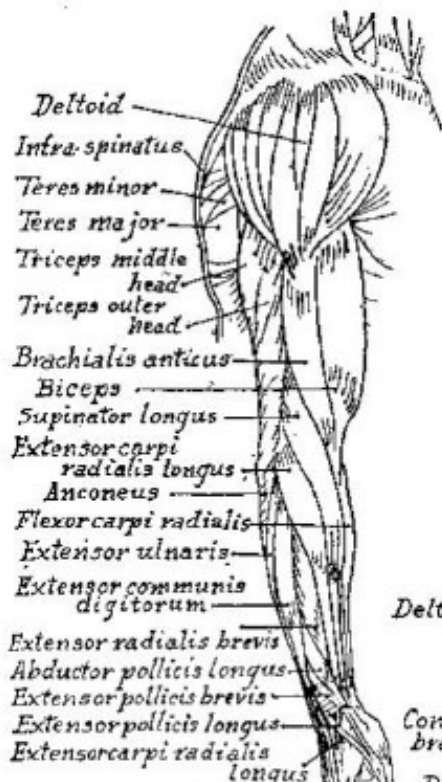





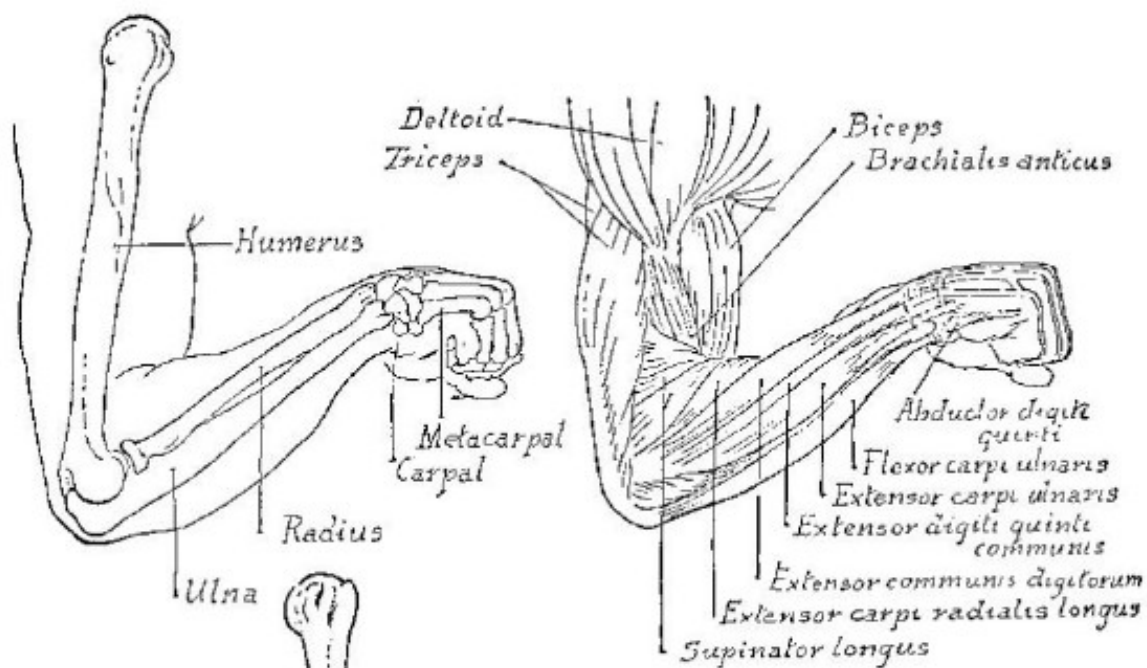




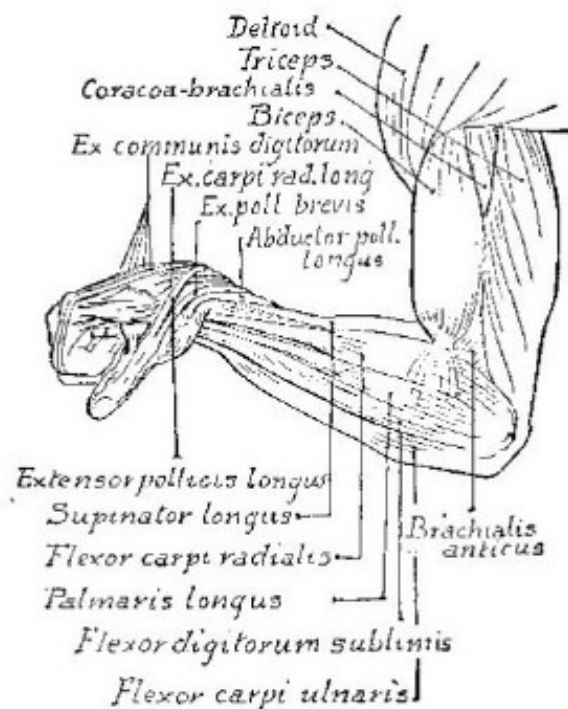

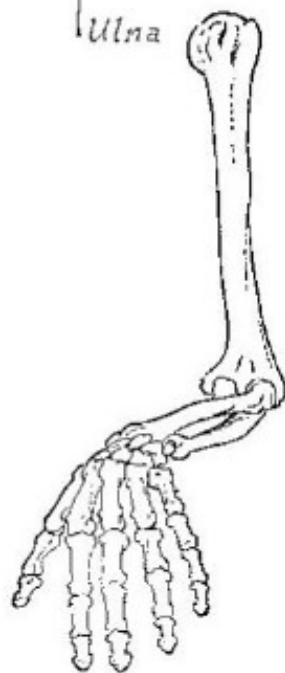
Front view of left arm

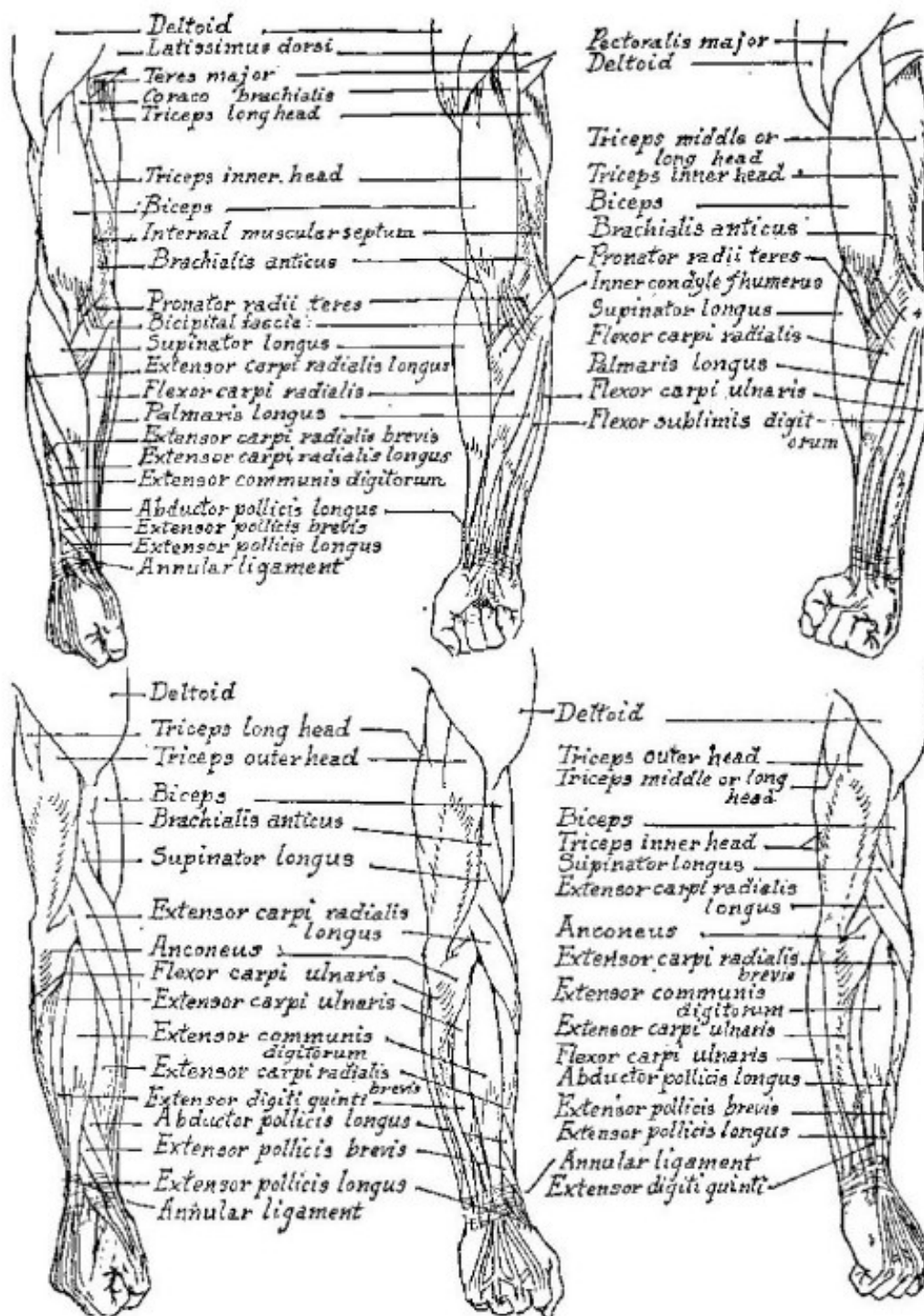
Right arm turned out

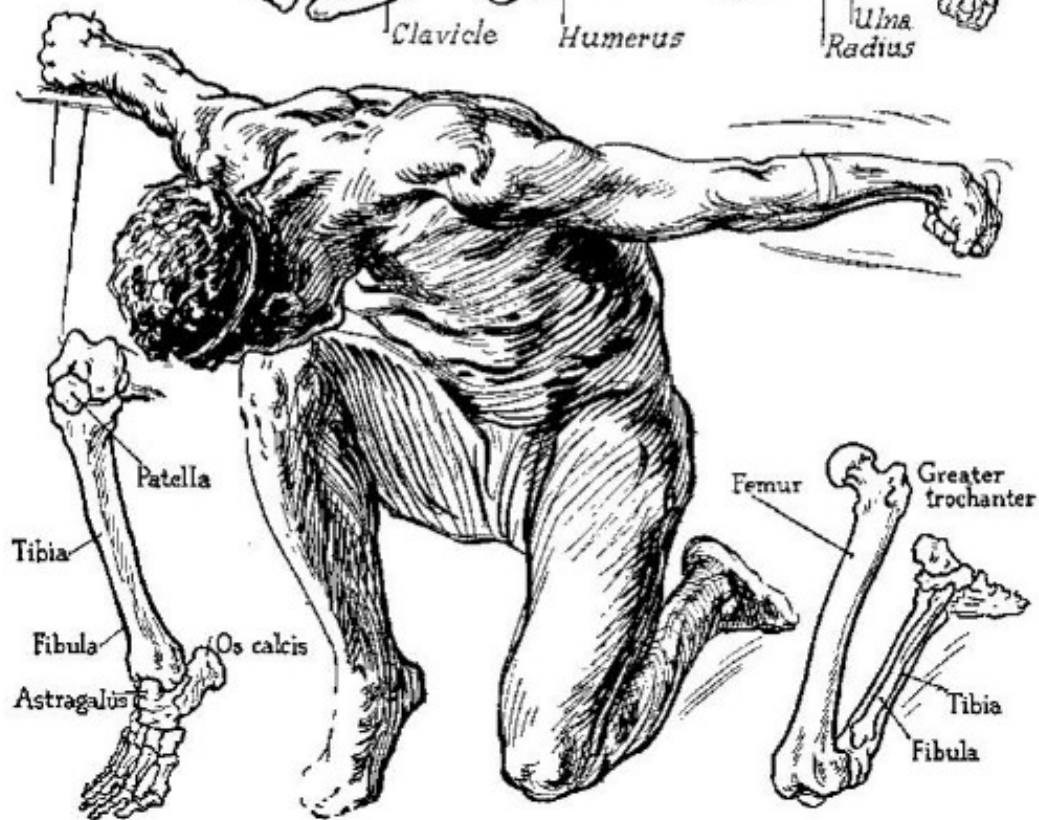
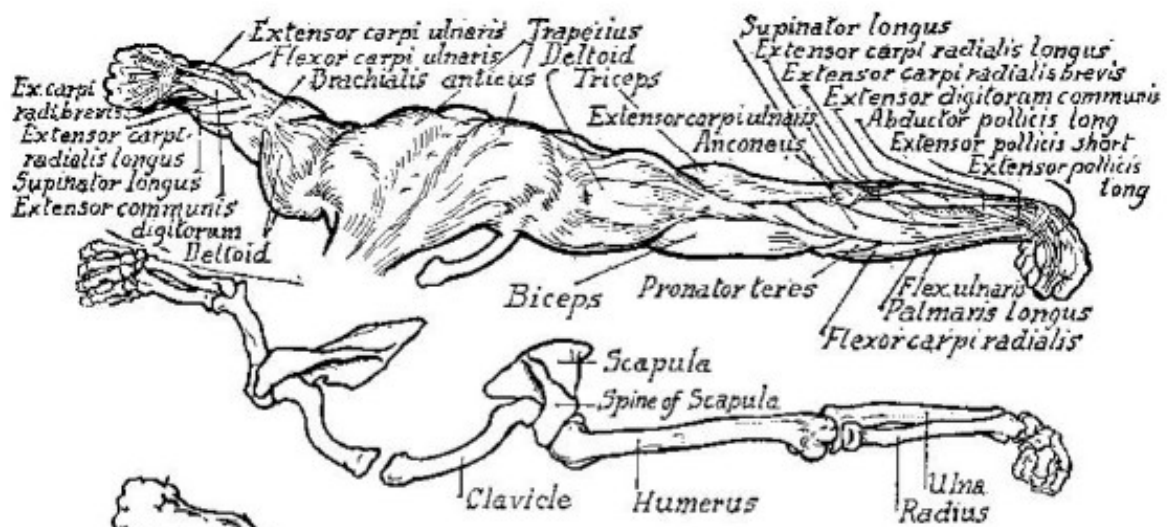


*Outer View of Right Arm*

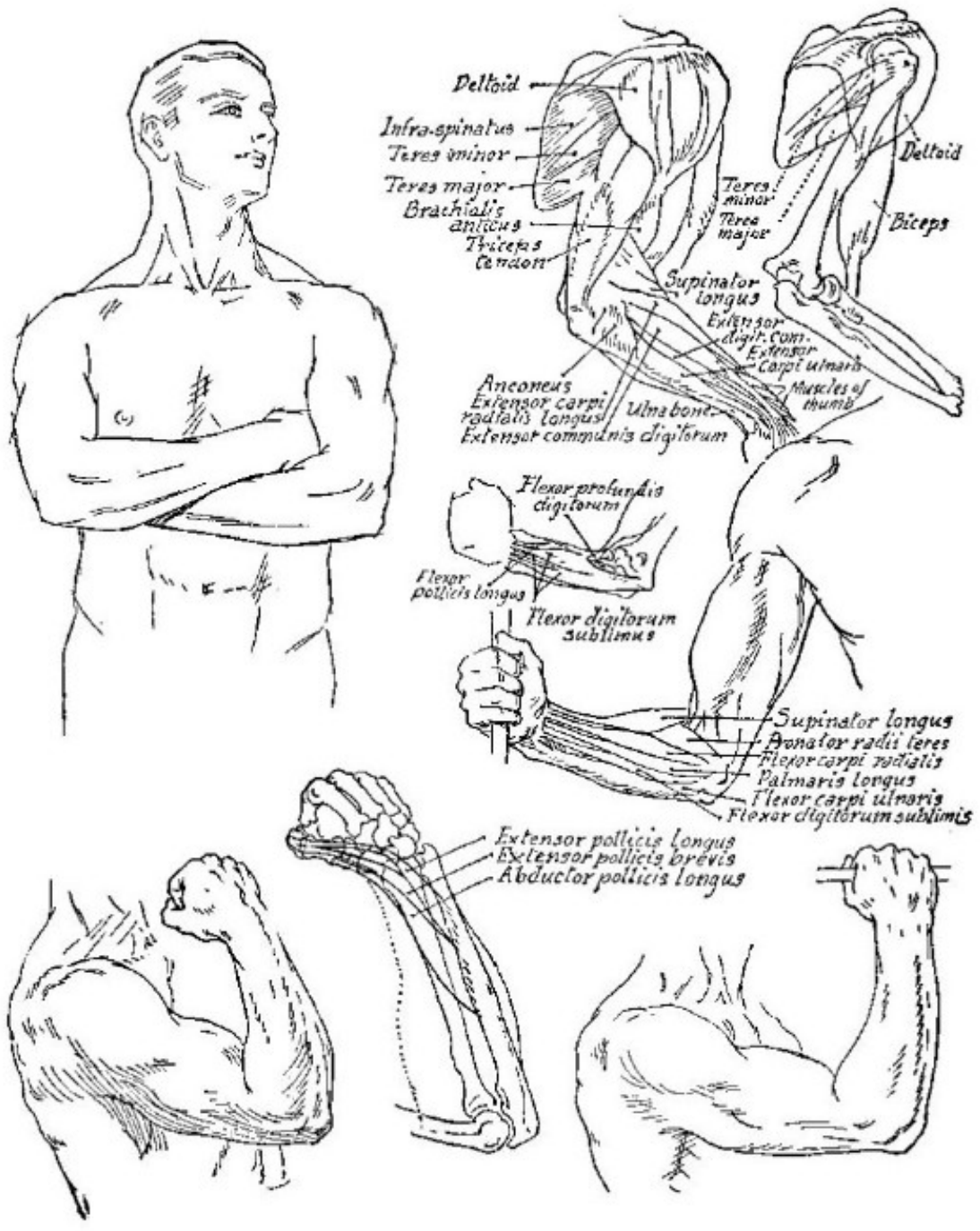


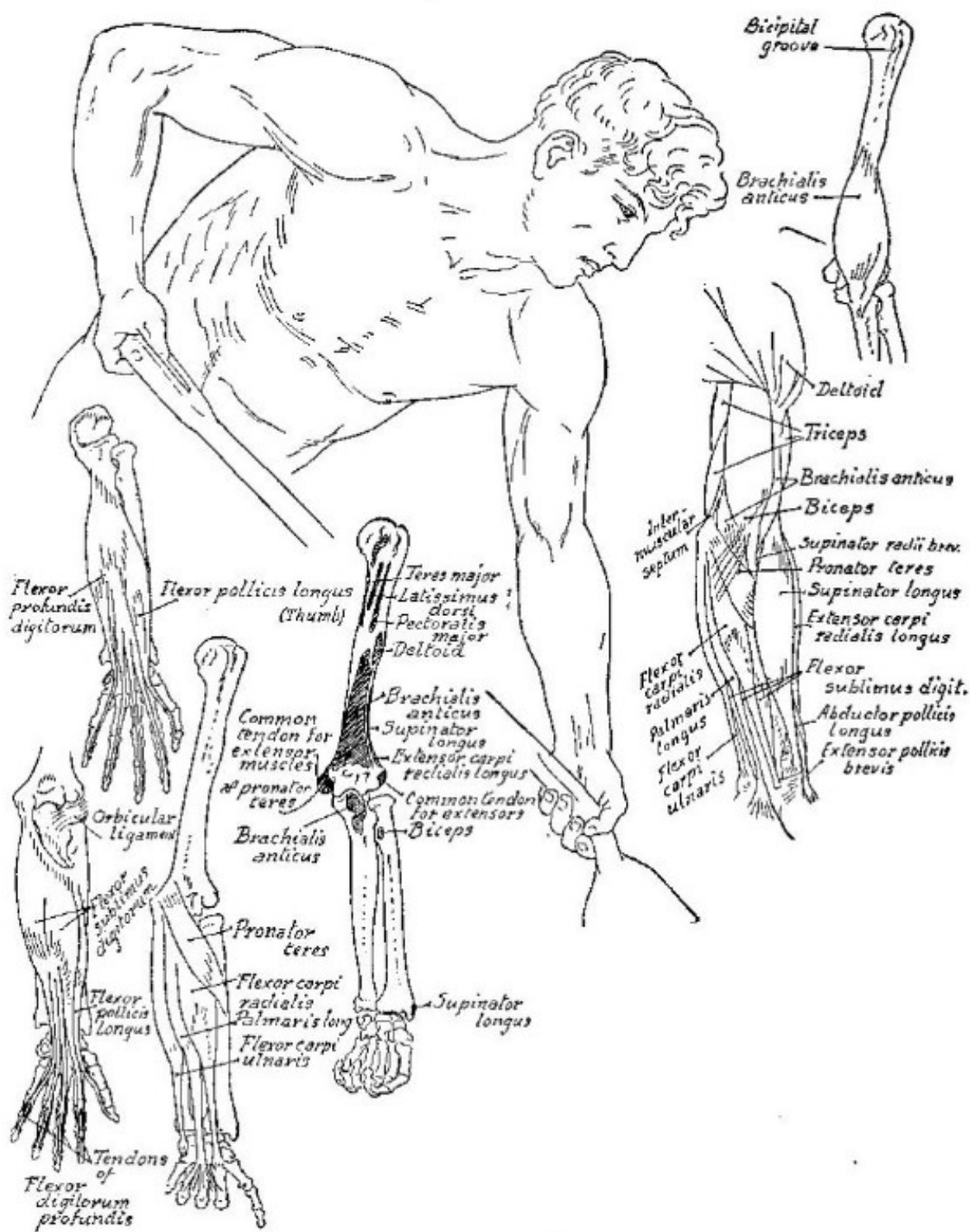
*Inner view*



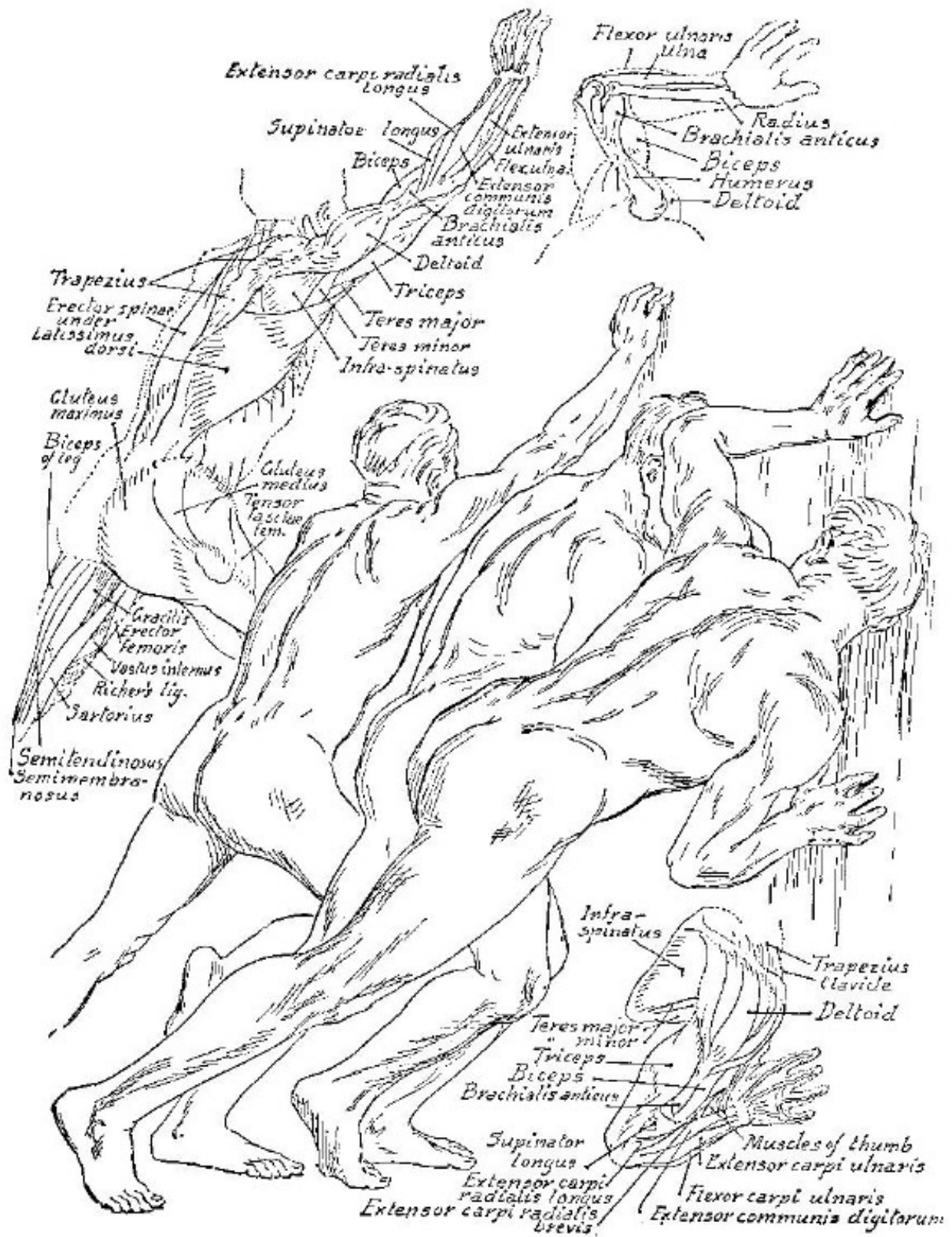










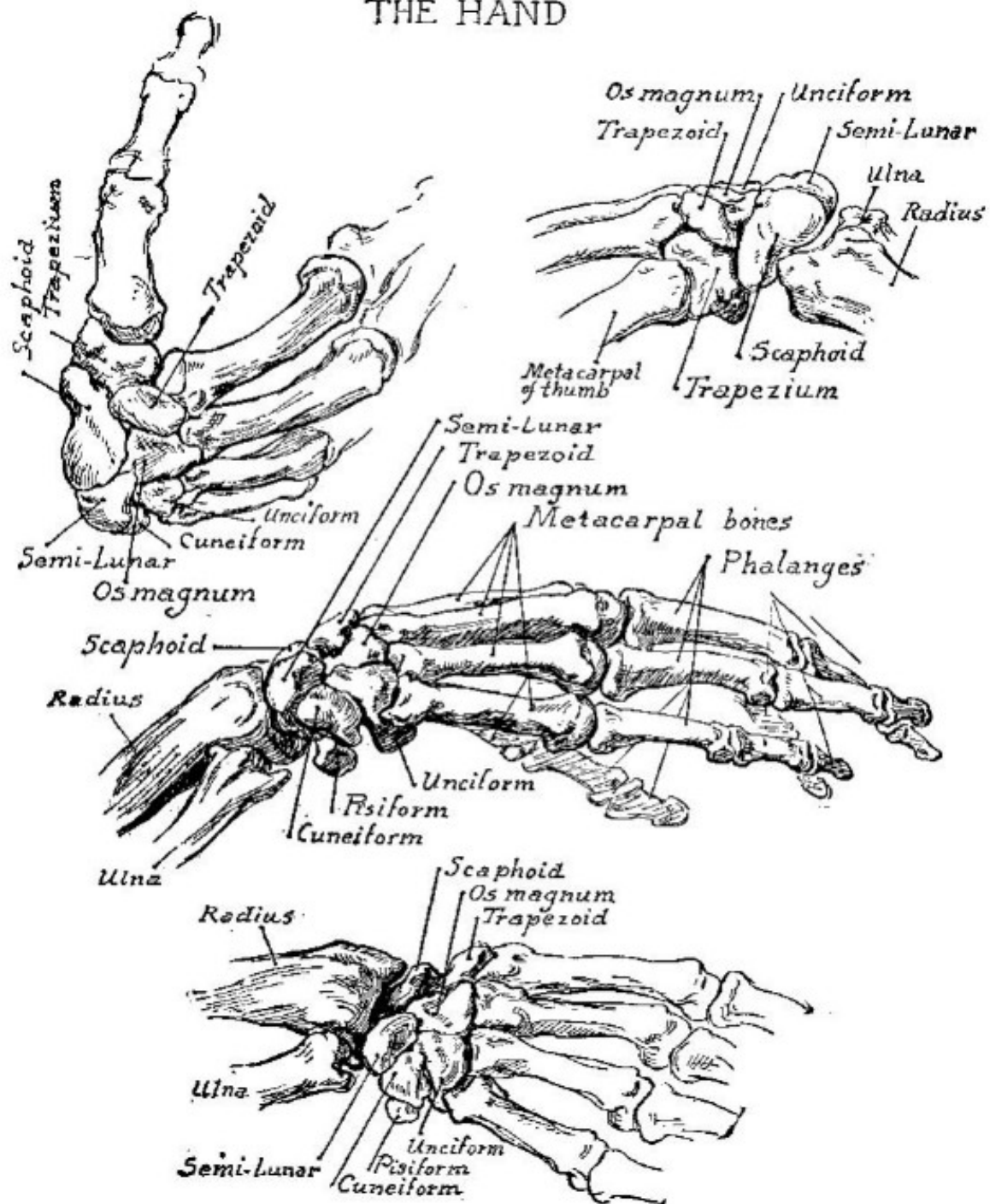


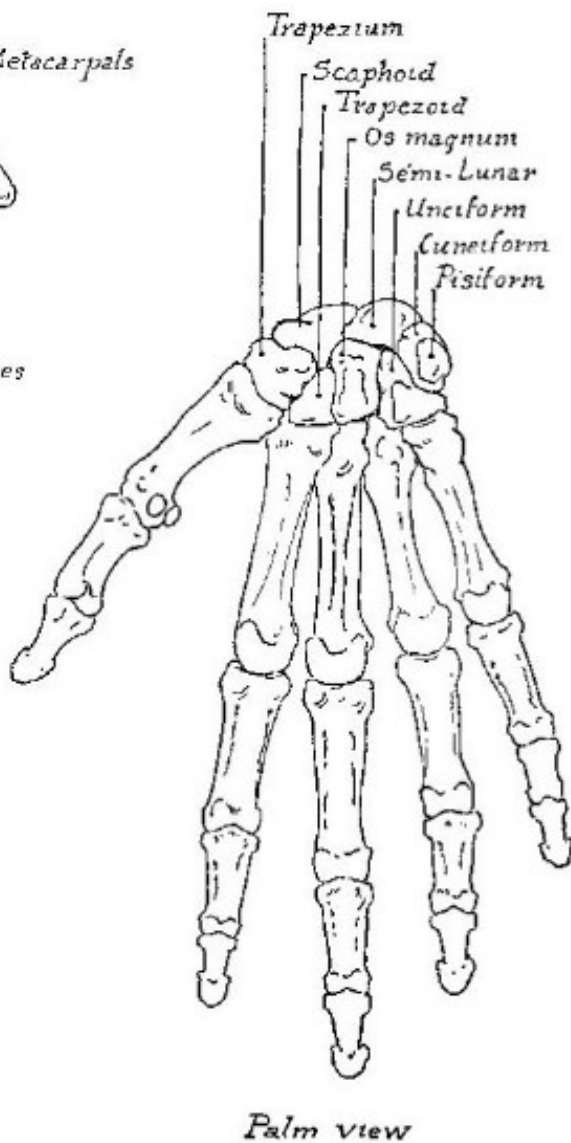
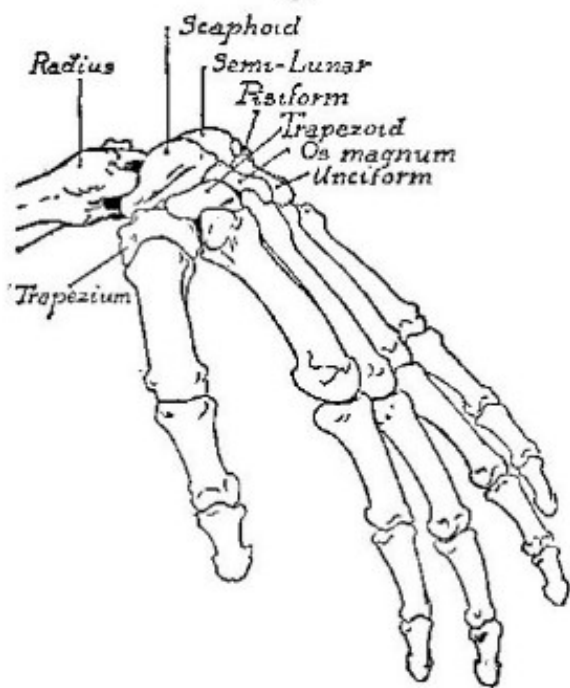
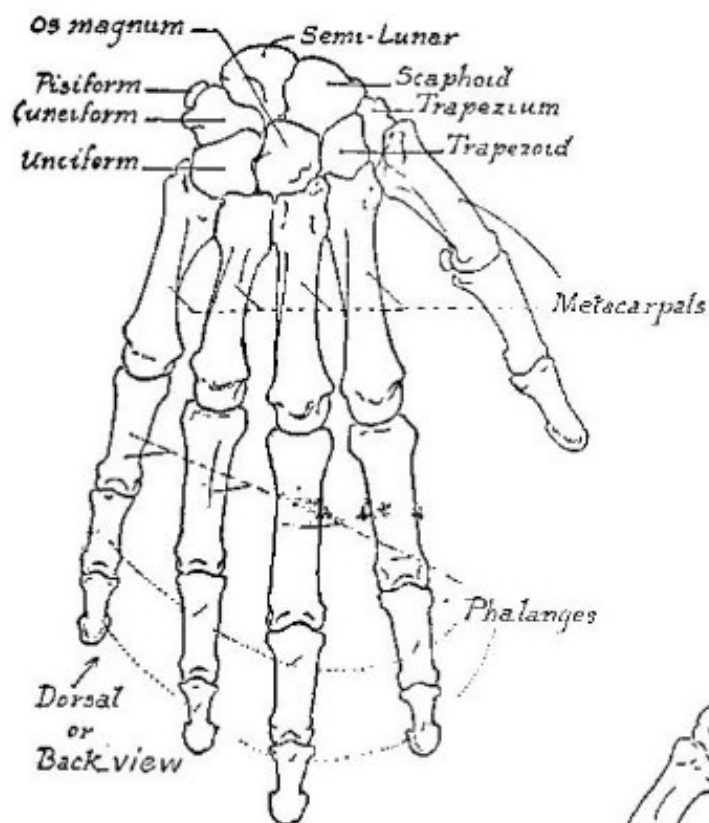


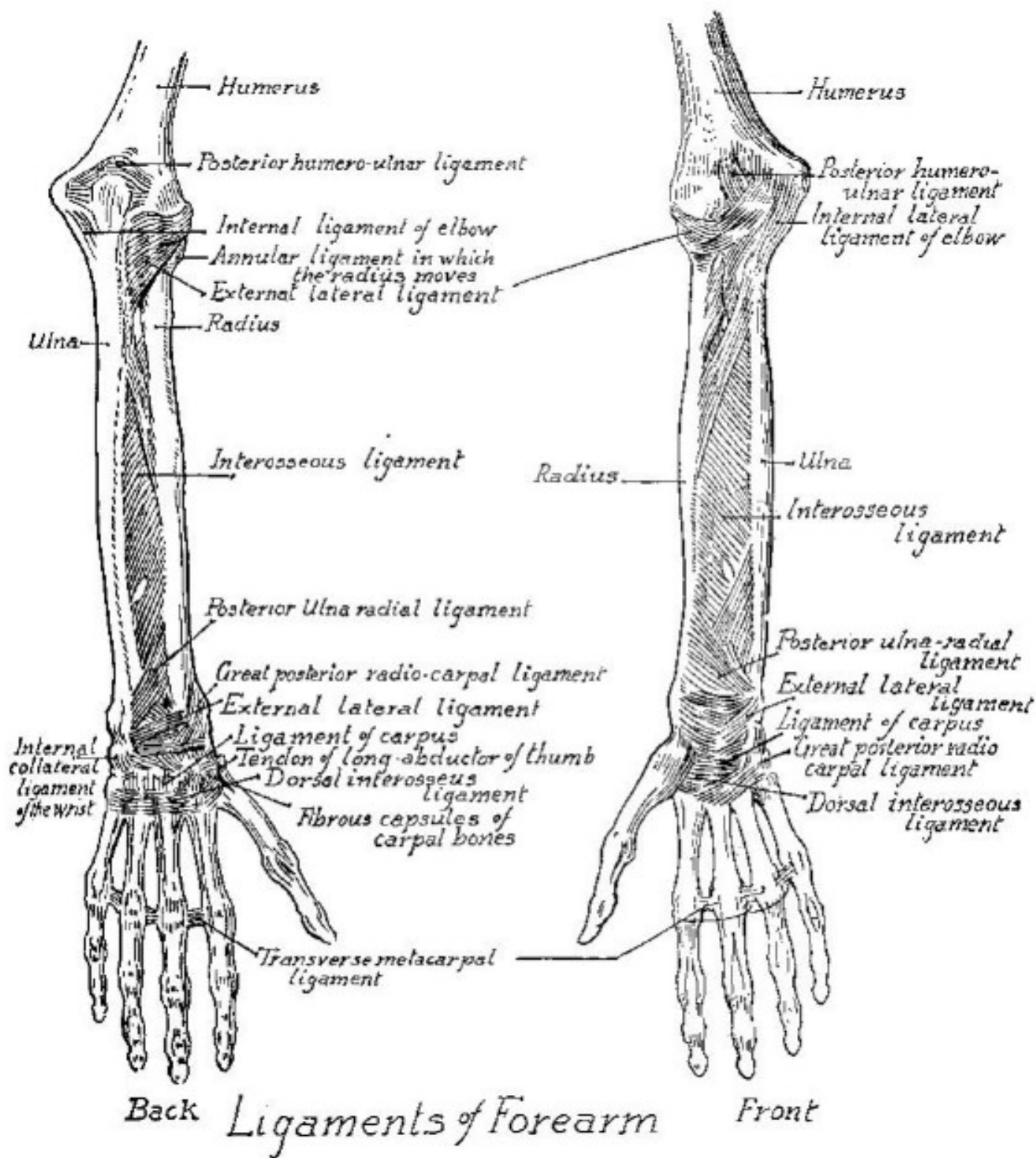
Part VI

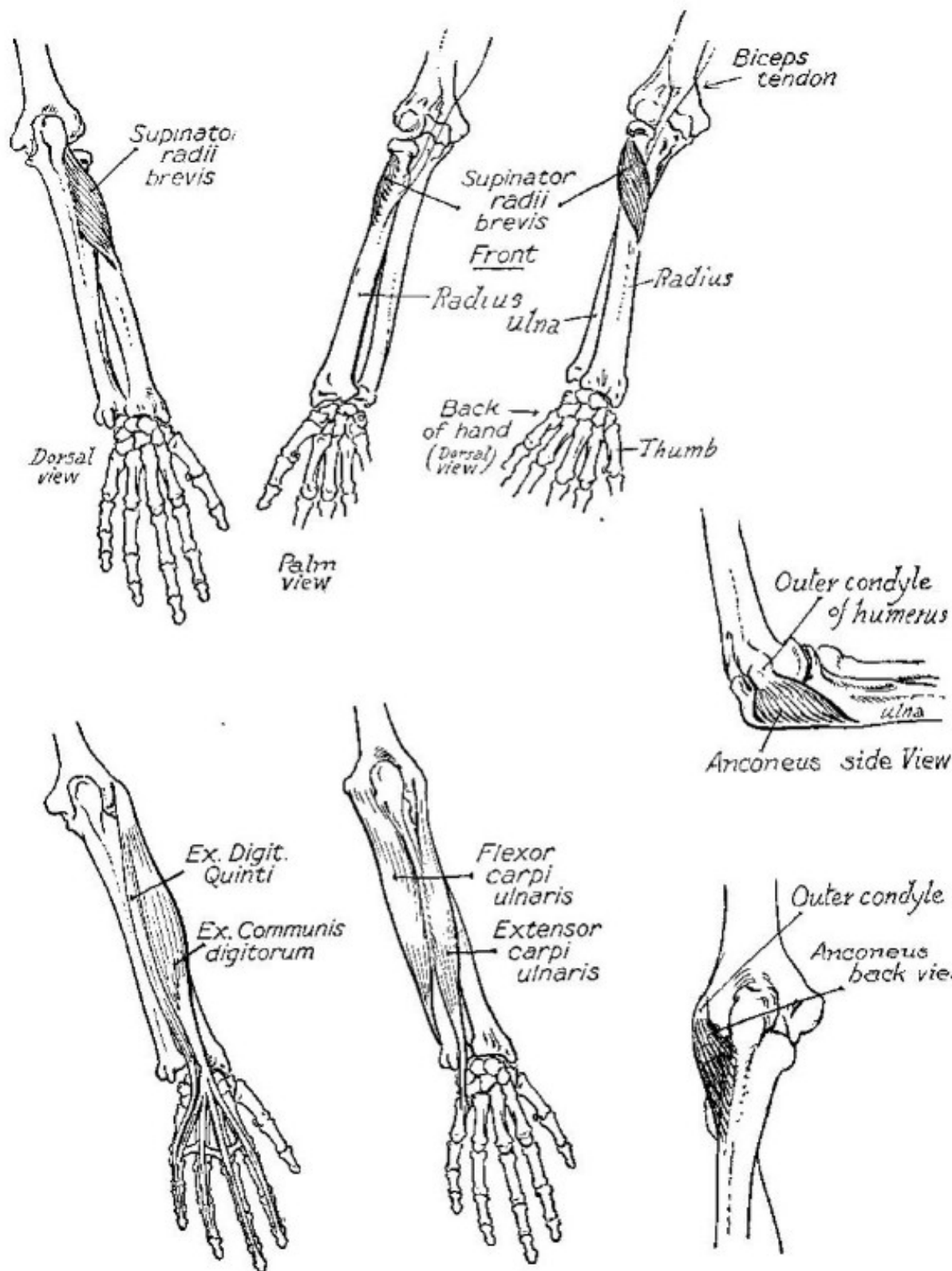
## *The Hand*

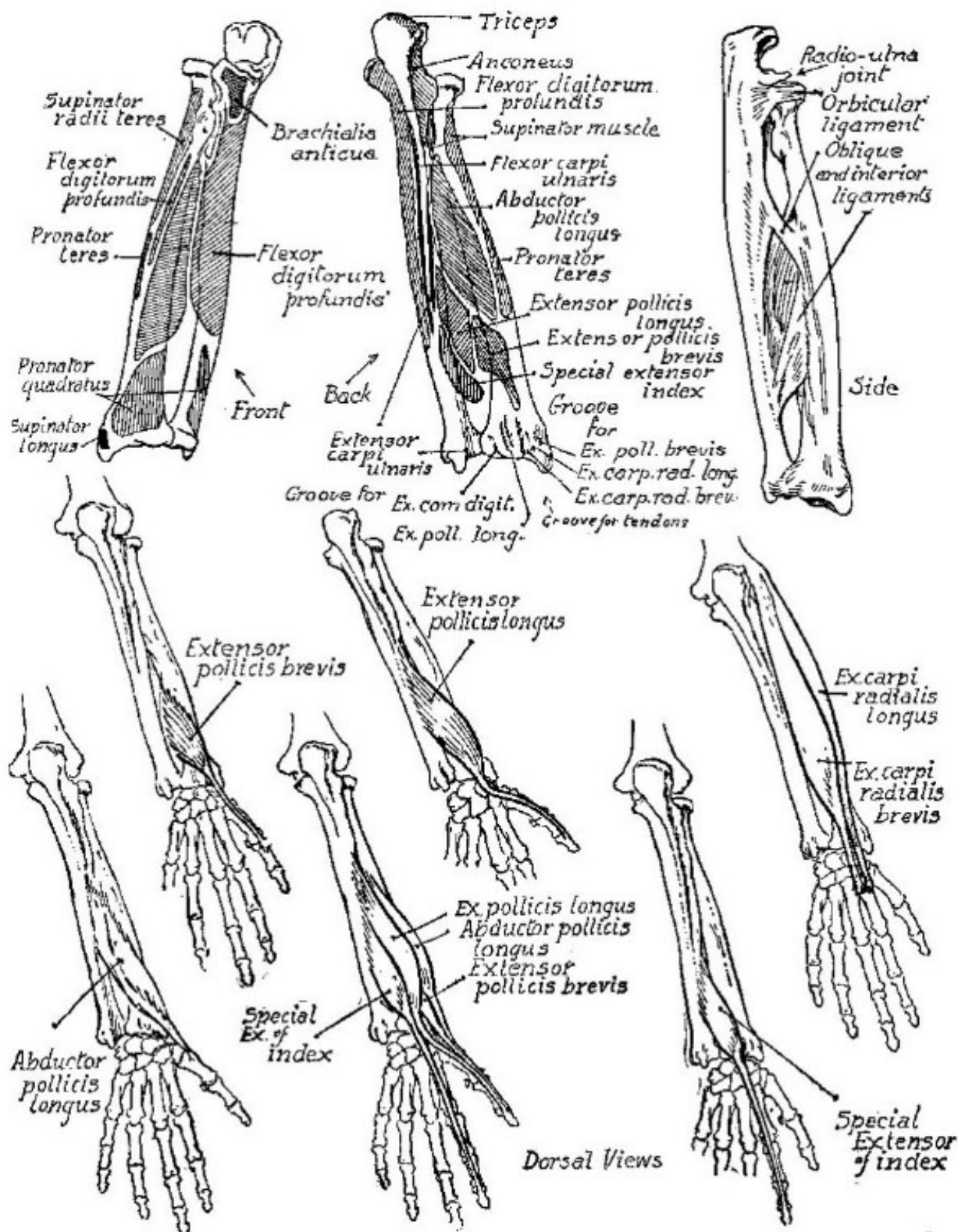
# THE HAND

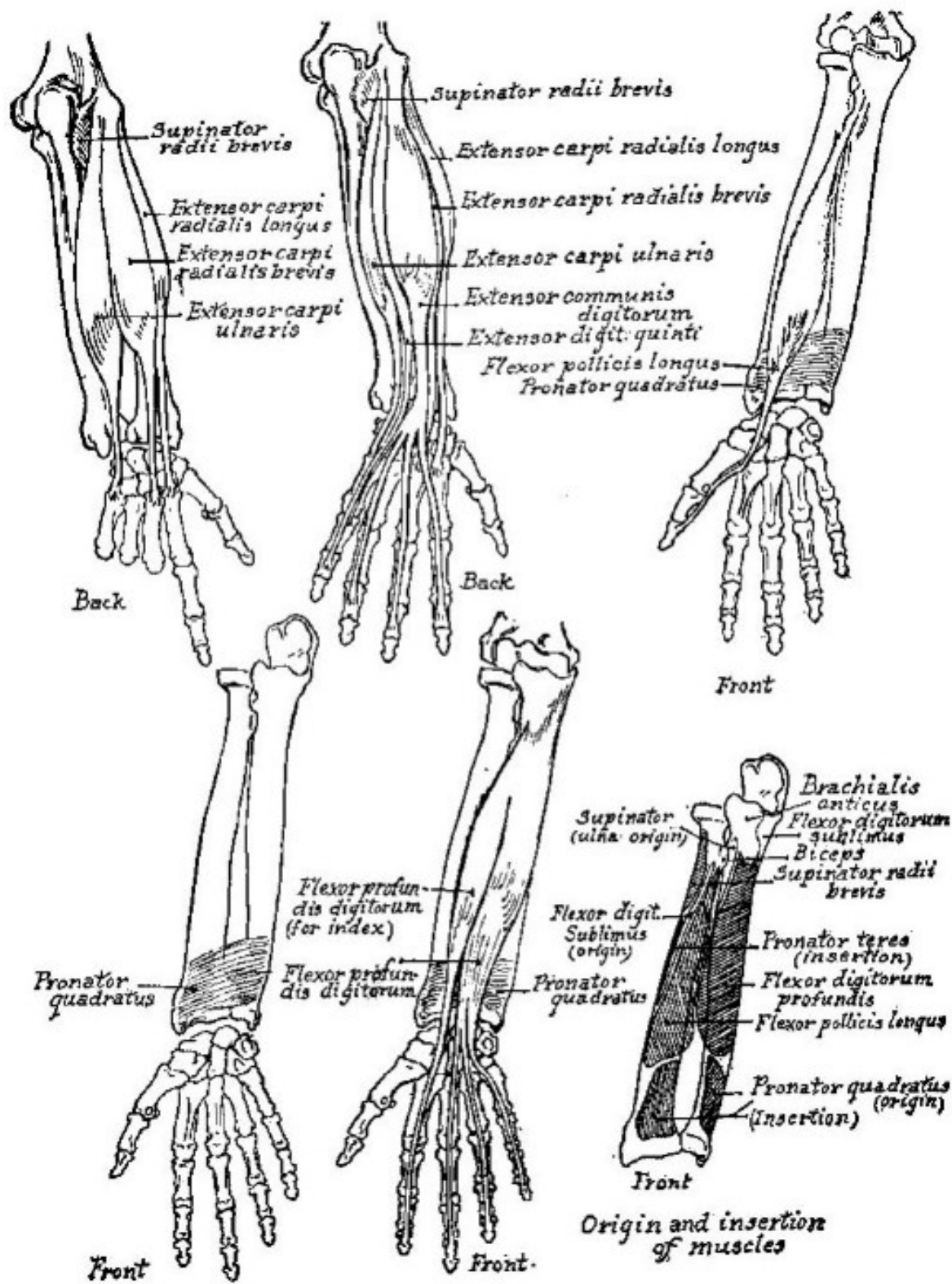




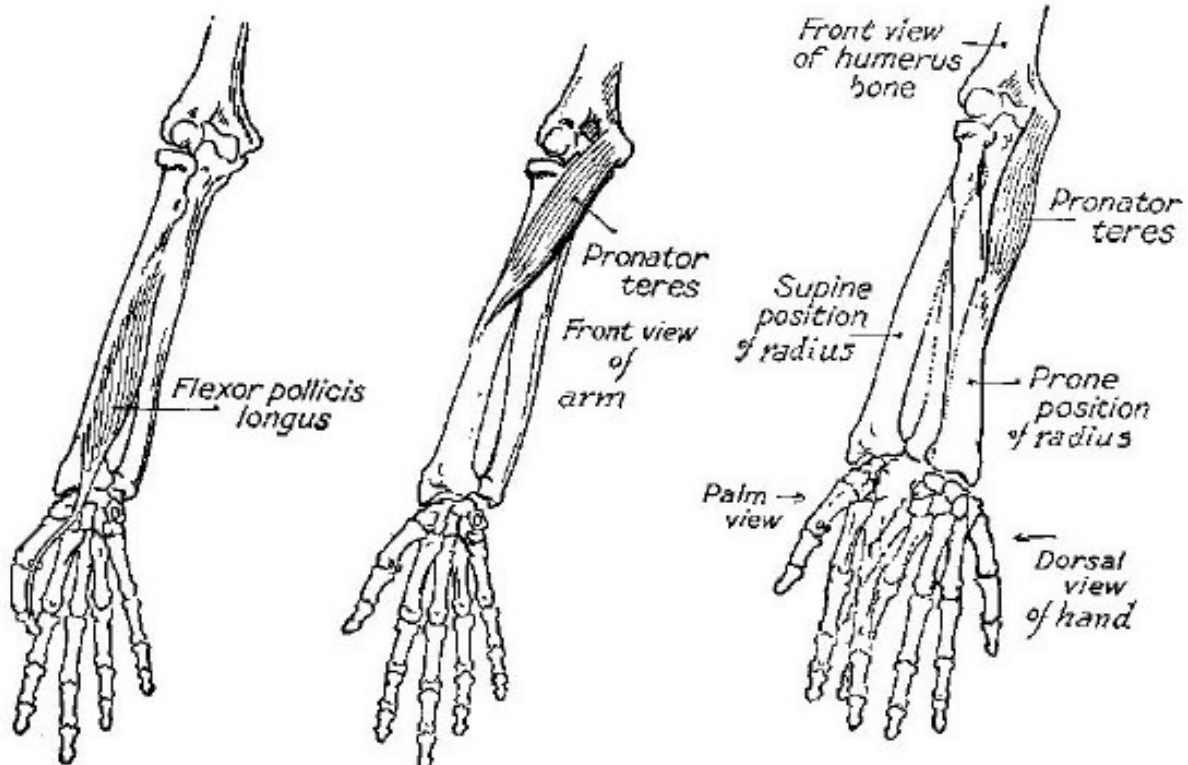
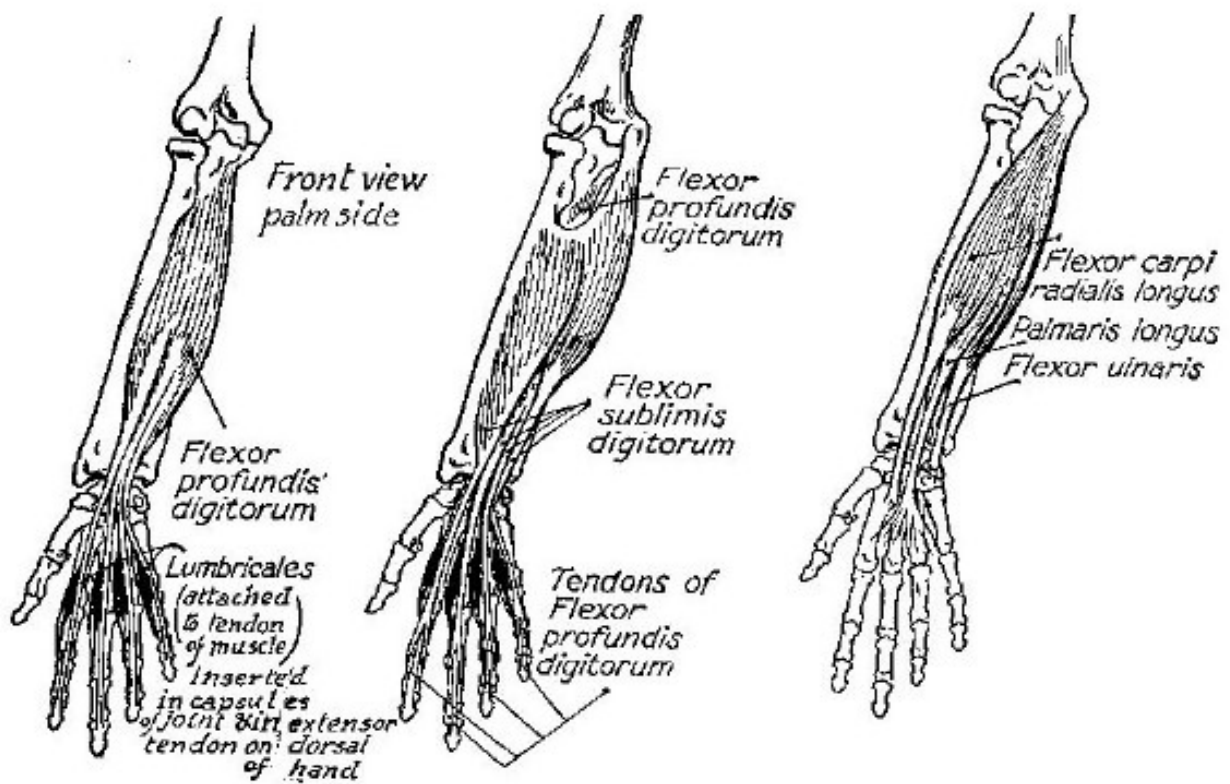


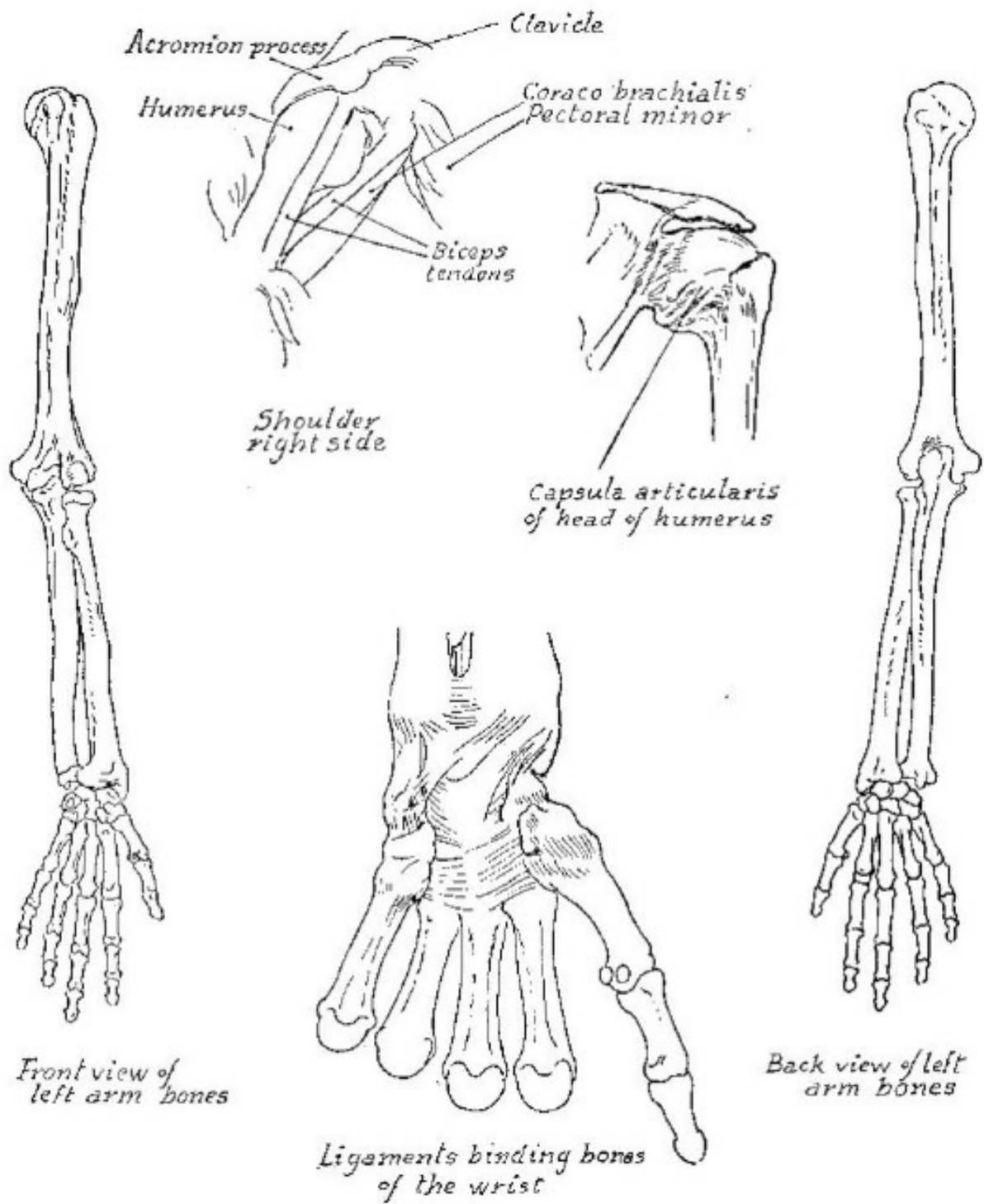


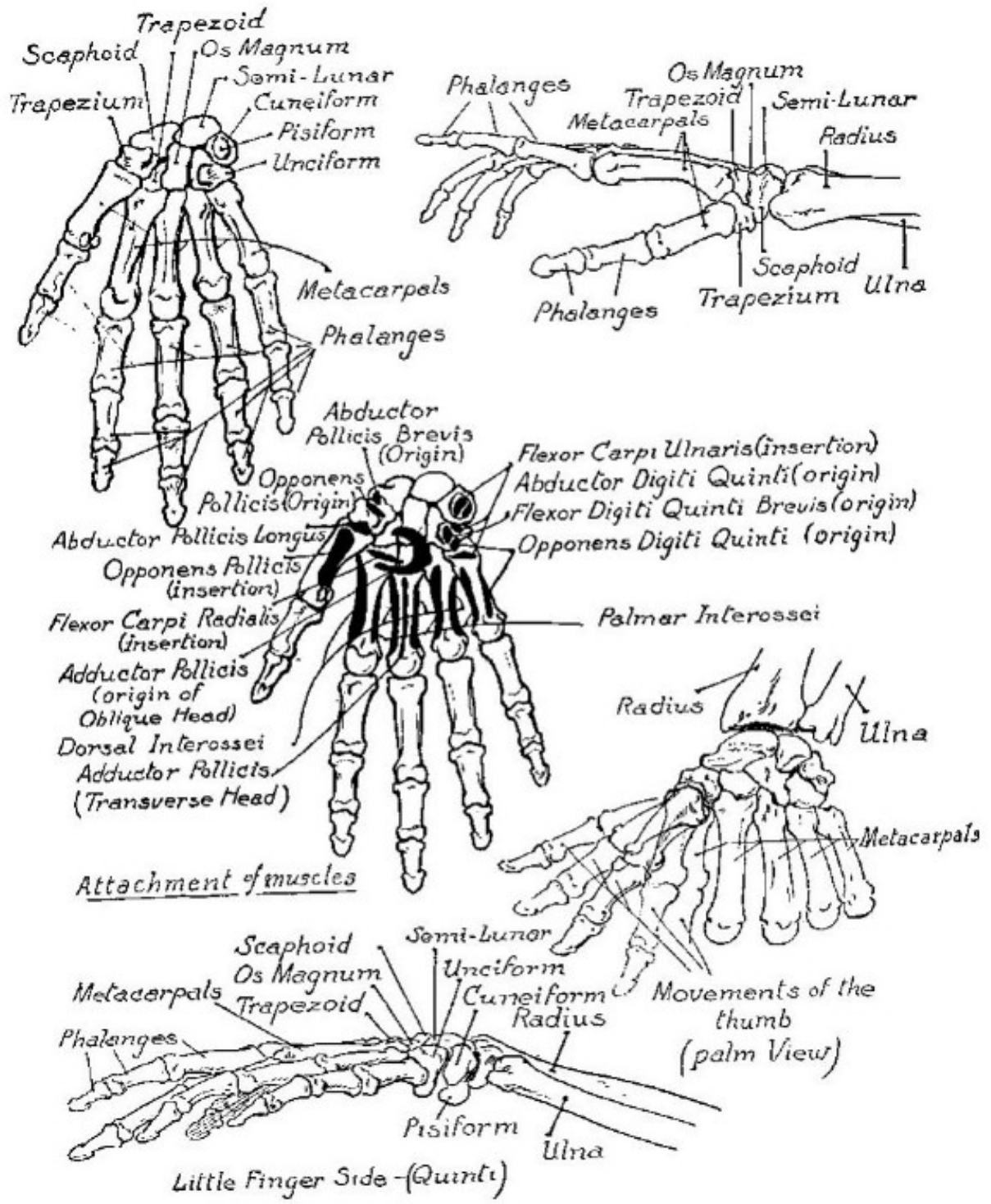




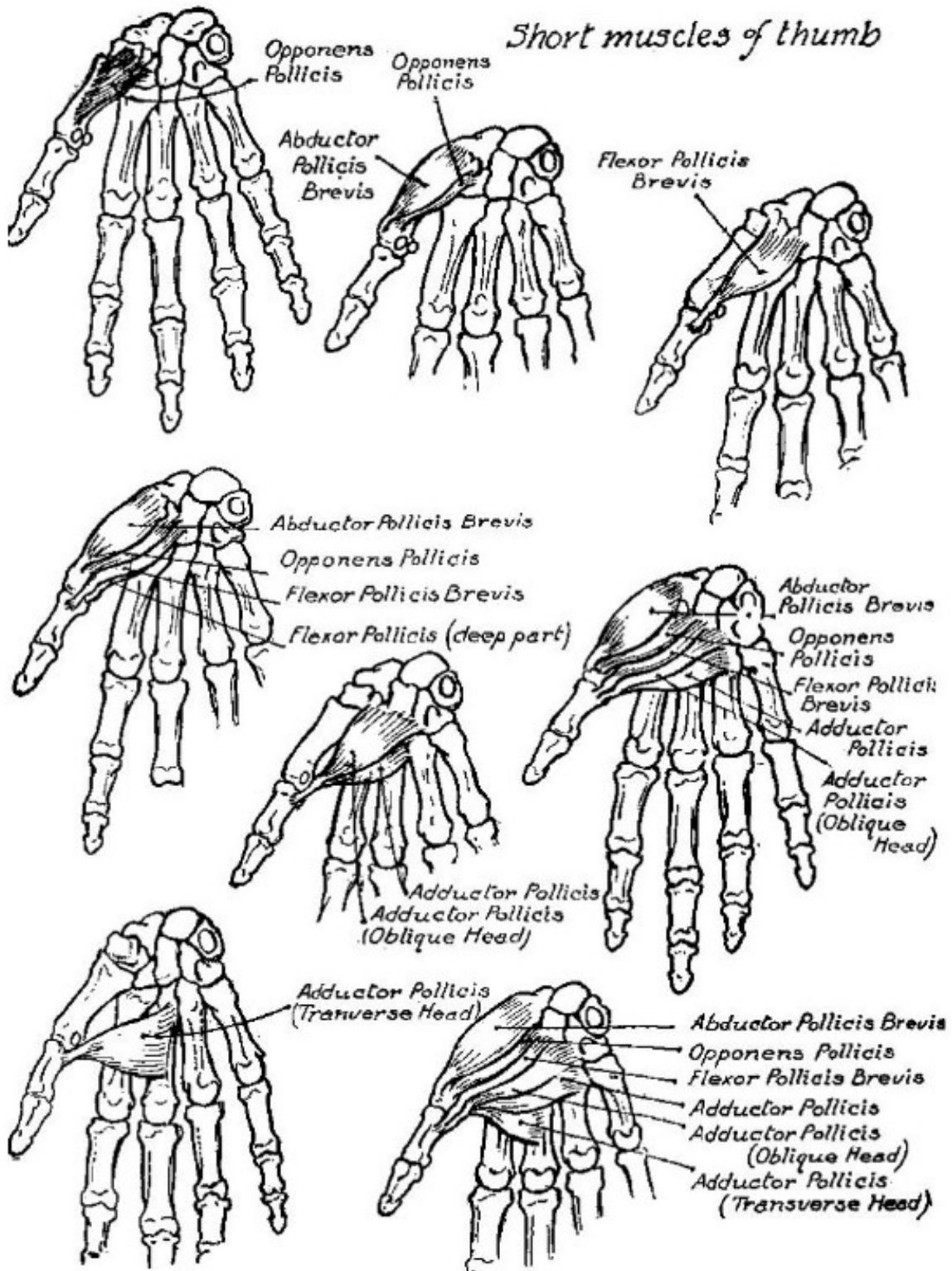


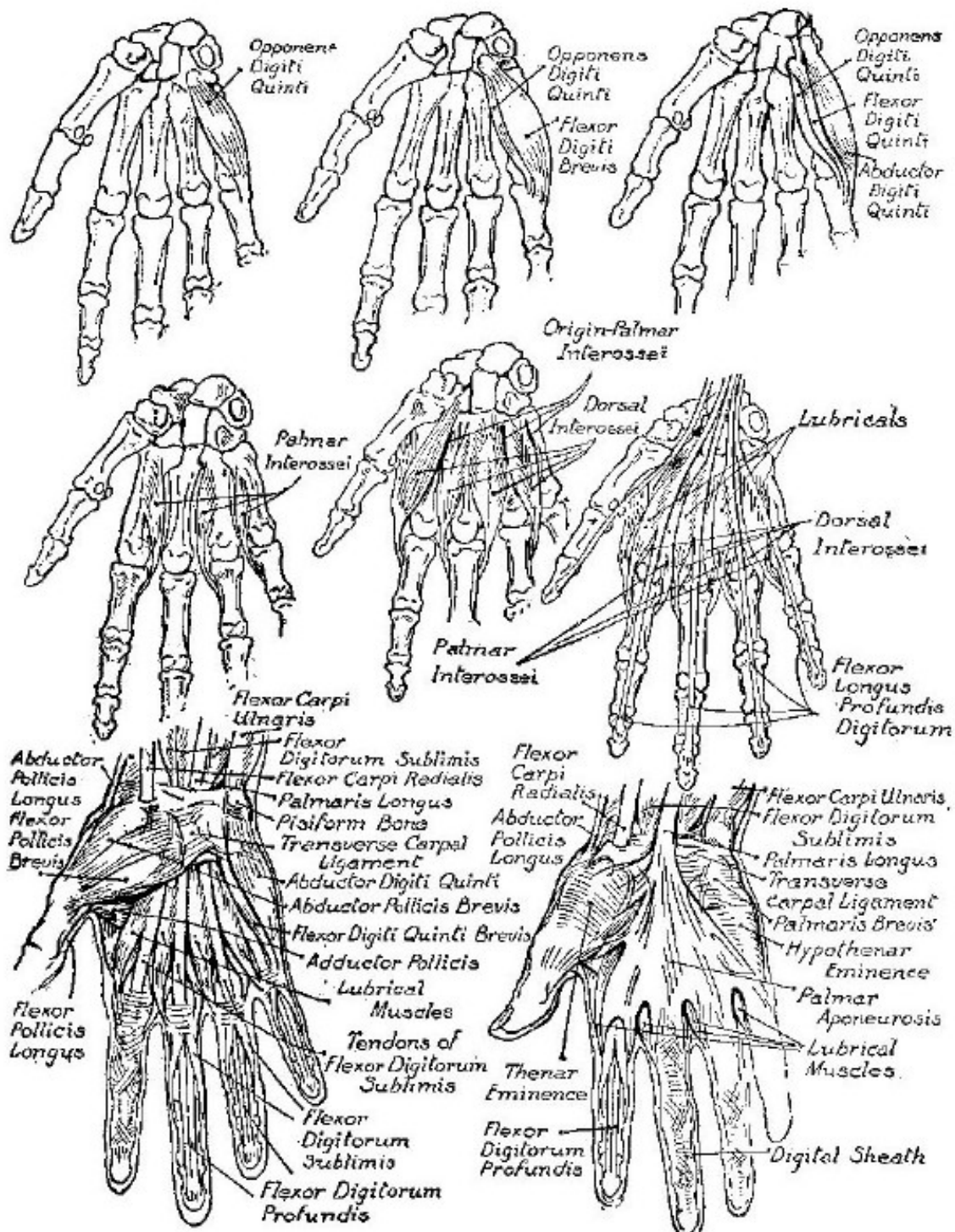


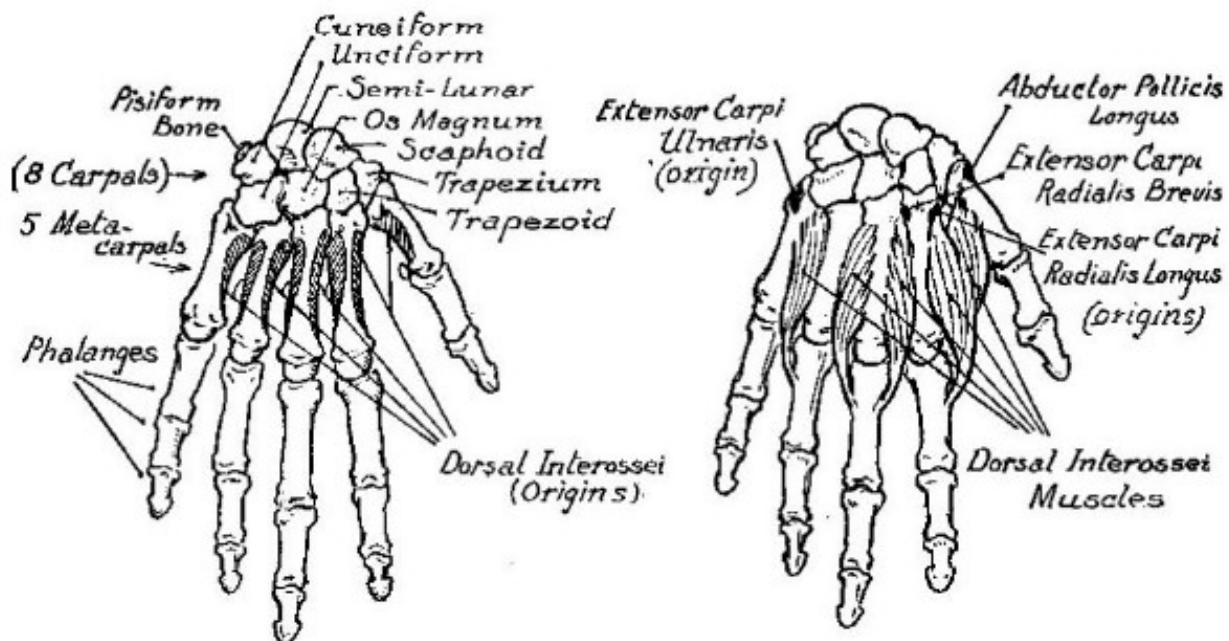




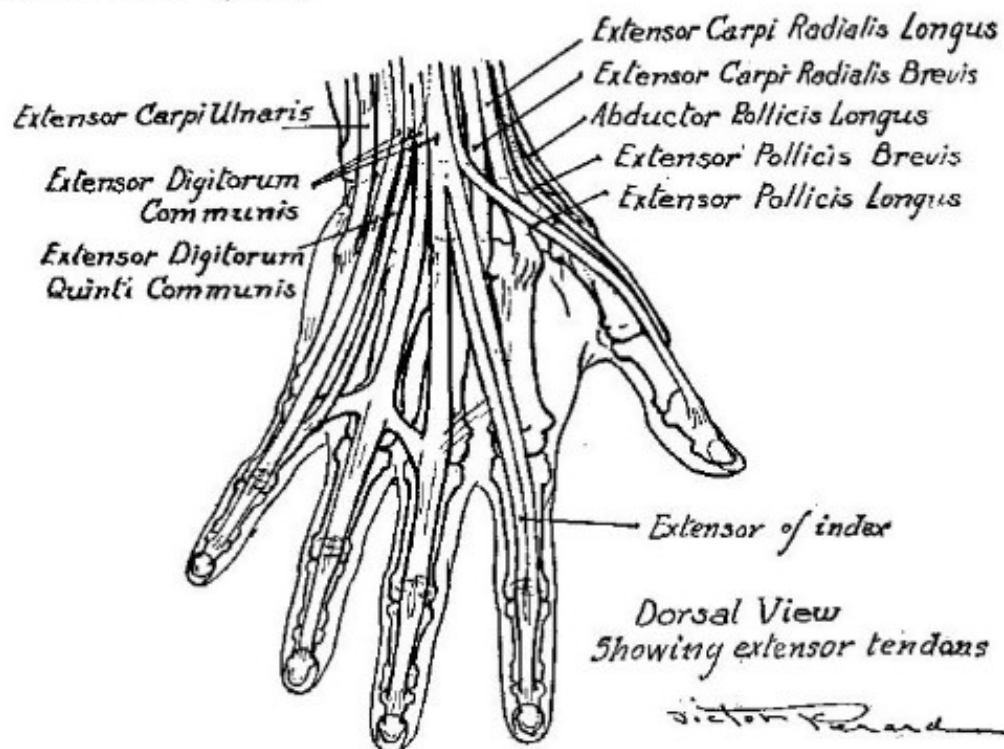
## Short muscles of thumb

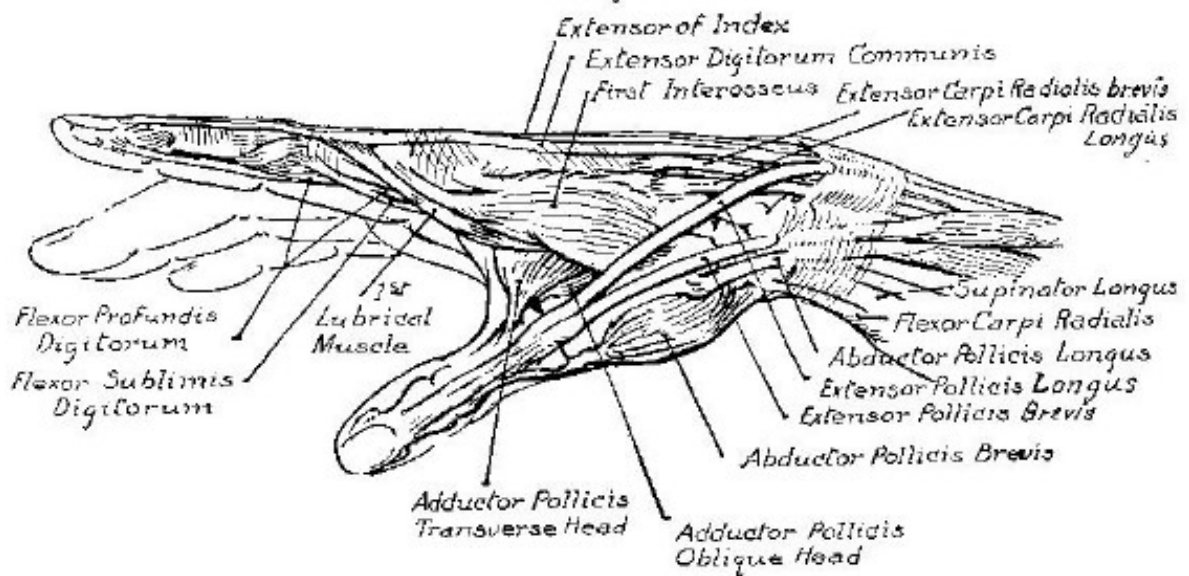


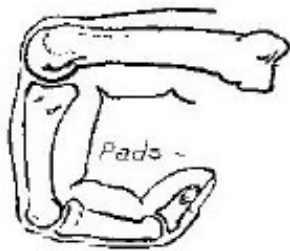
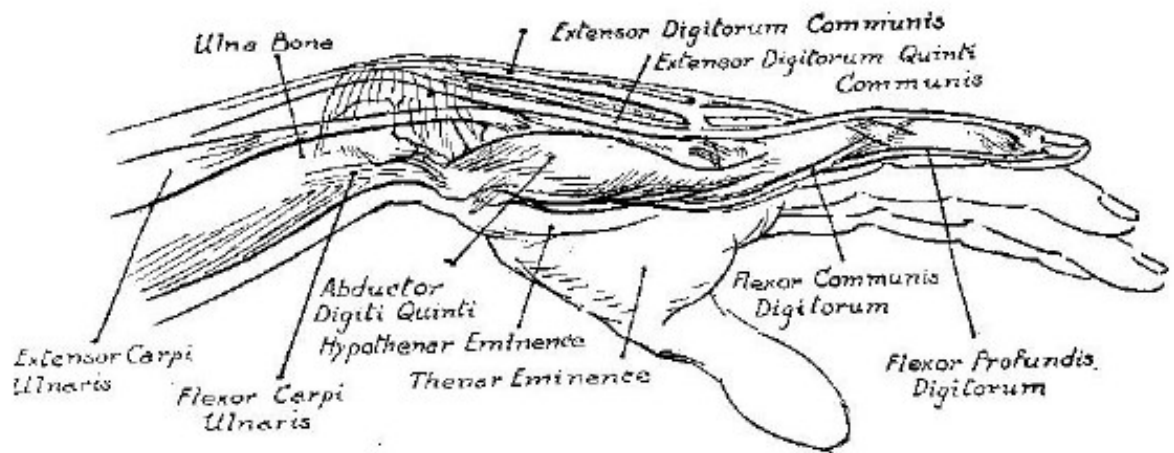




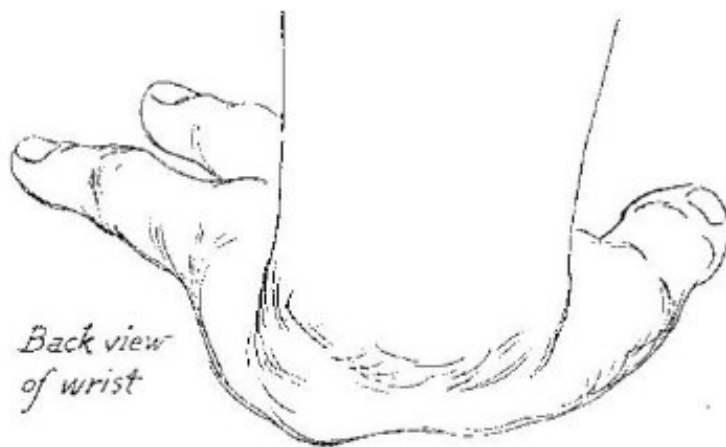


*Dorsal View (back)*

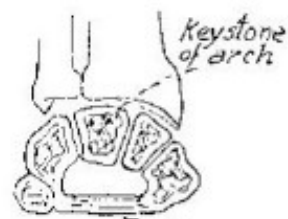




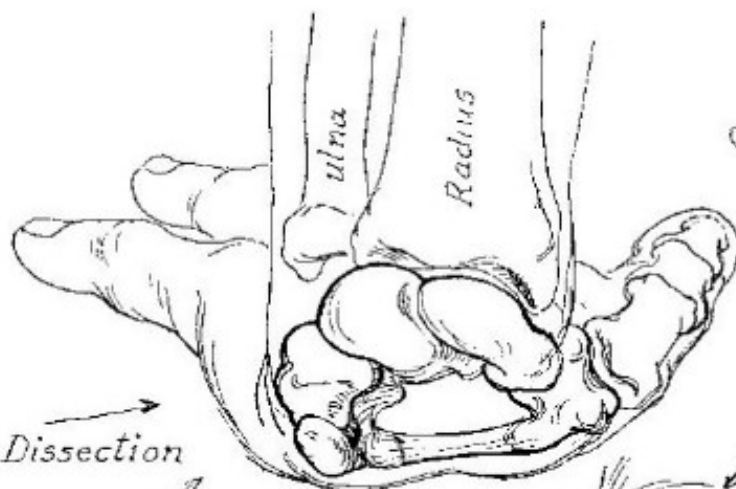




*Back view  
of wrist*

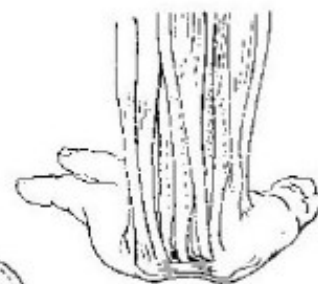

*Keystone  
of arch*  
  
*Annular ligament.  
Sectional view of  
wrist bones*

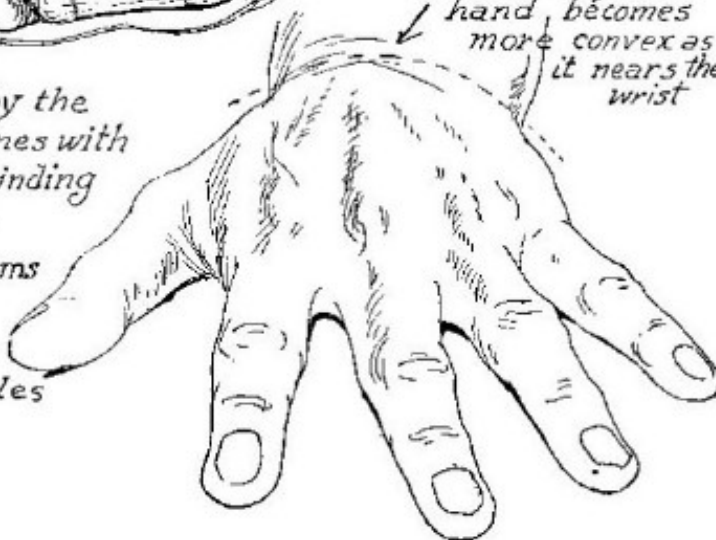

*Dissection*

*The arch formed by the  
group of wrist bones with  
the ligament binding  
the two hook like  
processes. This forms  
a canal through  
which the tendons  
of the flexor muscles  
pass.*

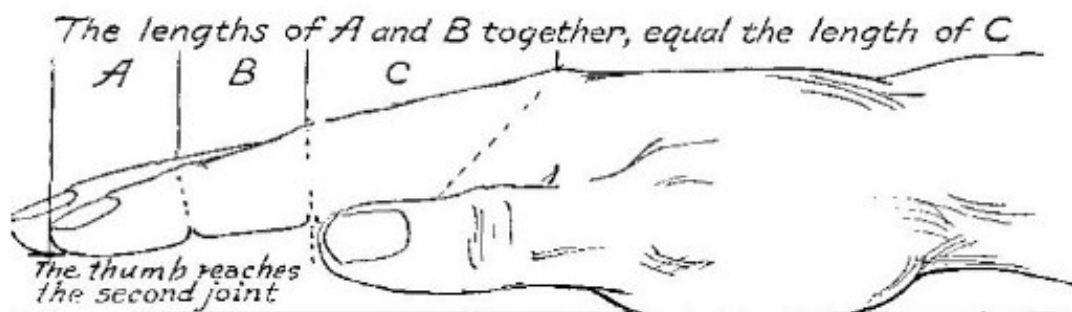


*Flexor tendons  
passing under the  
arch of the wrist  
bones.*

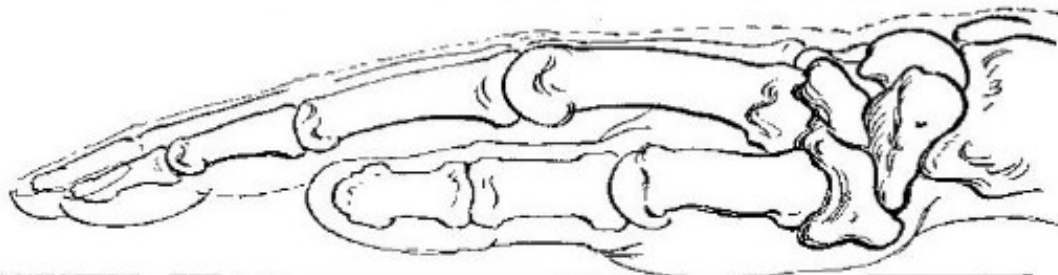


*The back of the  
hand becomes  
more convex as  
it nears the  
wrist*

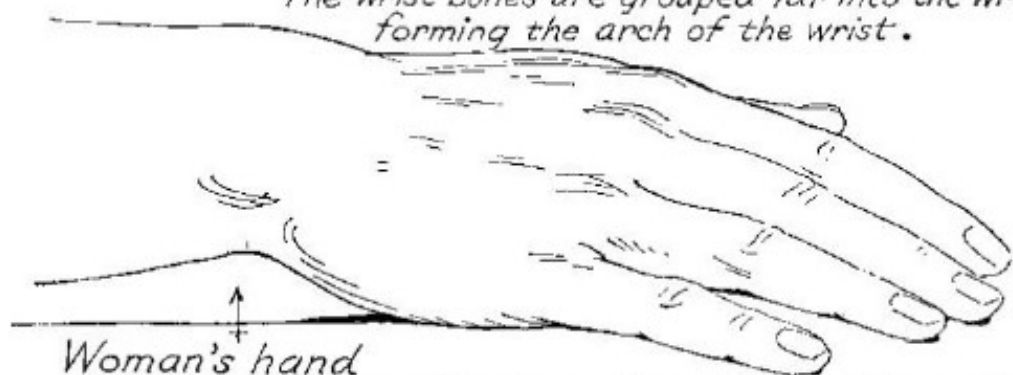




When the hand is resting on a flat surface, the wrist does not come in contact with that surface.

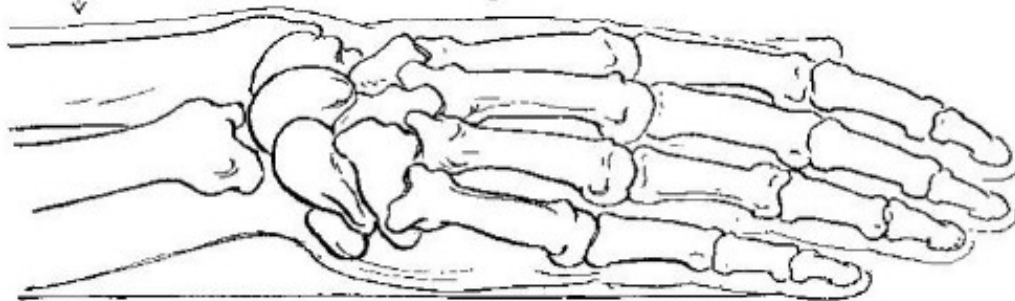


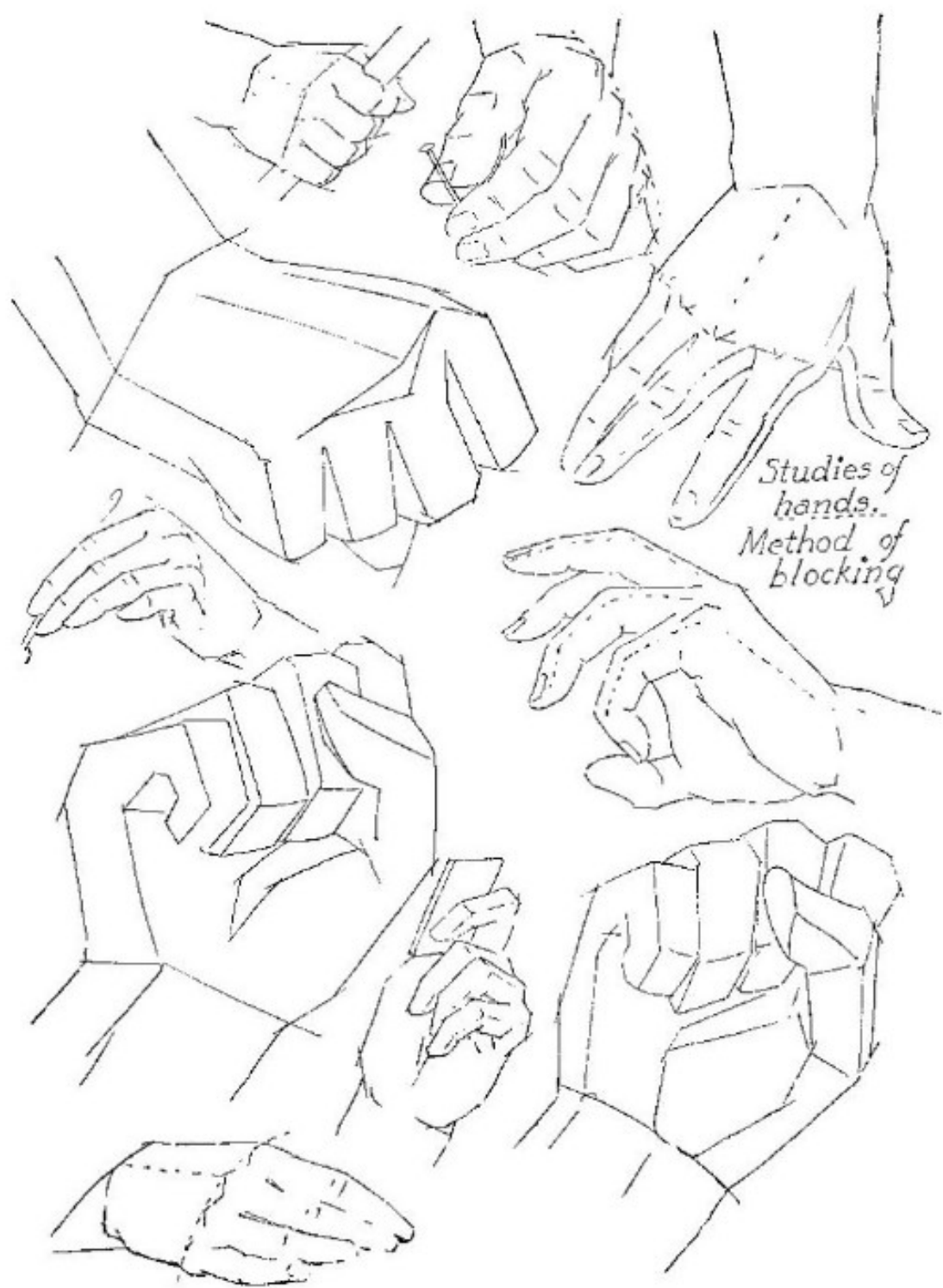
The wrist bones are grouped far into the wrist forming the arch of the wrist.



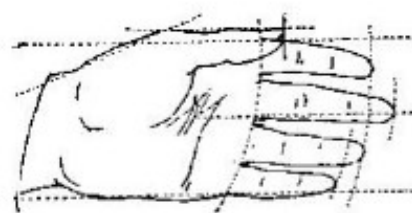
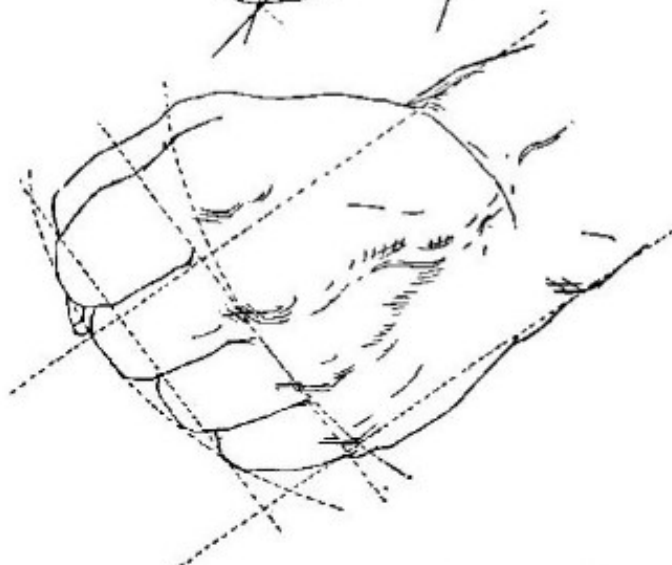

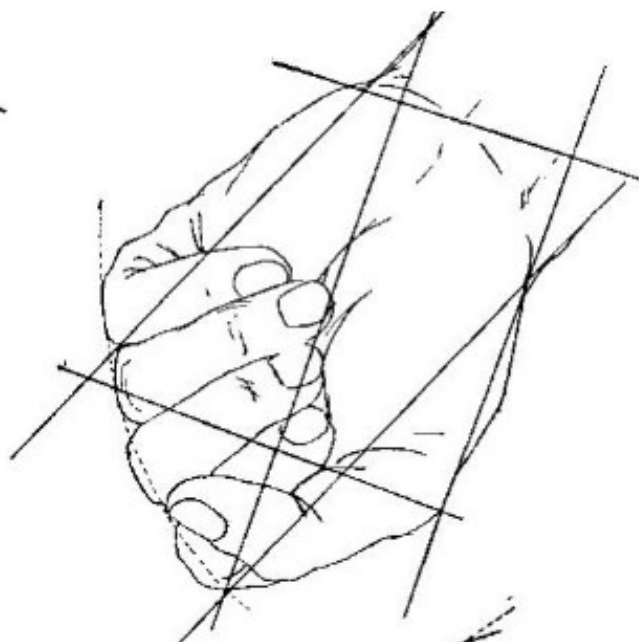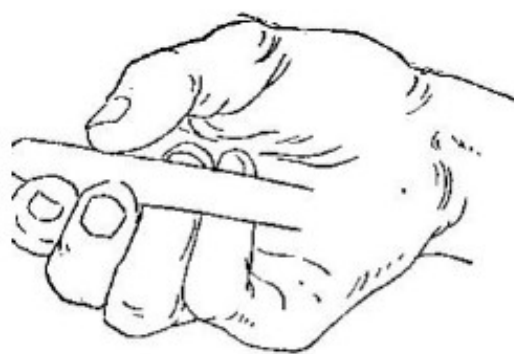
Woman's hand

Relative positions of the bones from the little finger side when the hand is resting on a flat surface.





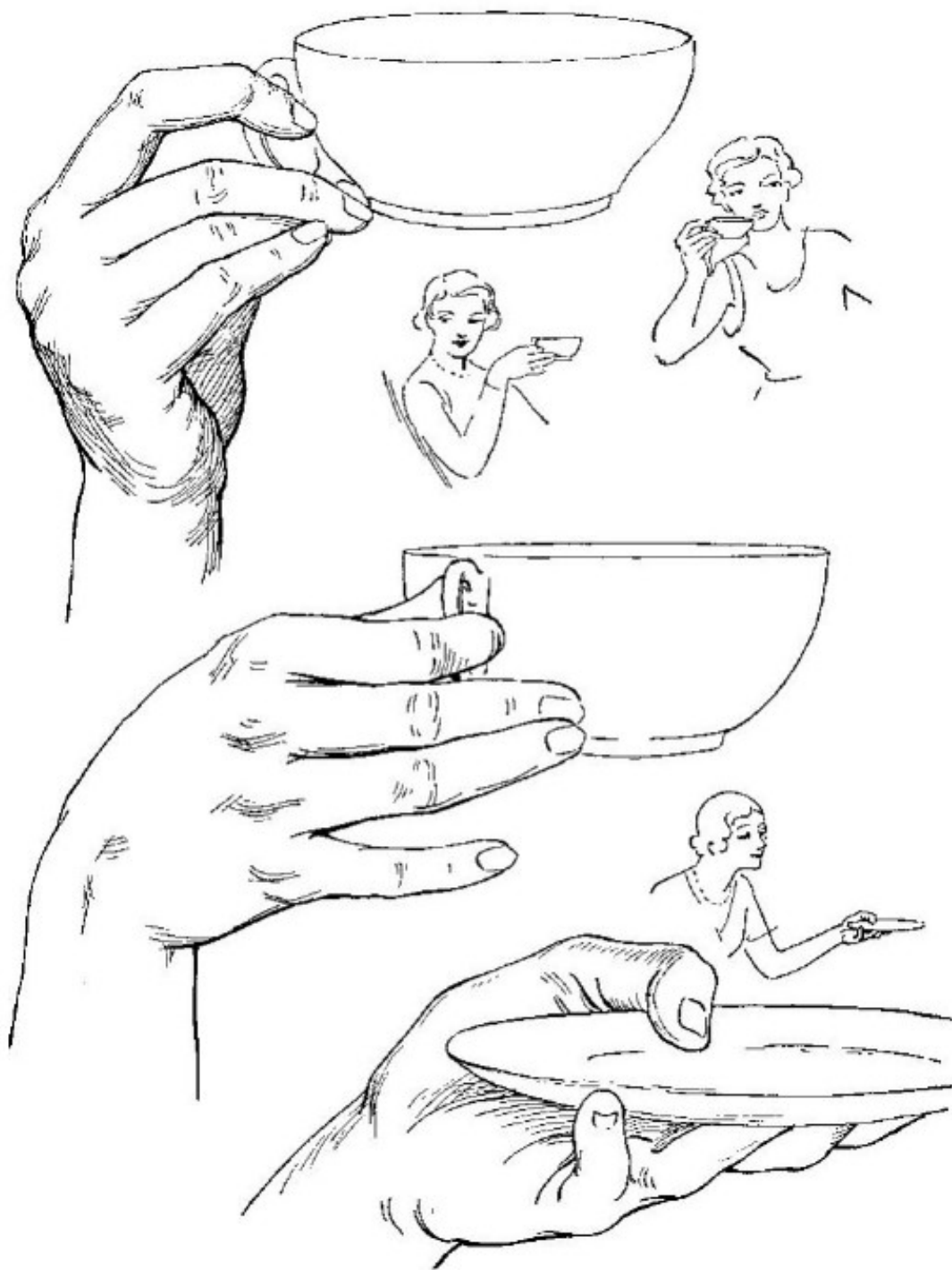
*Studies of  
hands.  
Method of  
blocking*

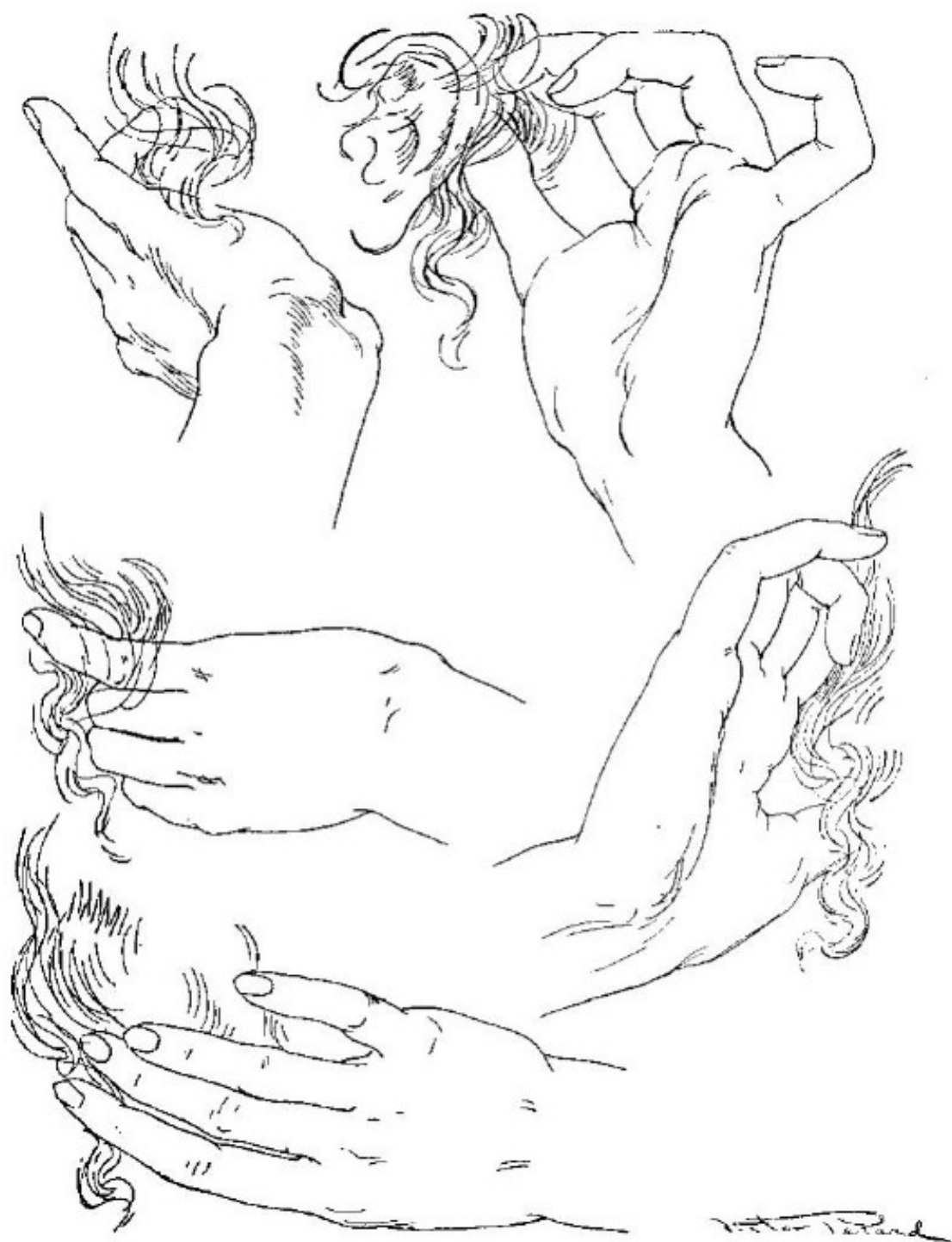

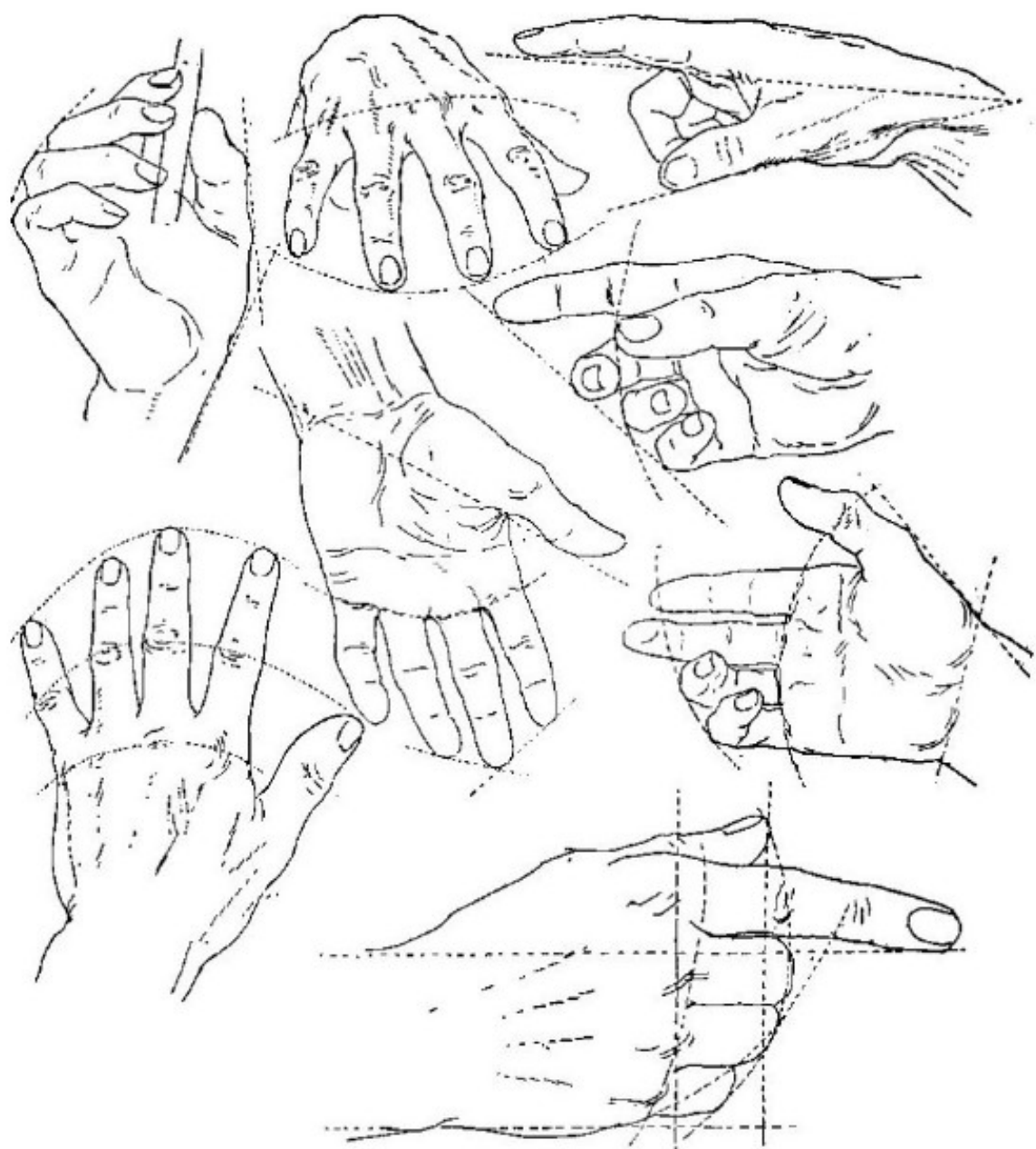
*Showing the use of imaginary lines  
to obtain proportion*



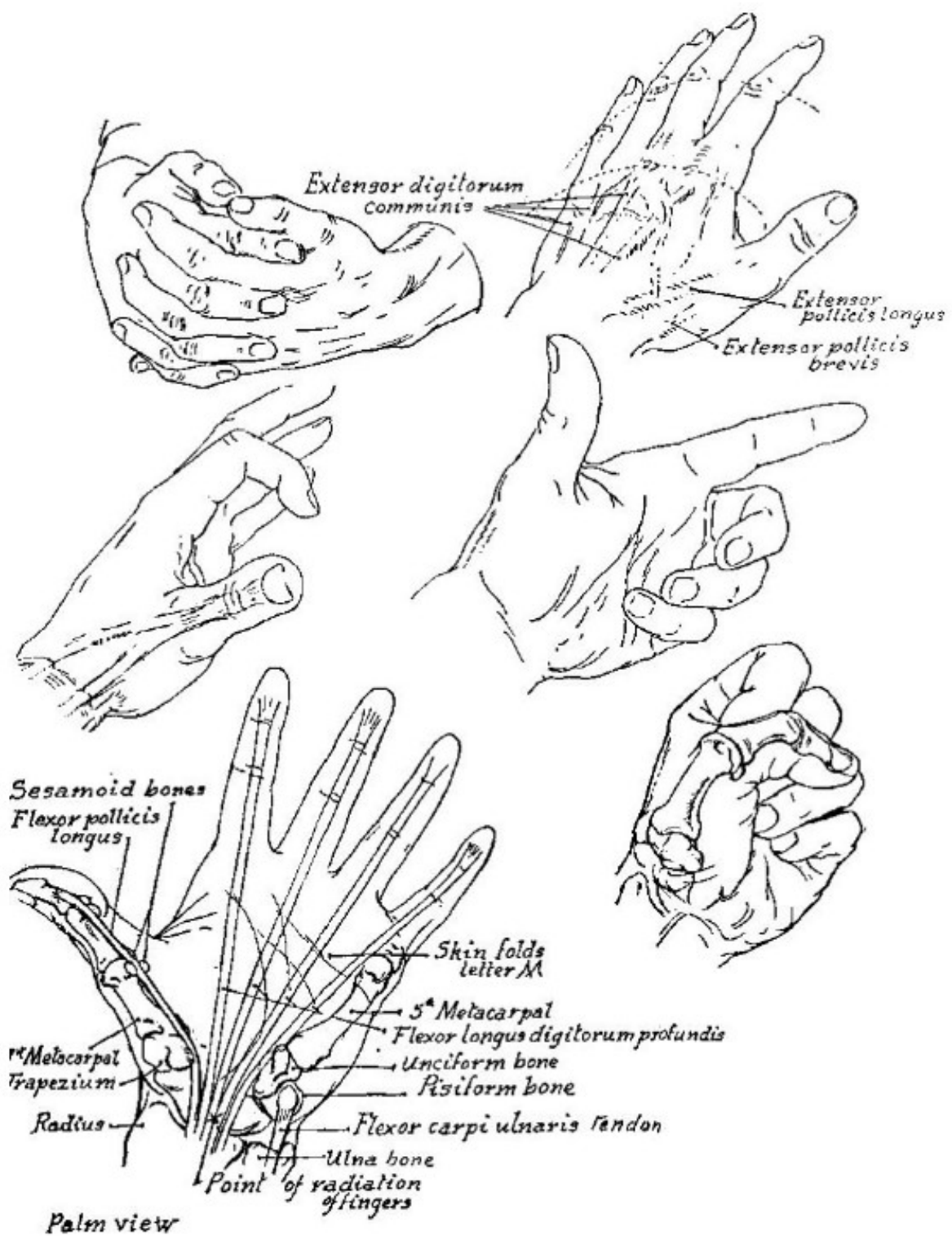
*Dicta Perma*

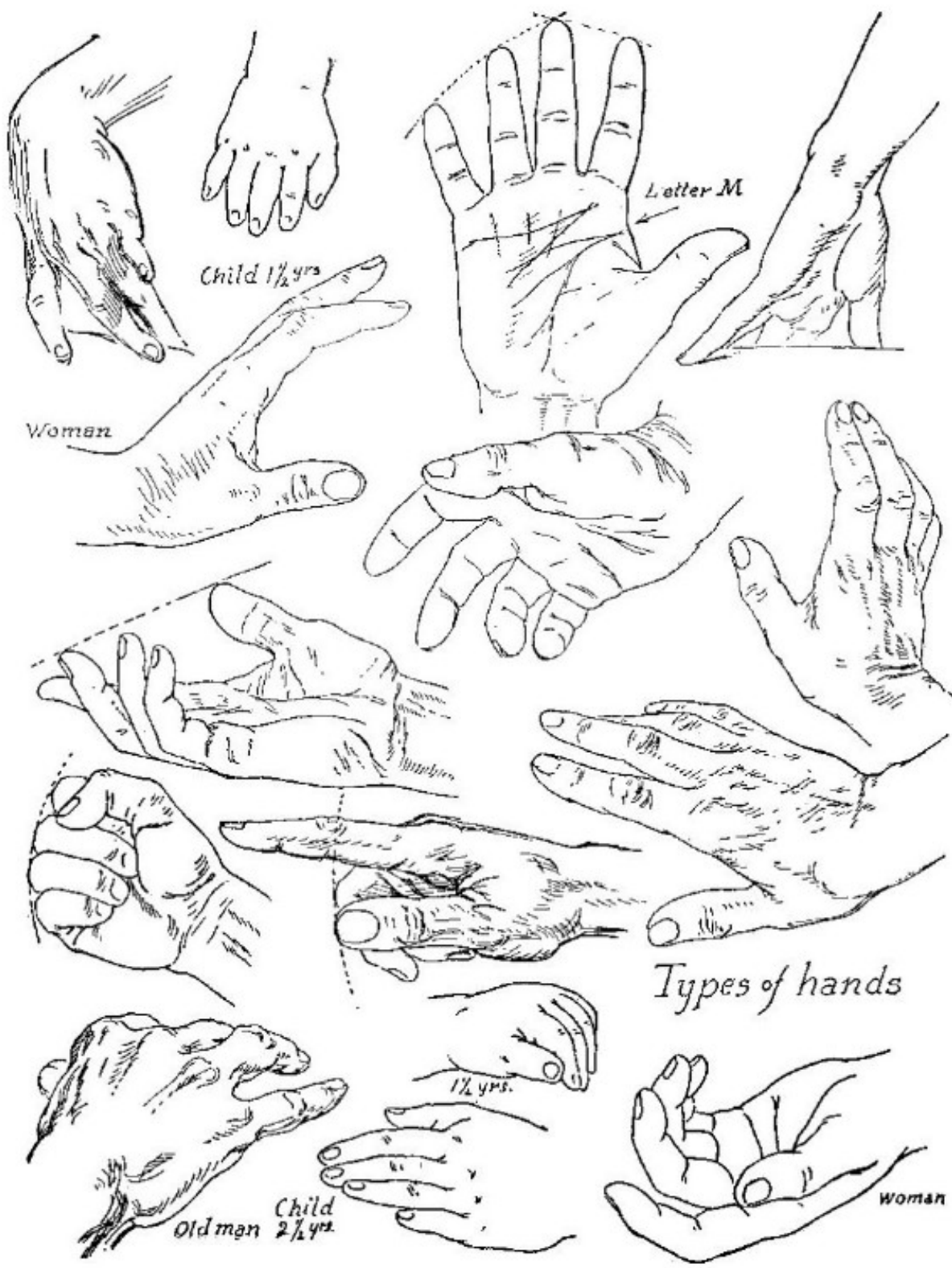




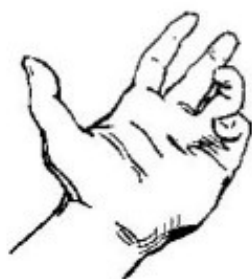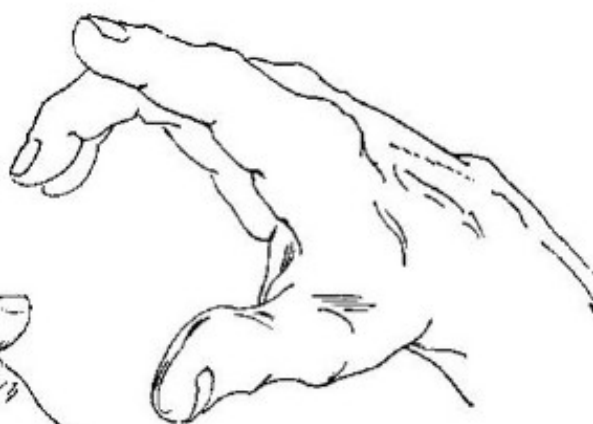

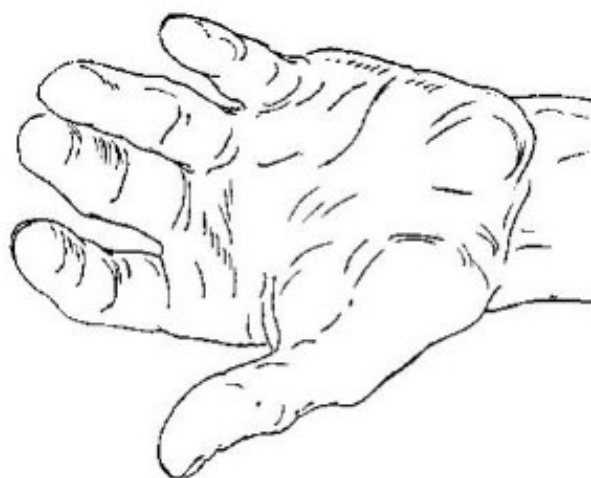
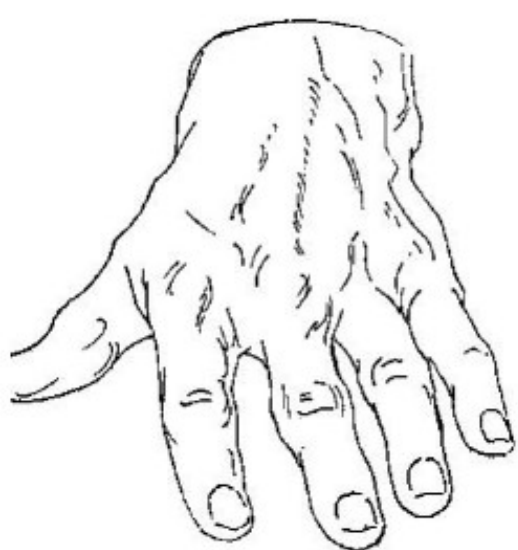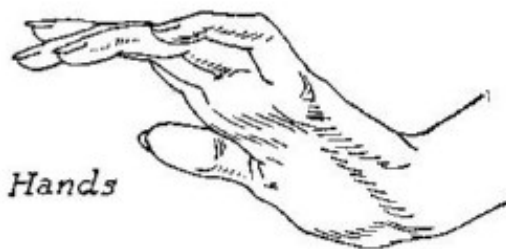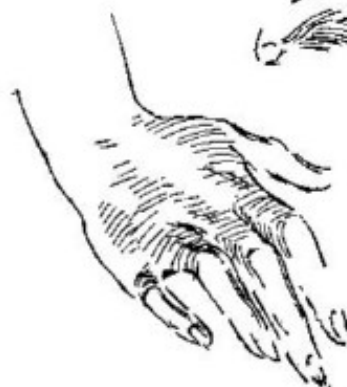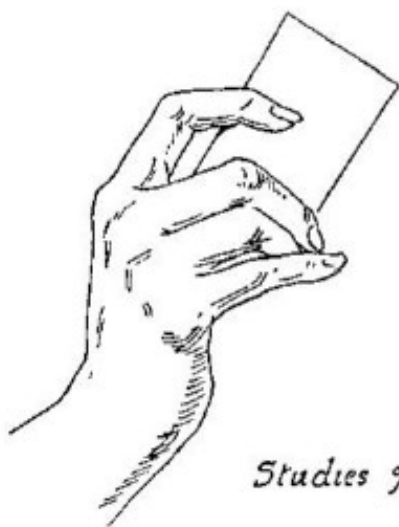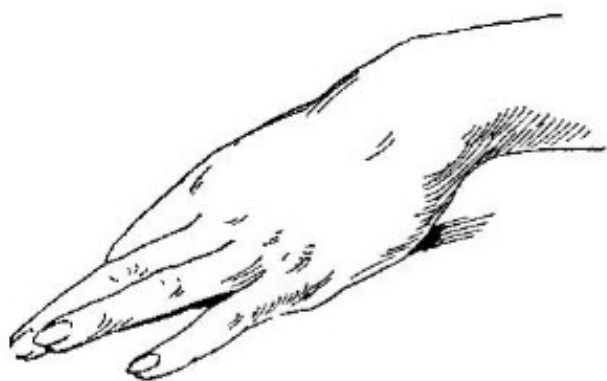
*Studies of hands with use of imaginary lines  
for proportion*






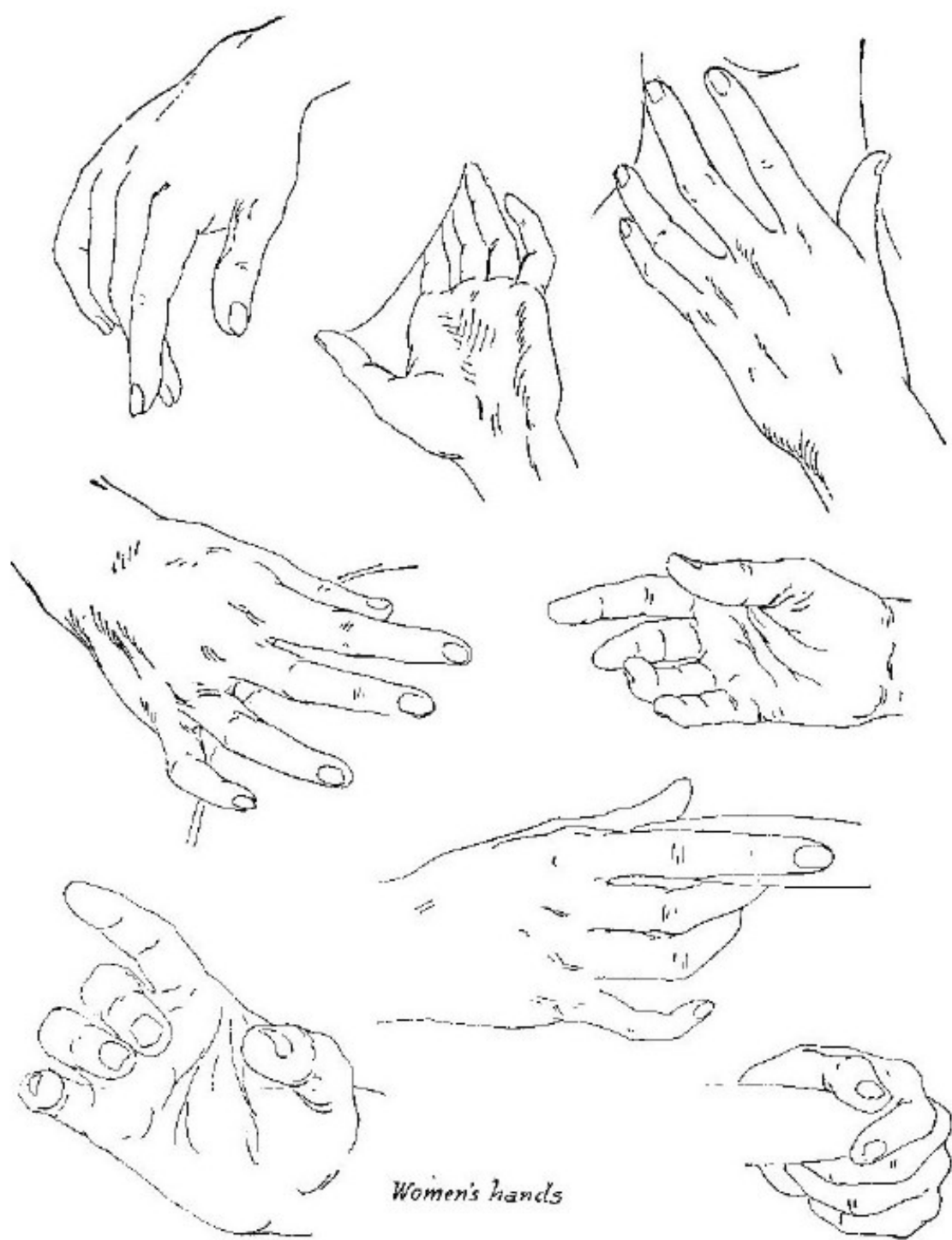






*Studies of Women's Hands*

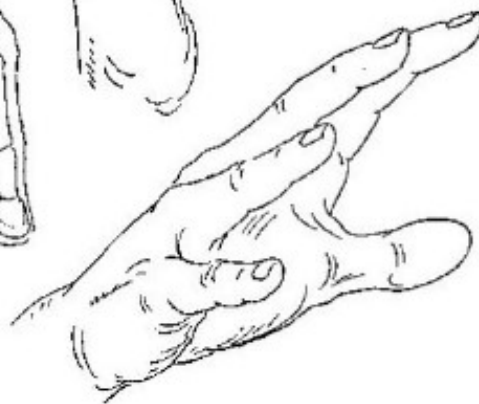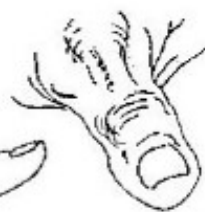
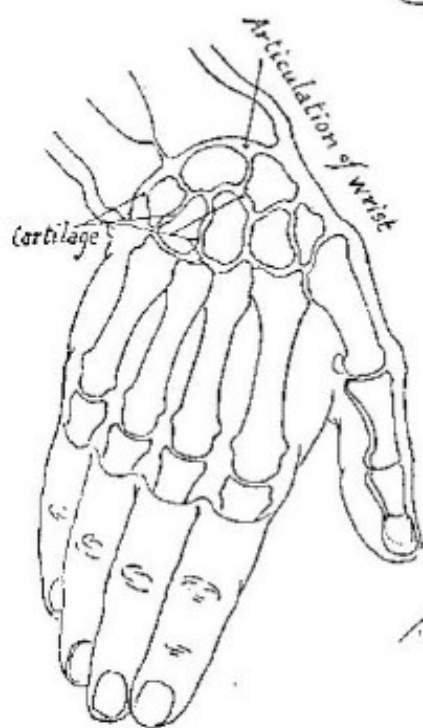
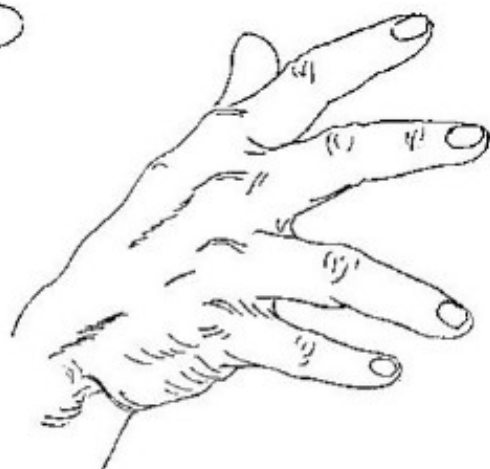
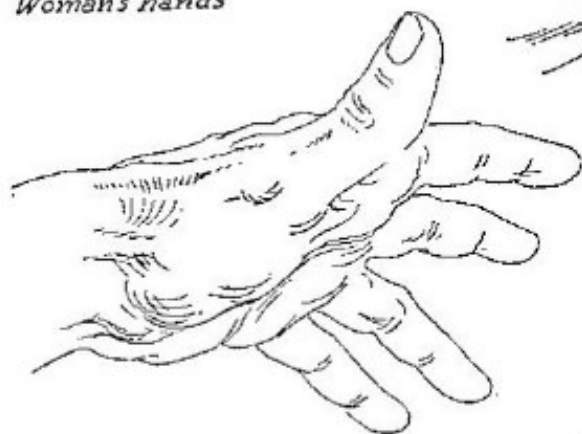




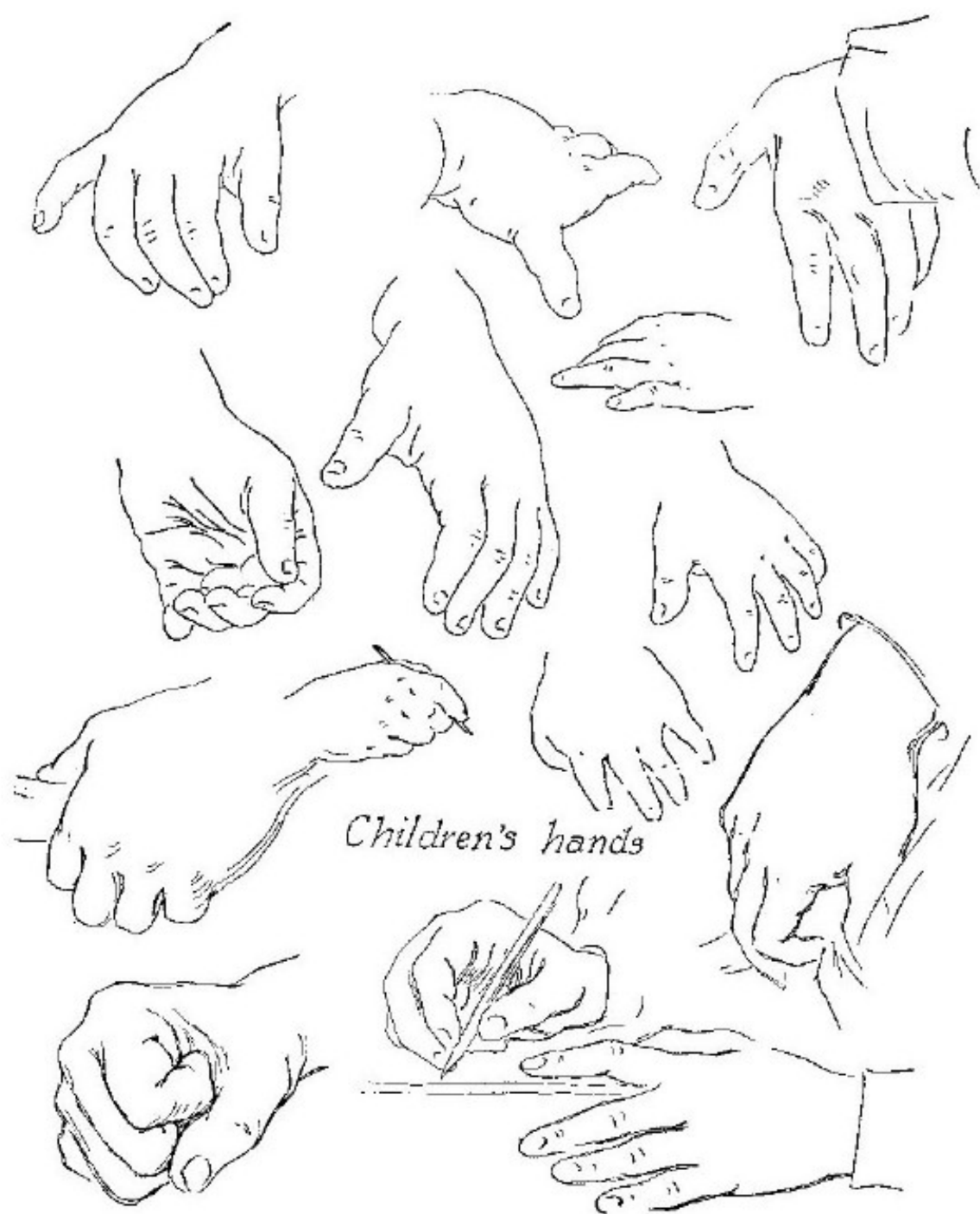*Women's hands*

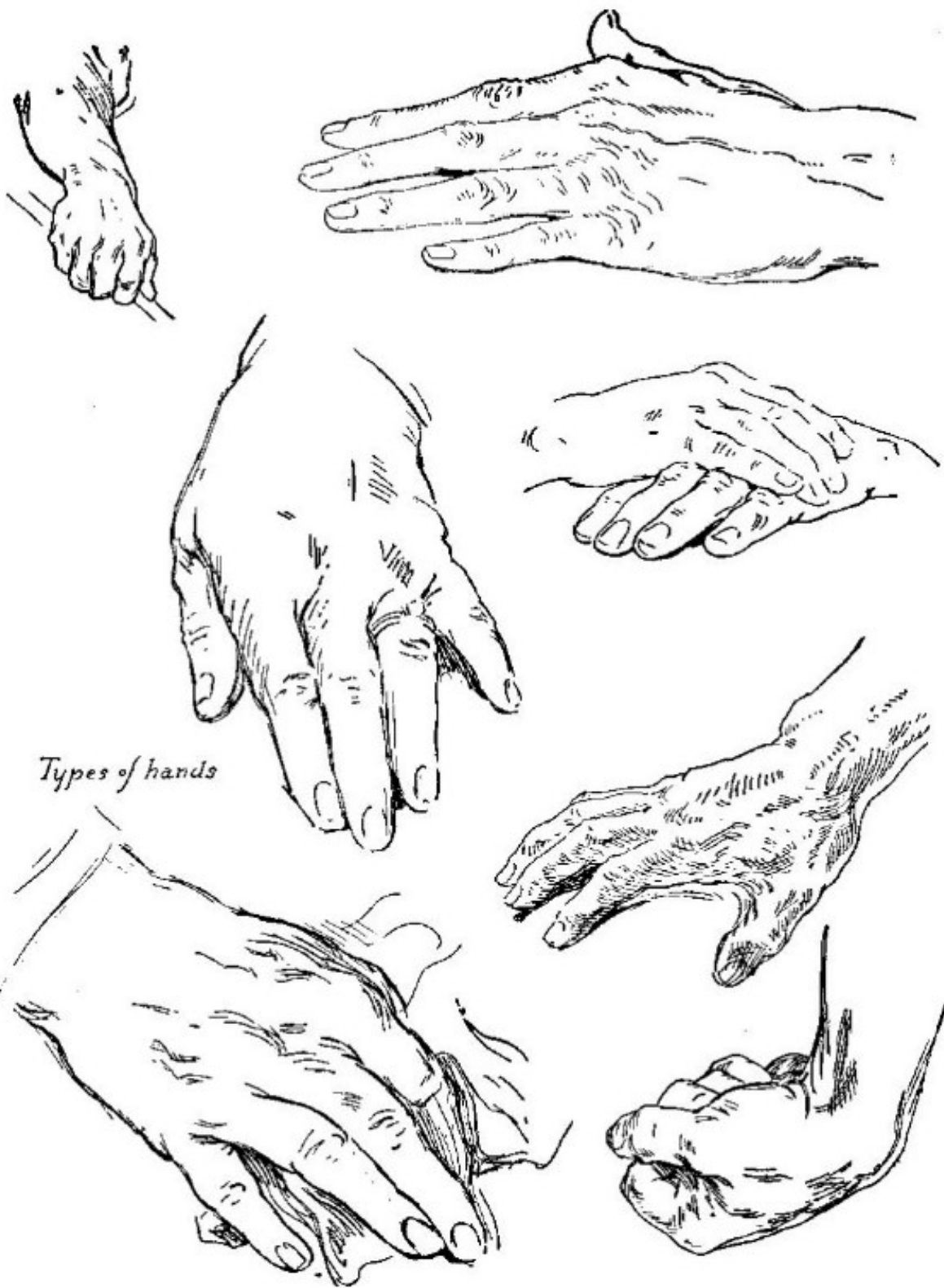

*Woman's hands*

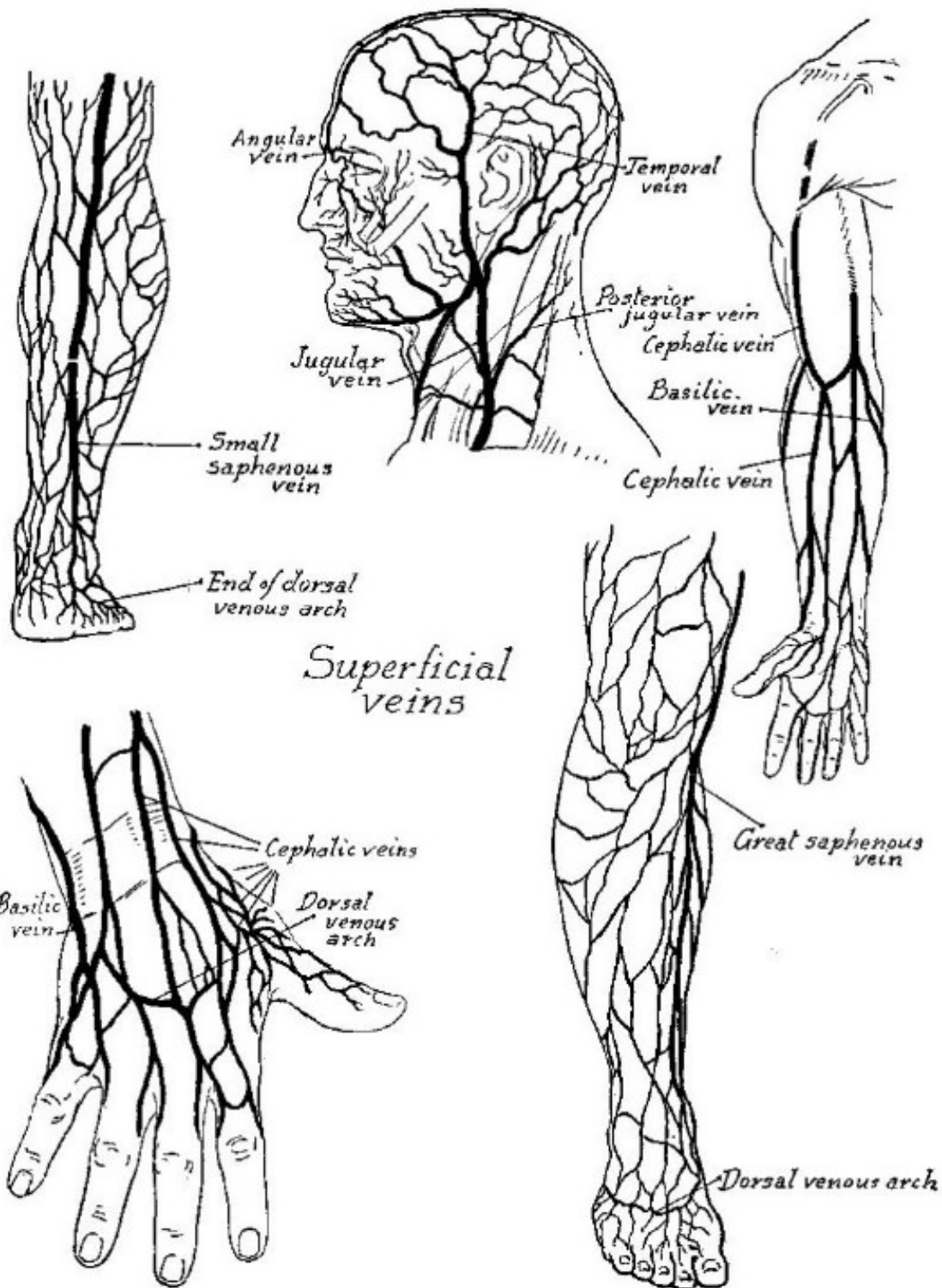


*Men's hands*





*Types of hands*

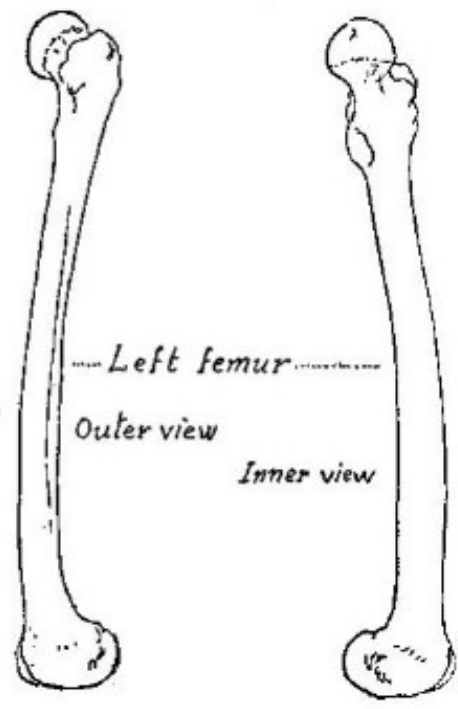
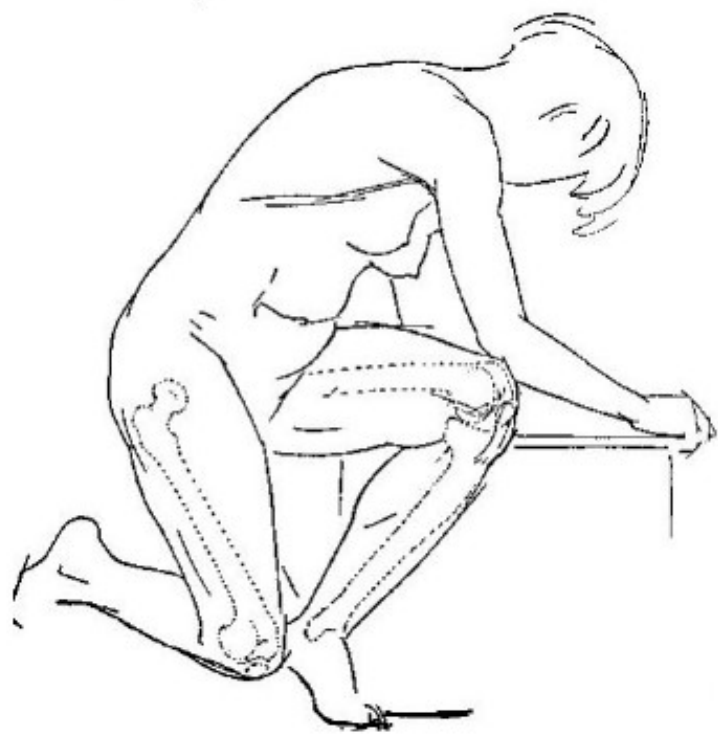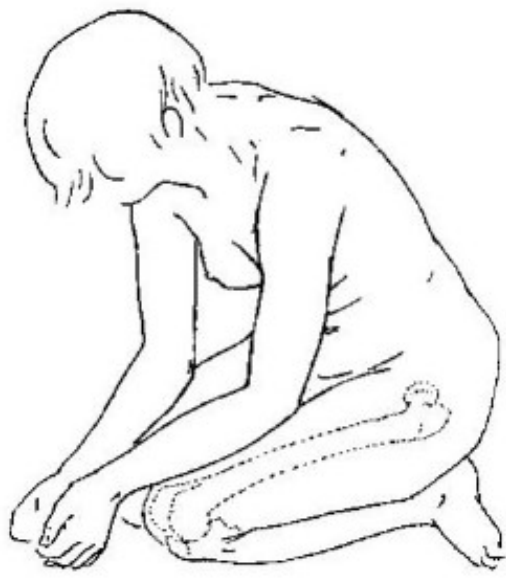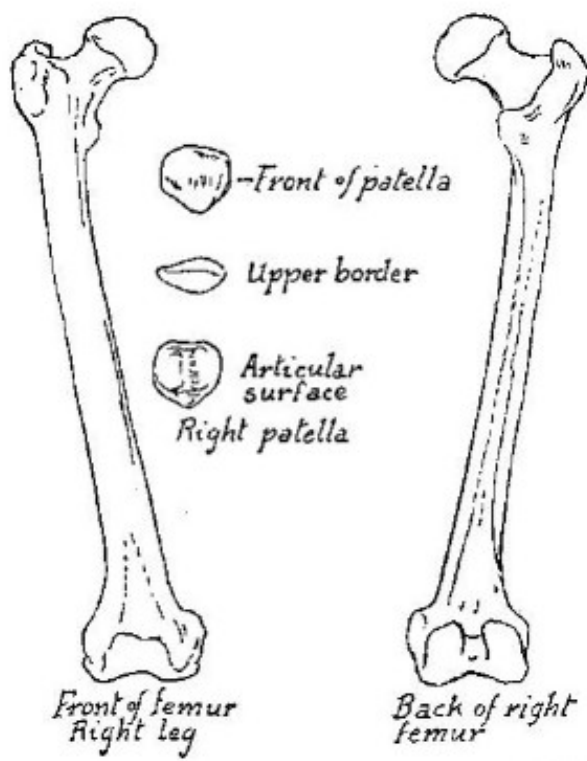


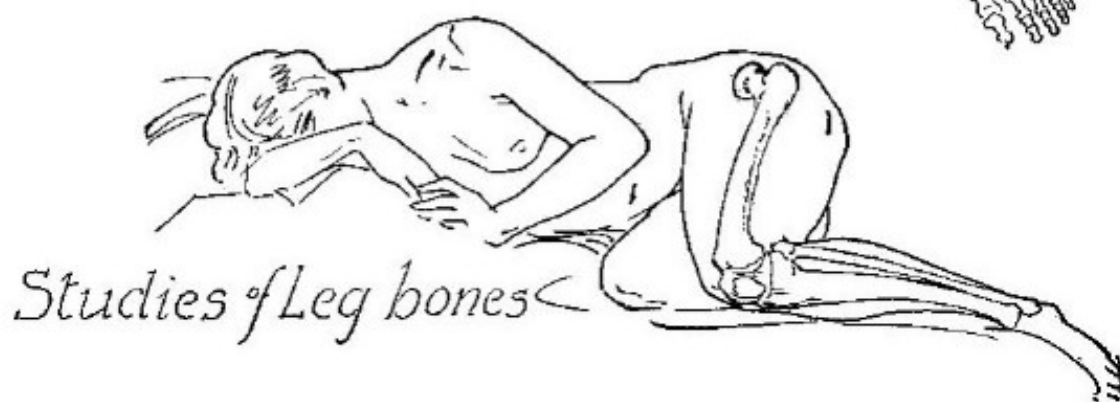
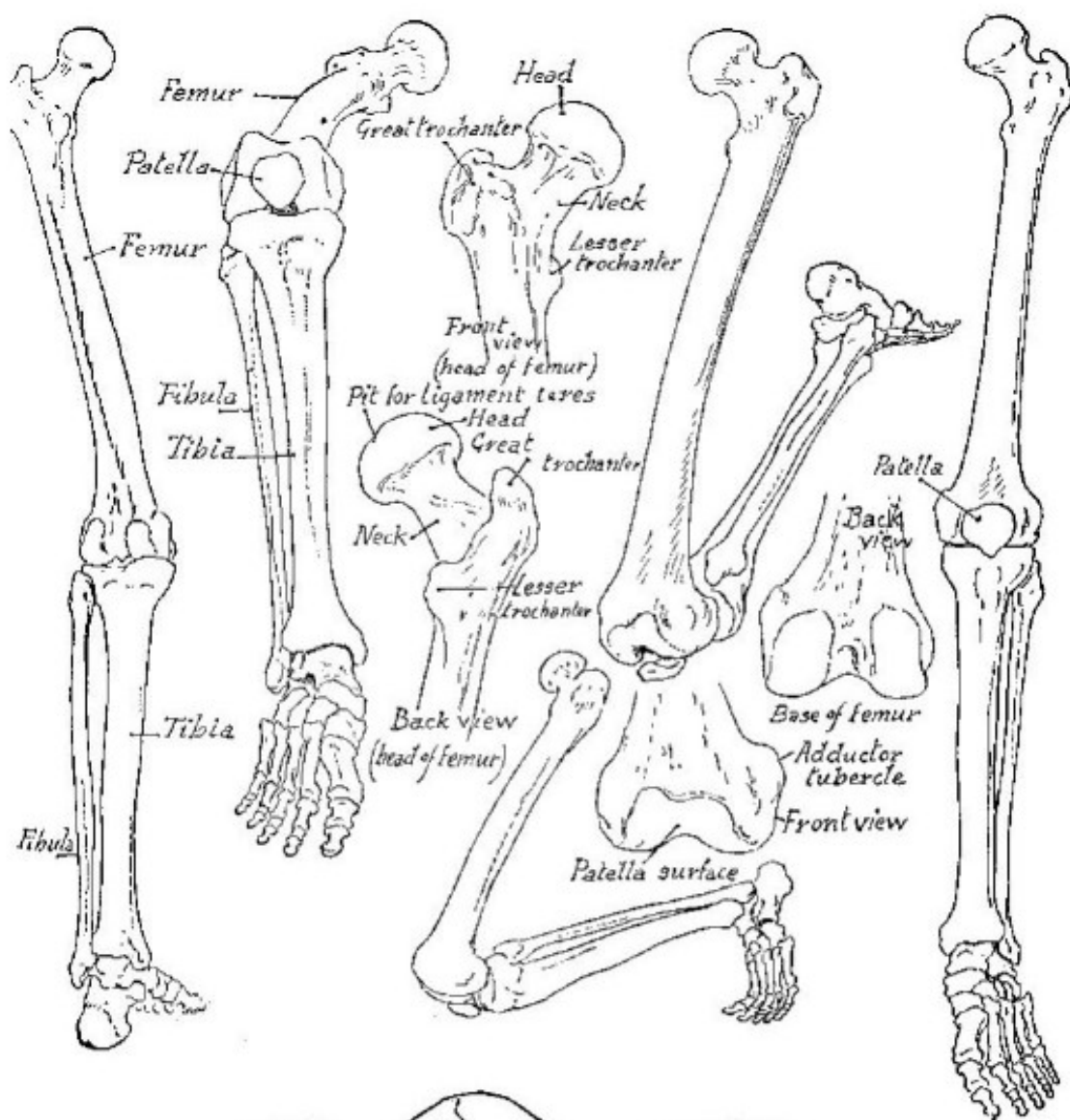


Part VII

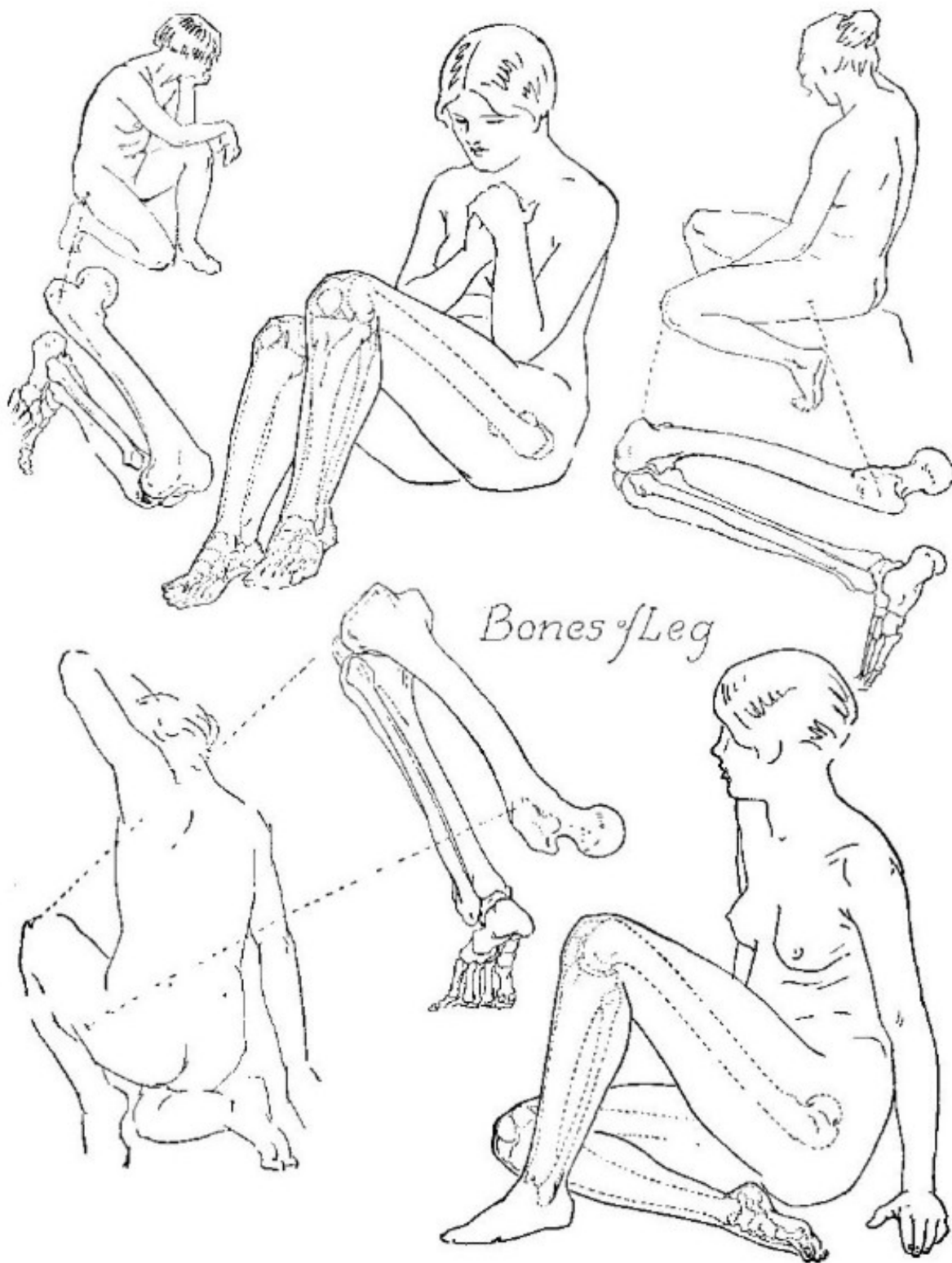
*The Leg*



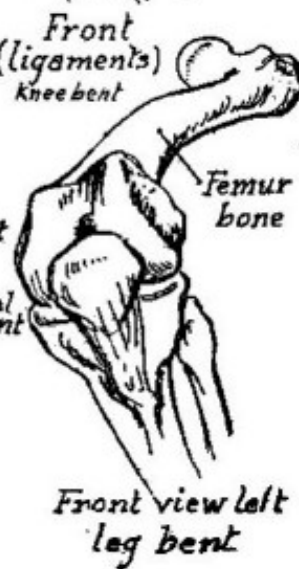
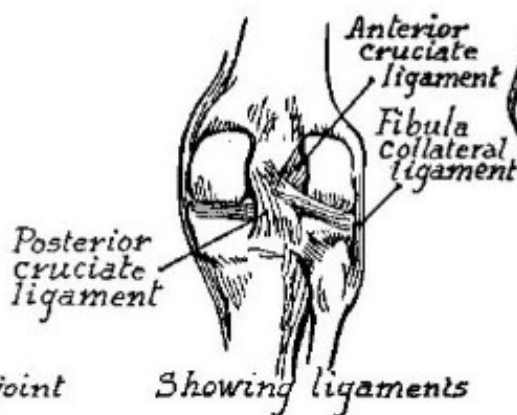
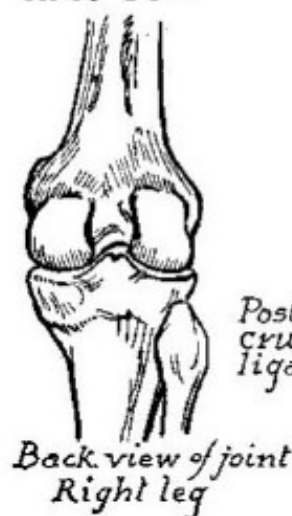
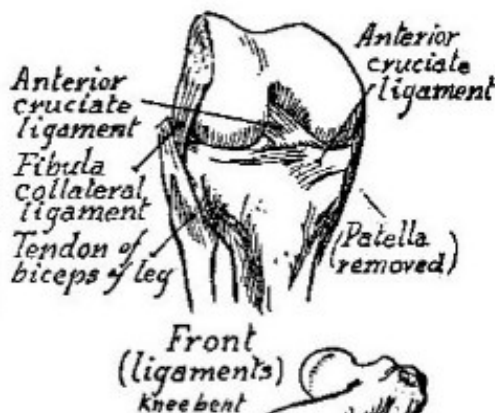
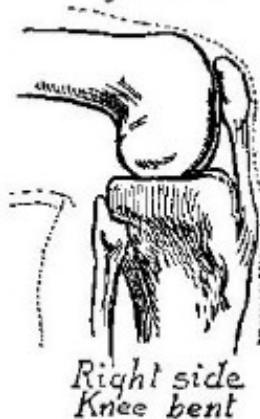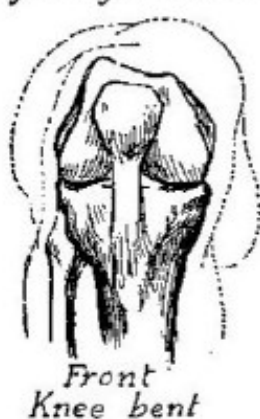
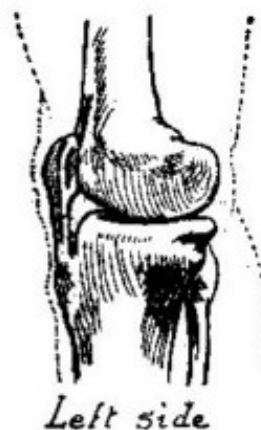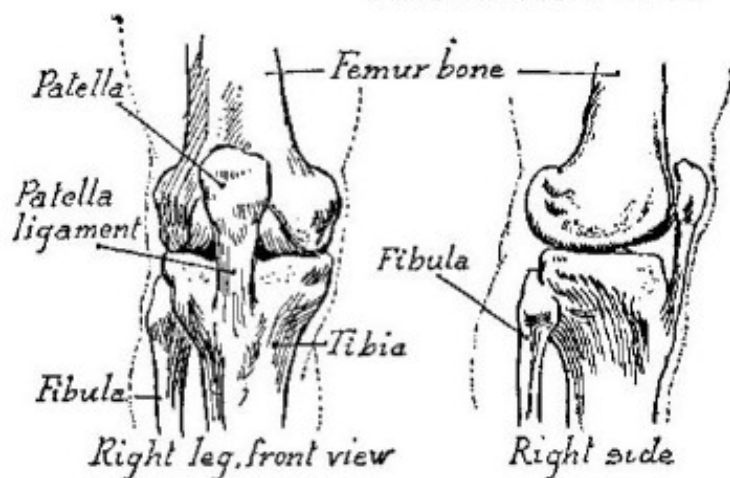


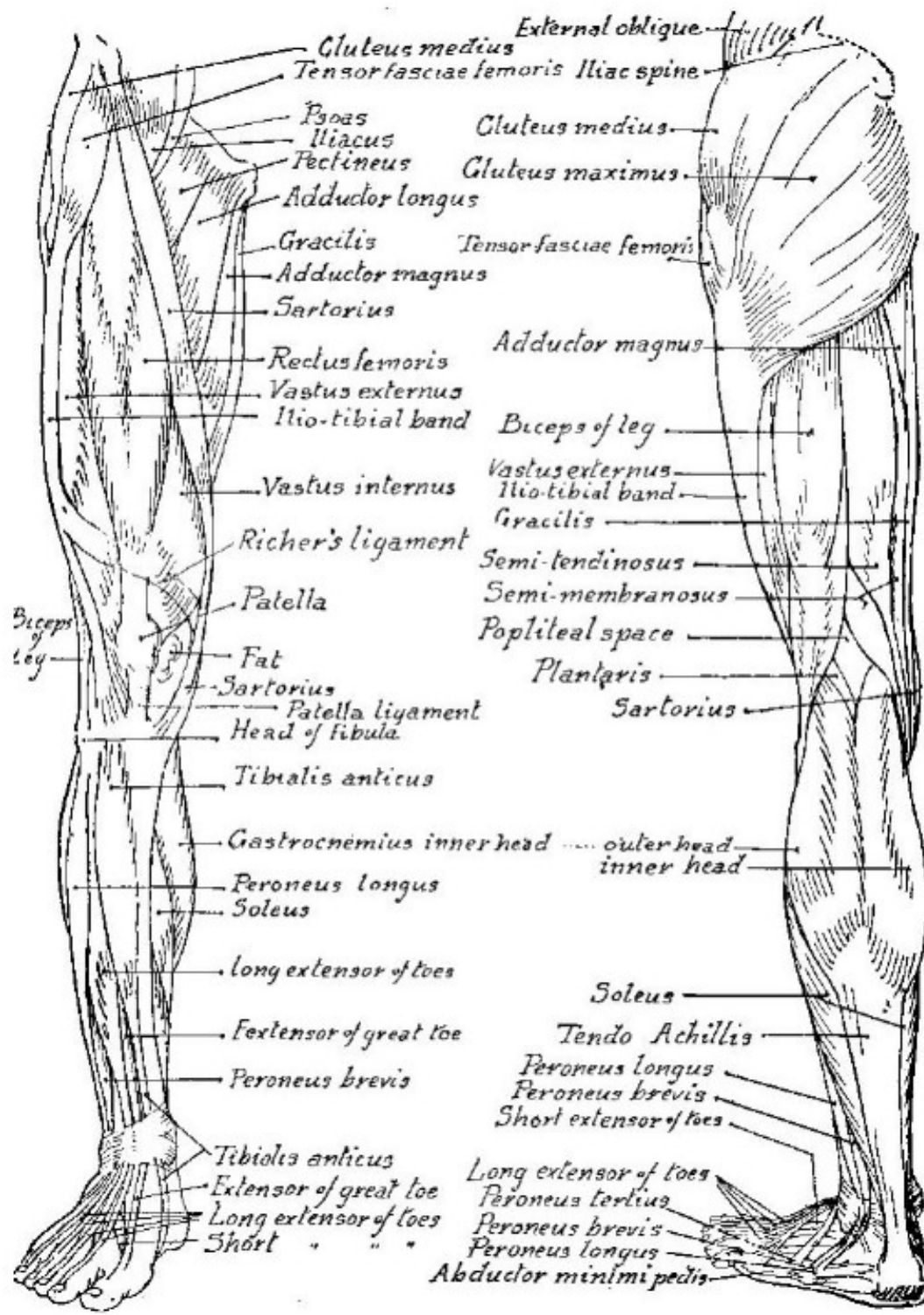


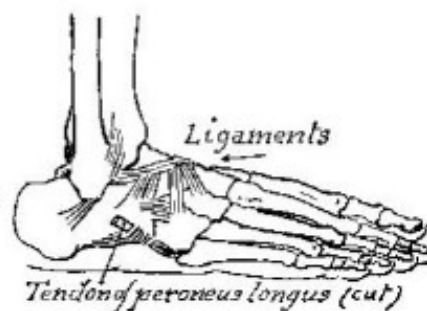
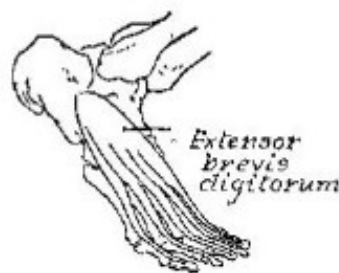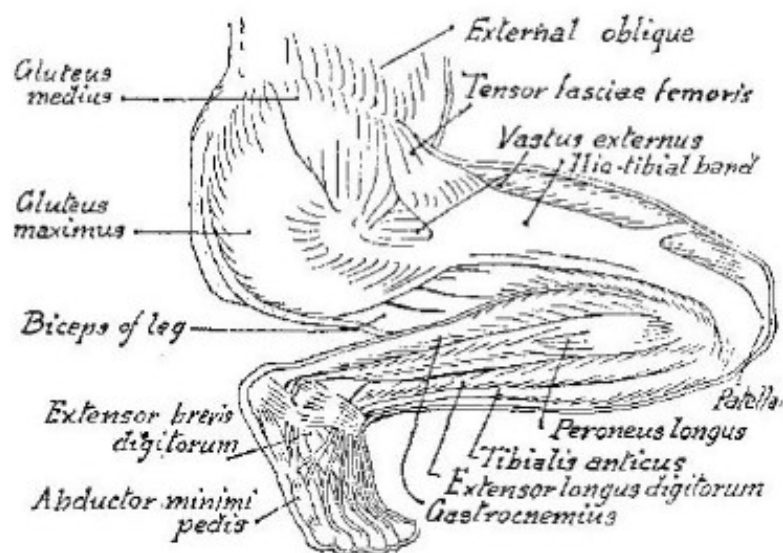
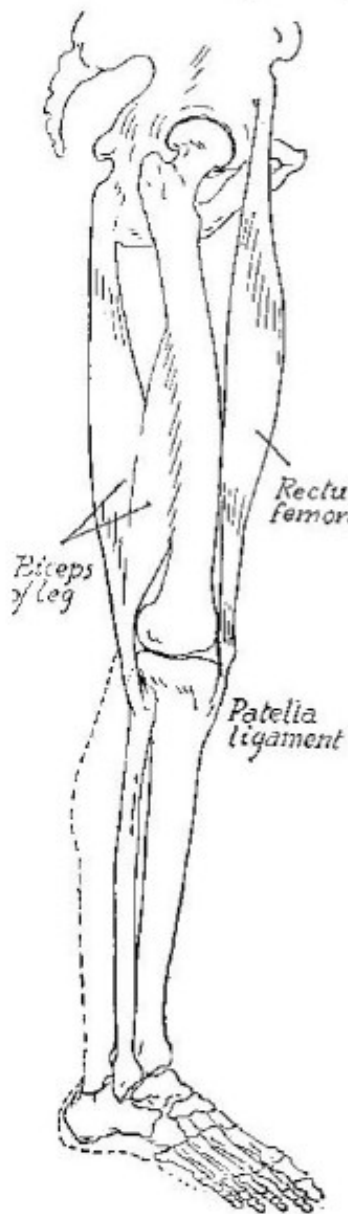
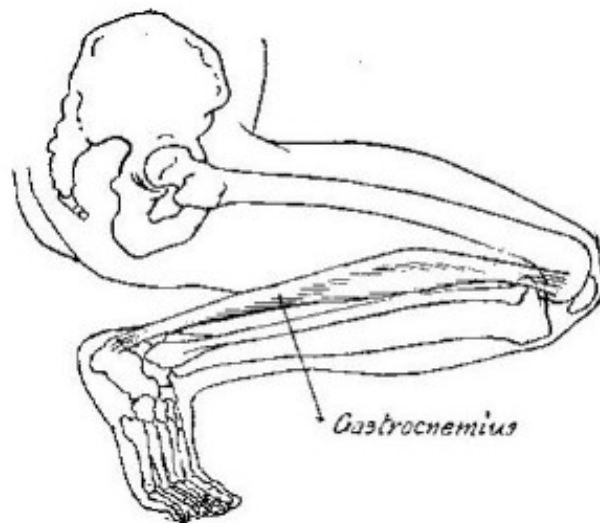
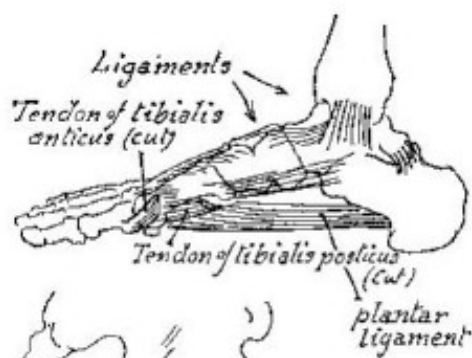
*Studies of Leg bones*

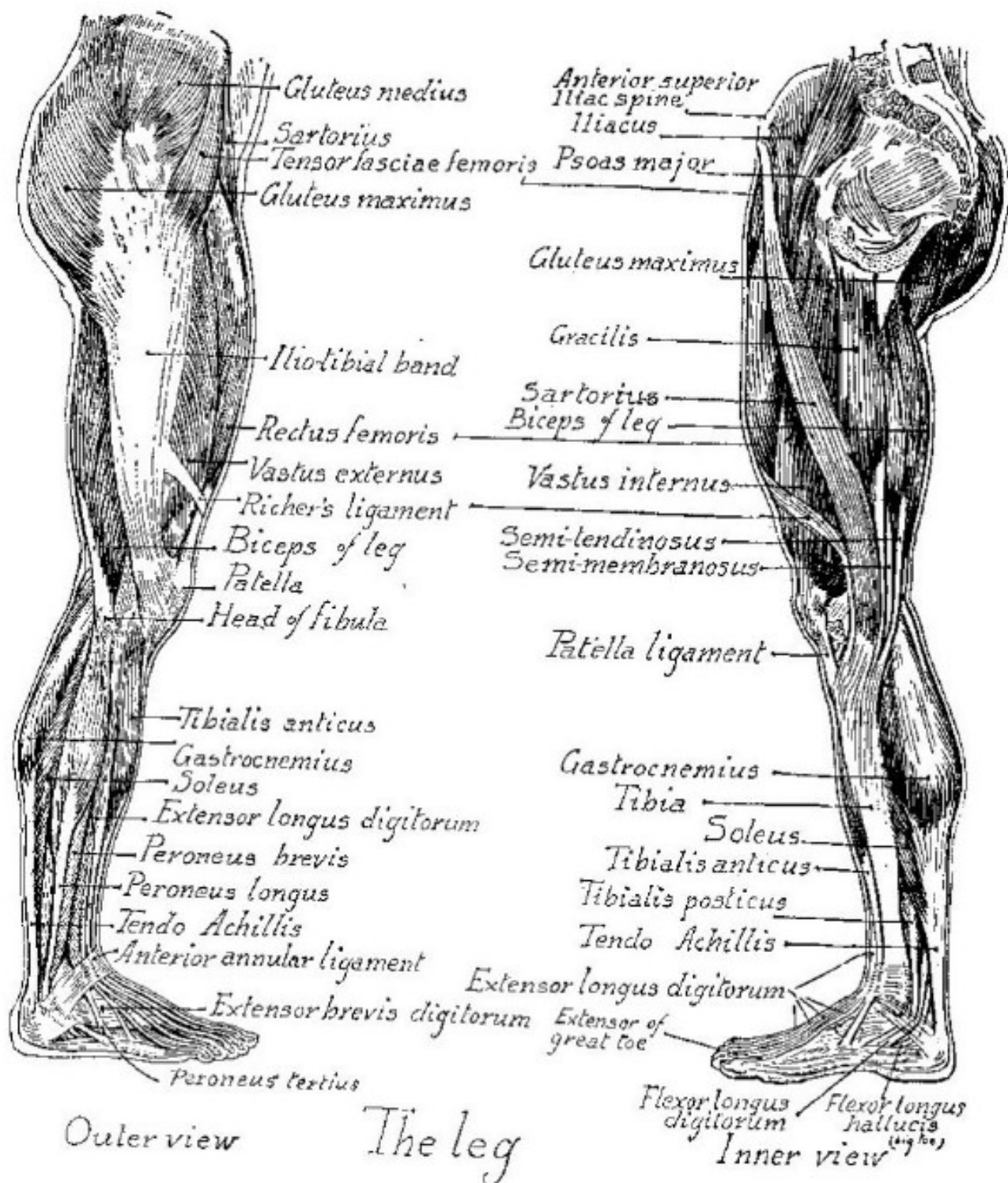


# The Knee Joint

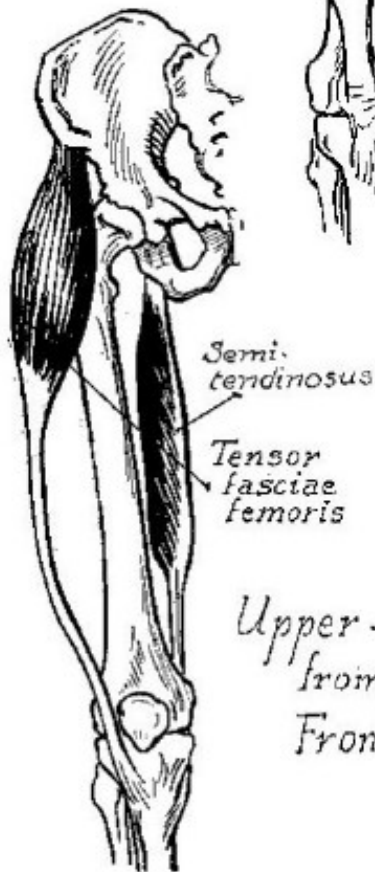
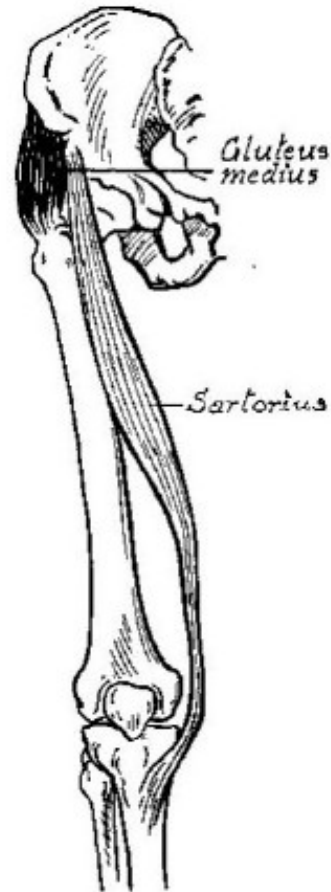
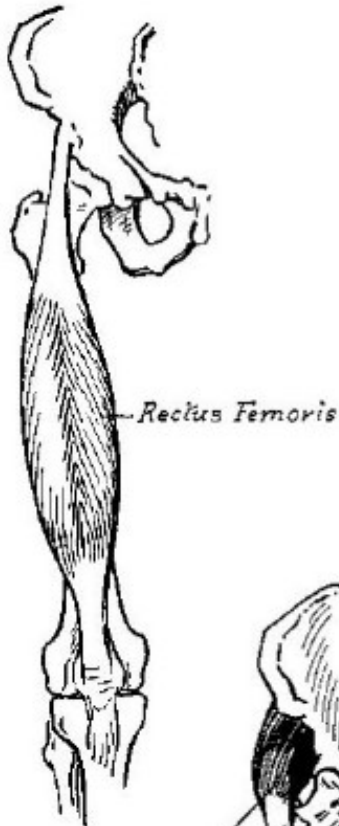
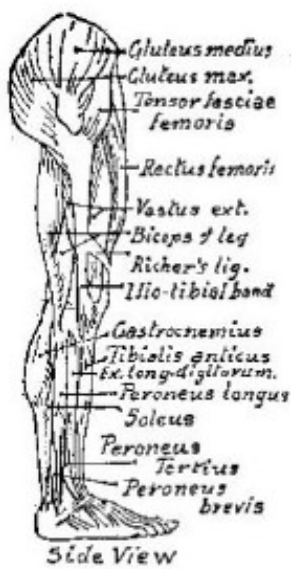



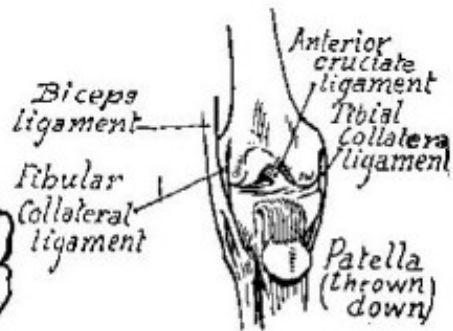
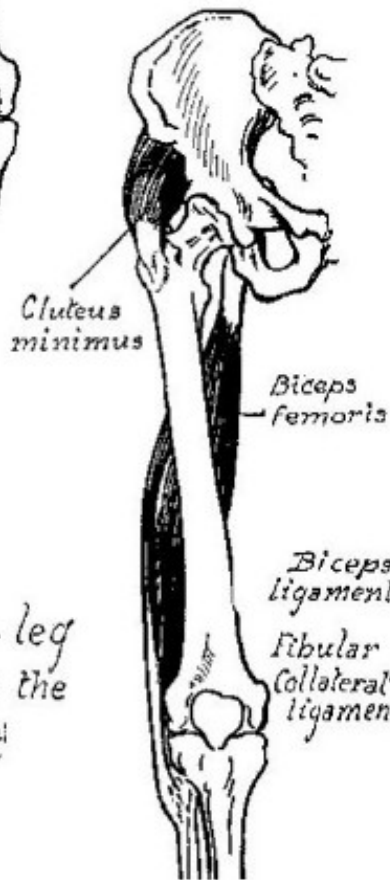




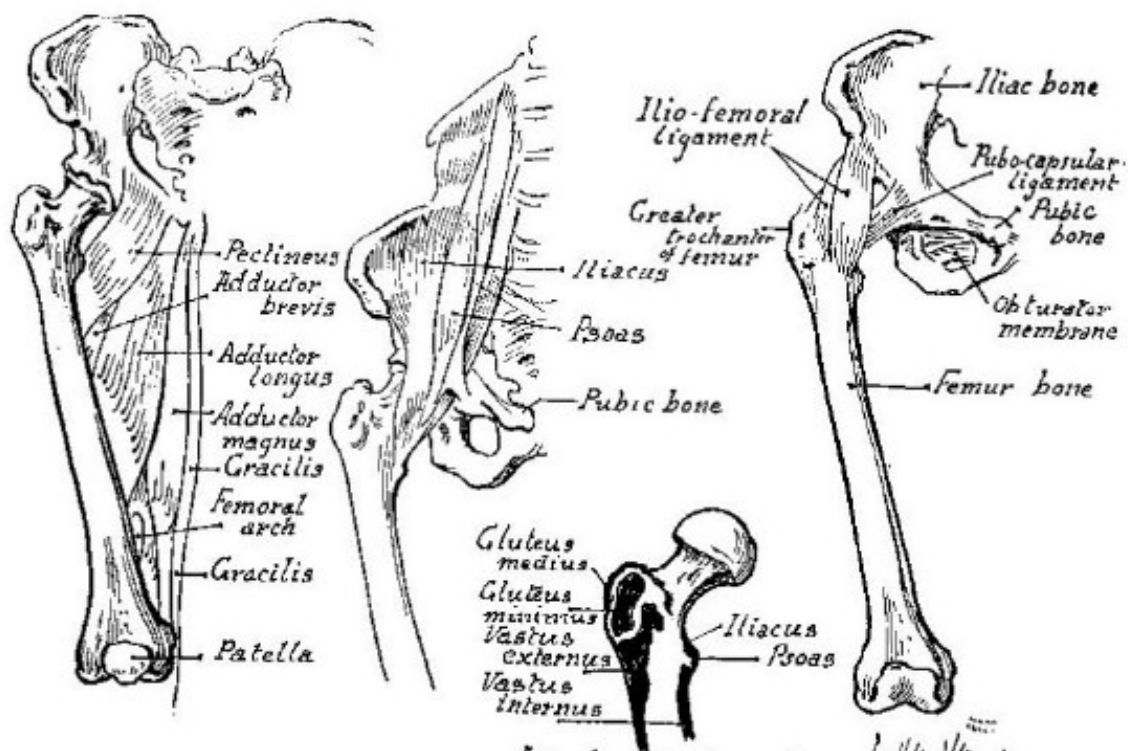




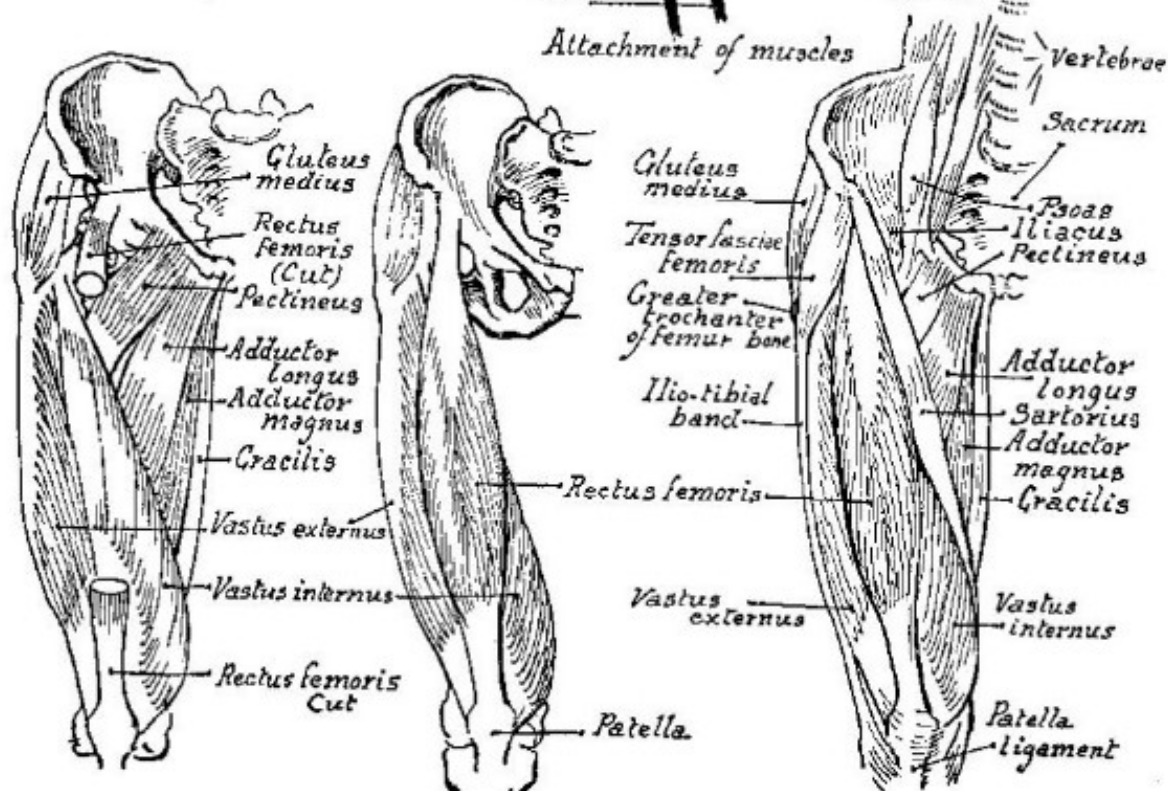
Upper - leg  
from the  
Front

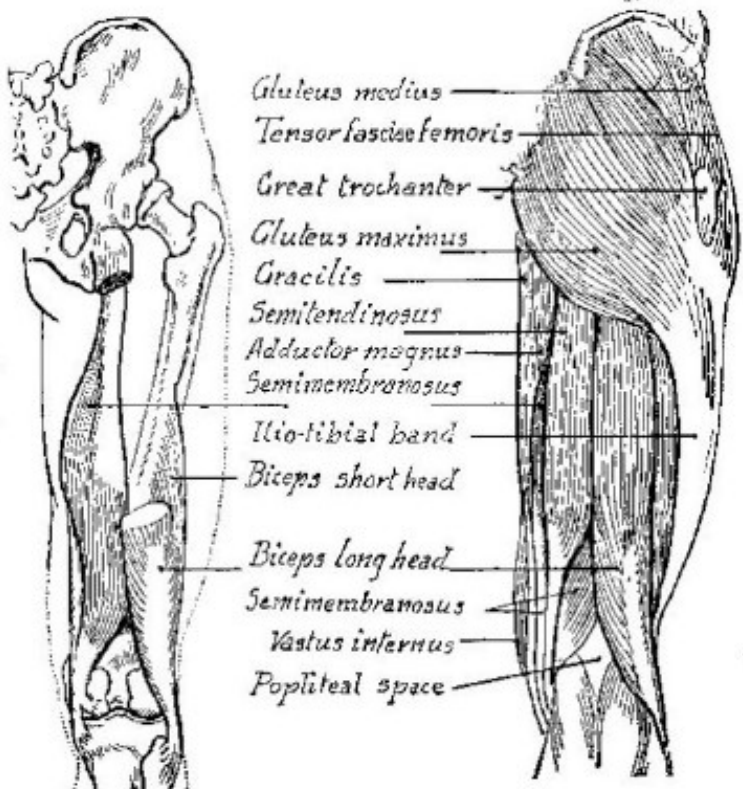
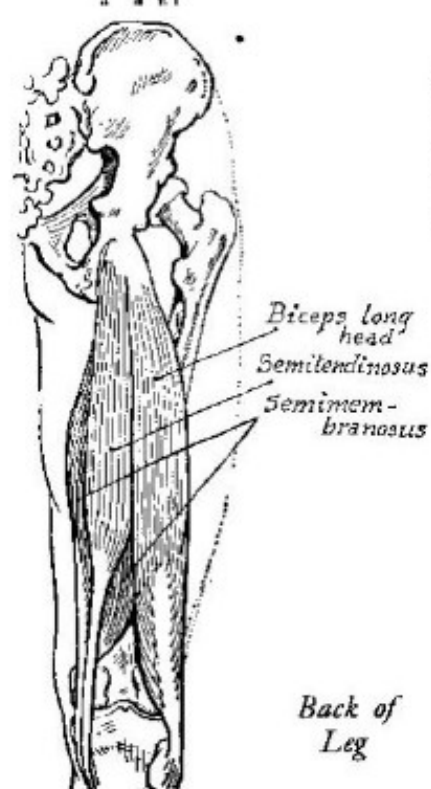
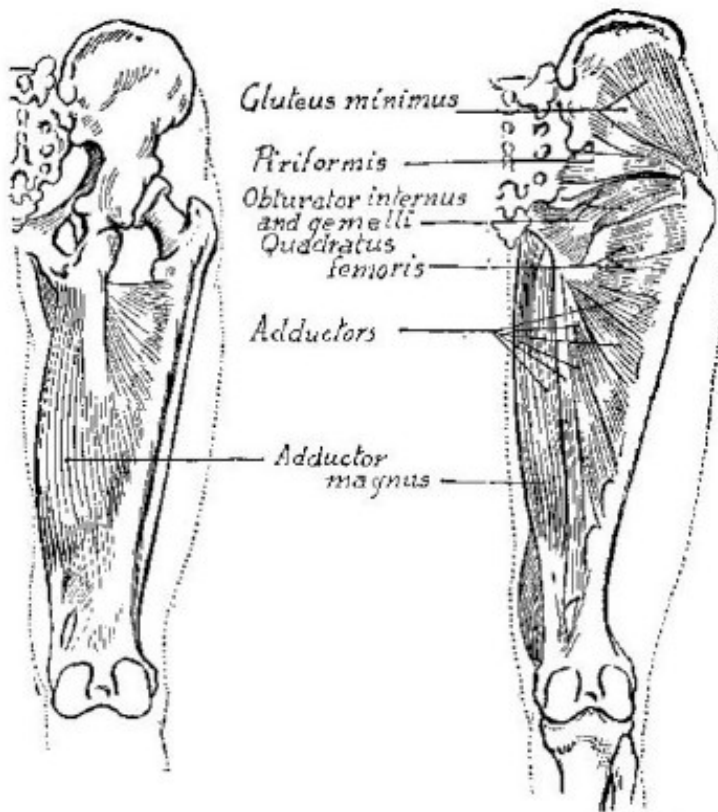
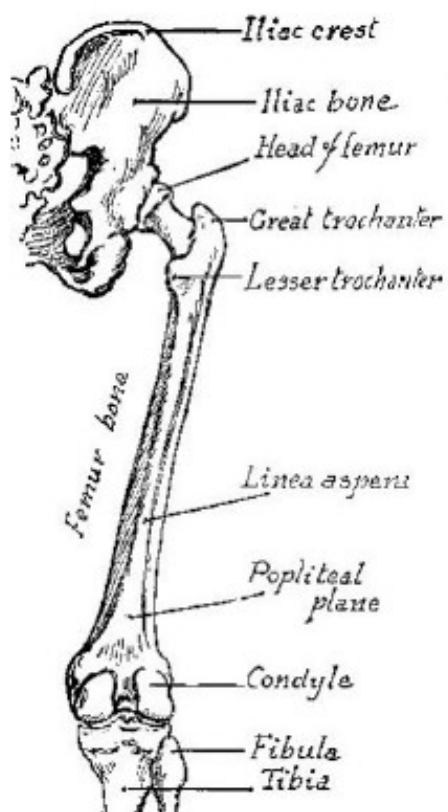


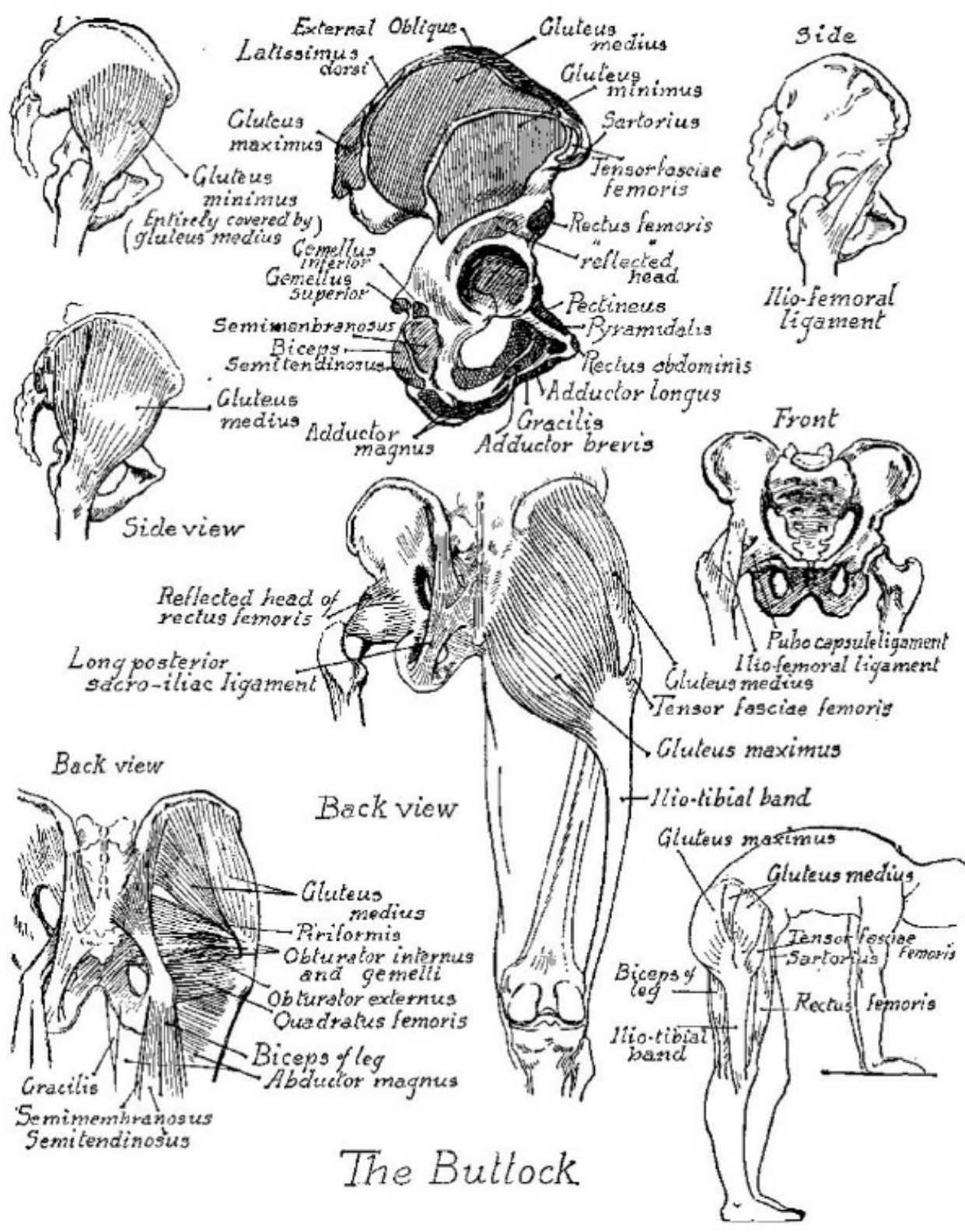




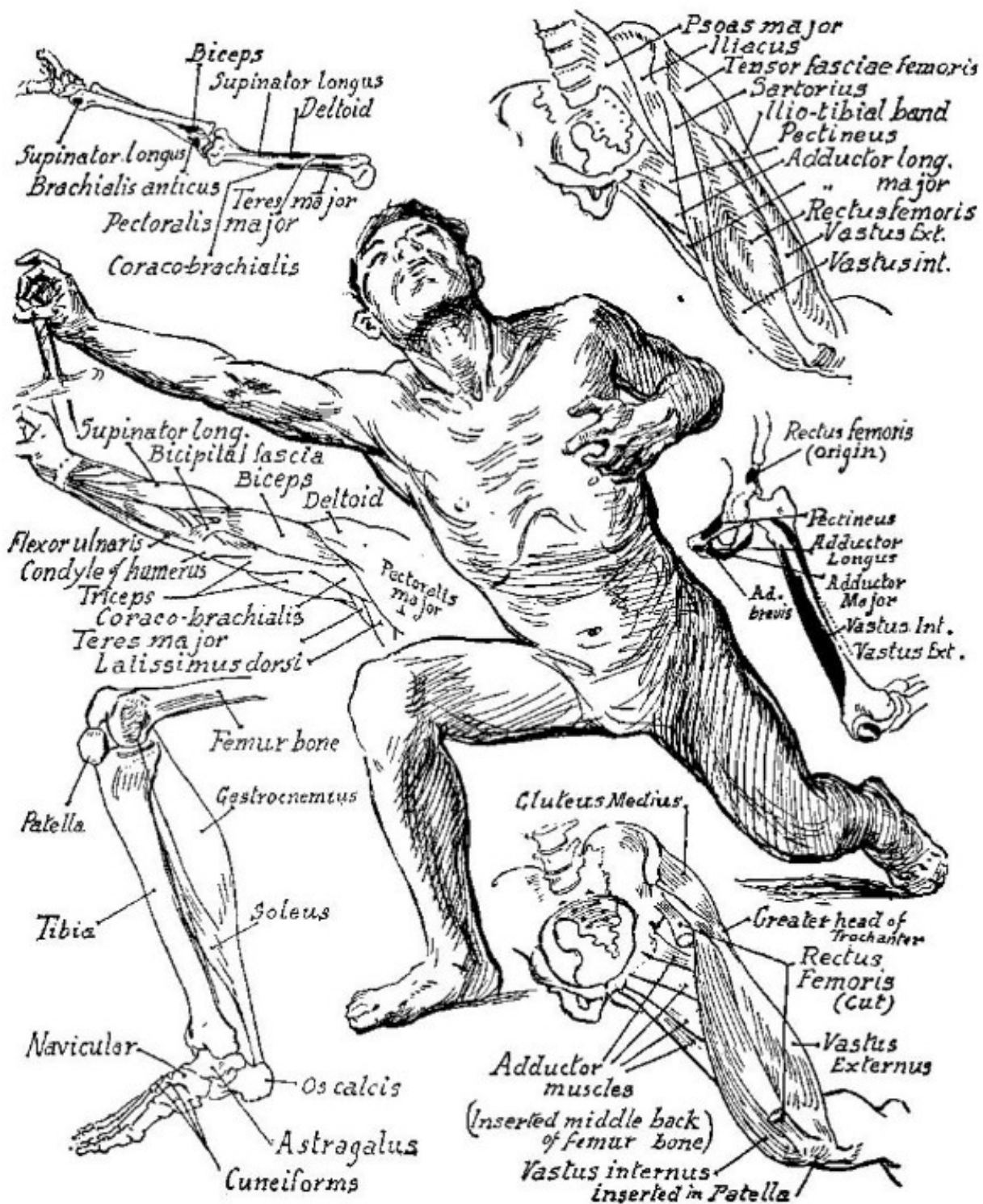#### Attachment of muscles

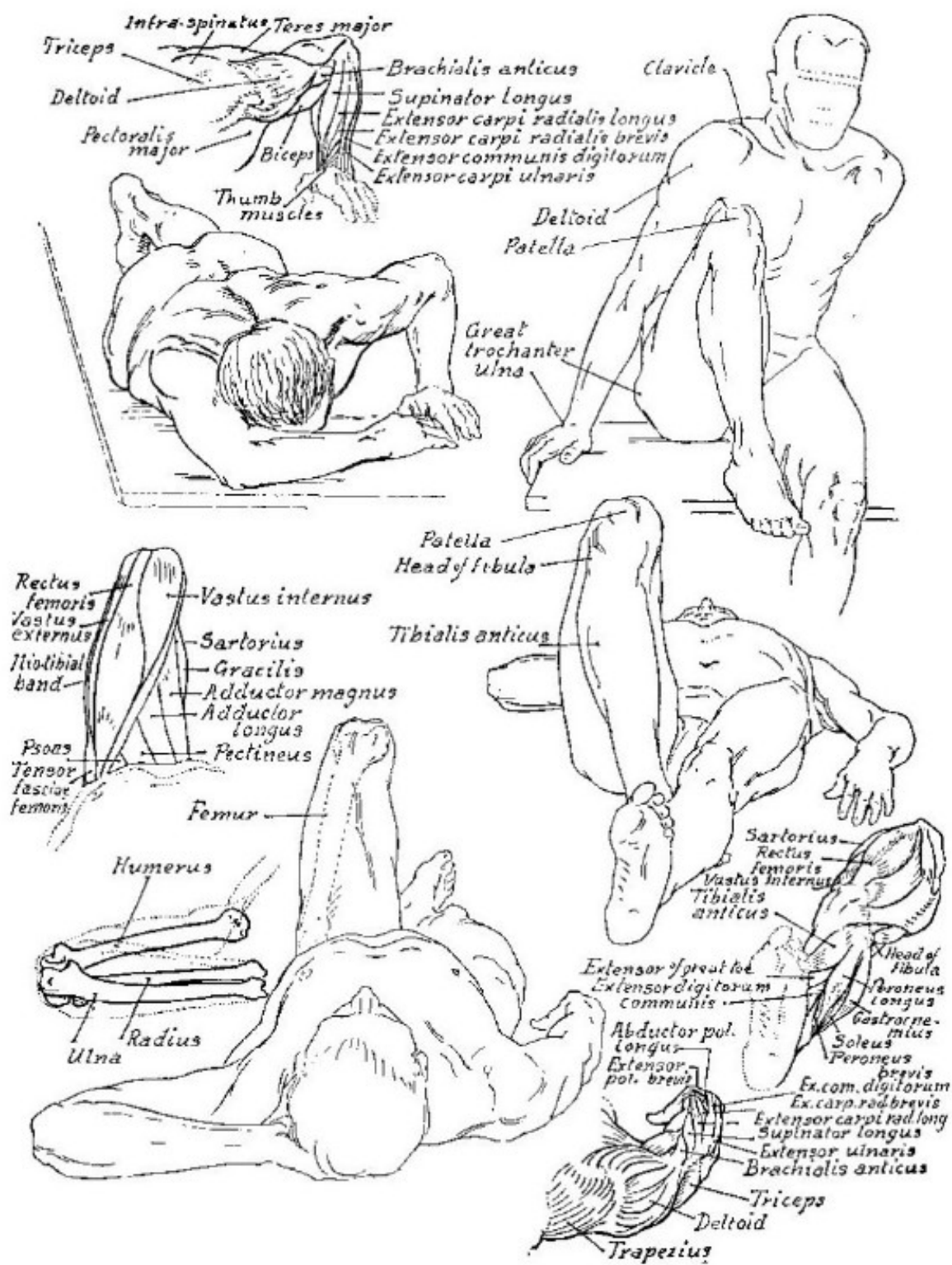




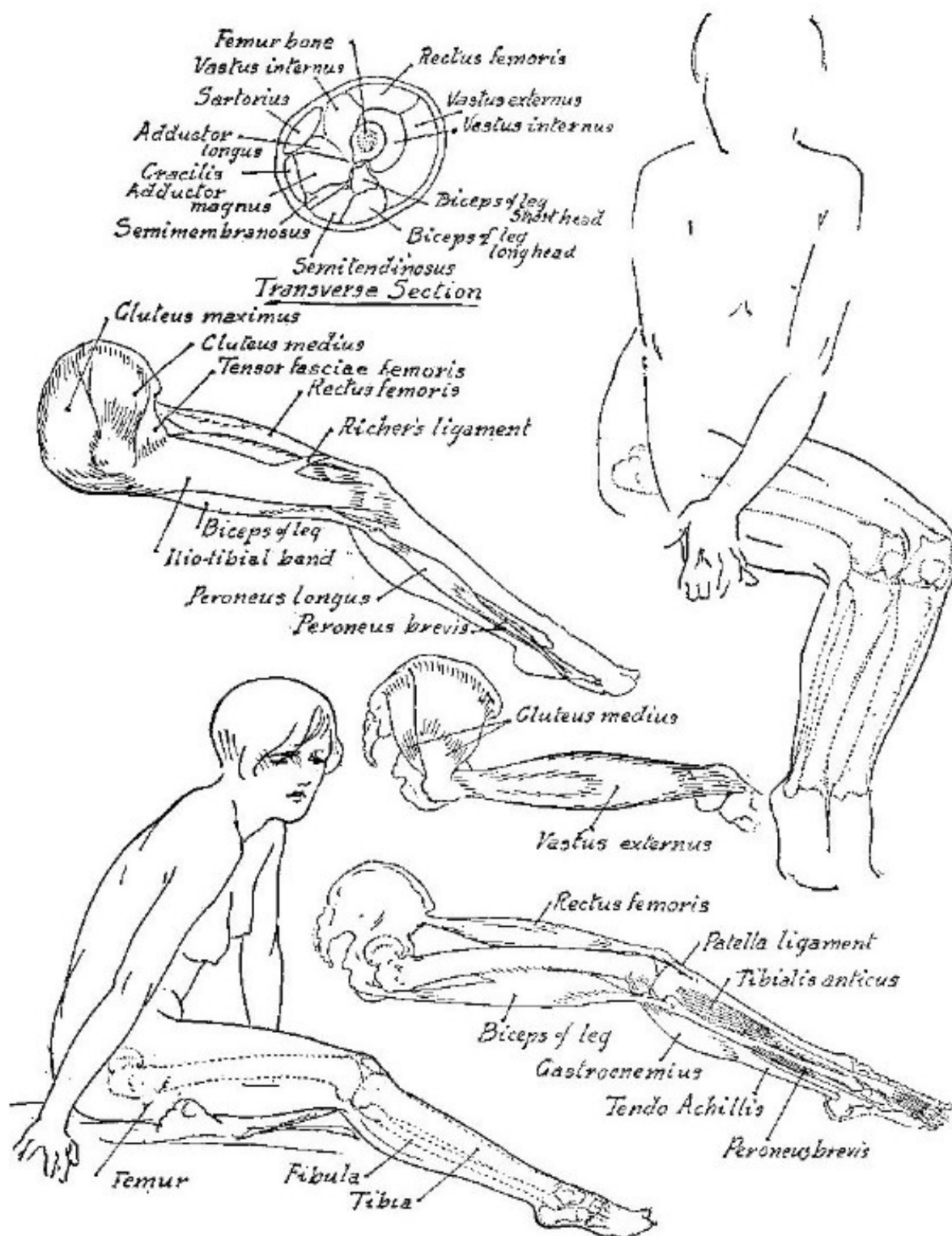


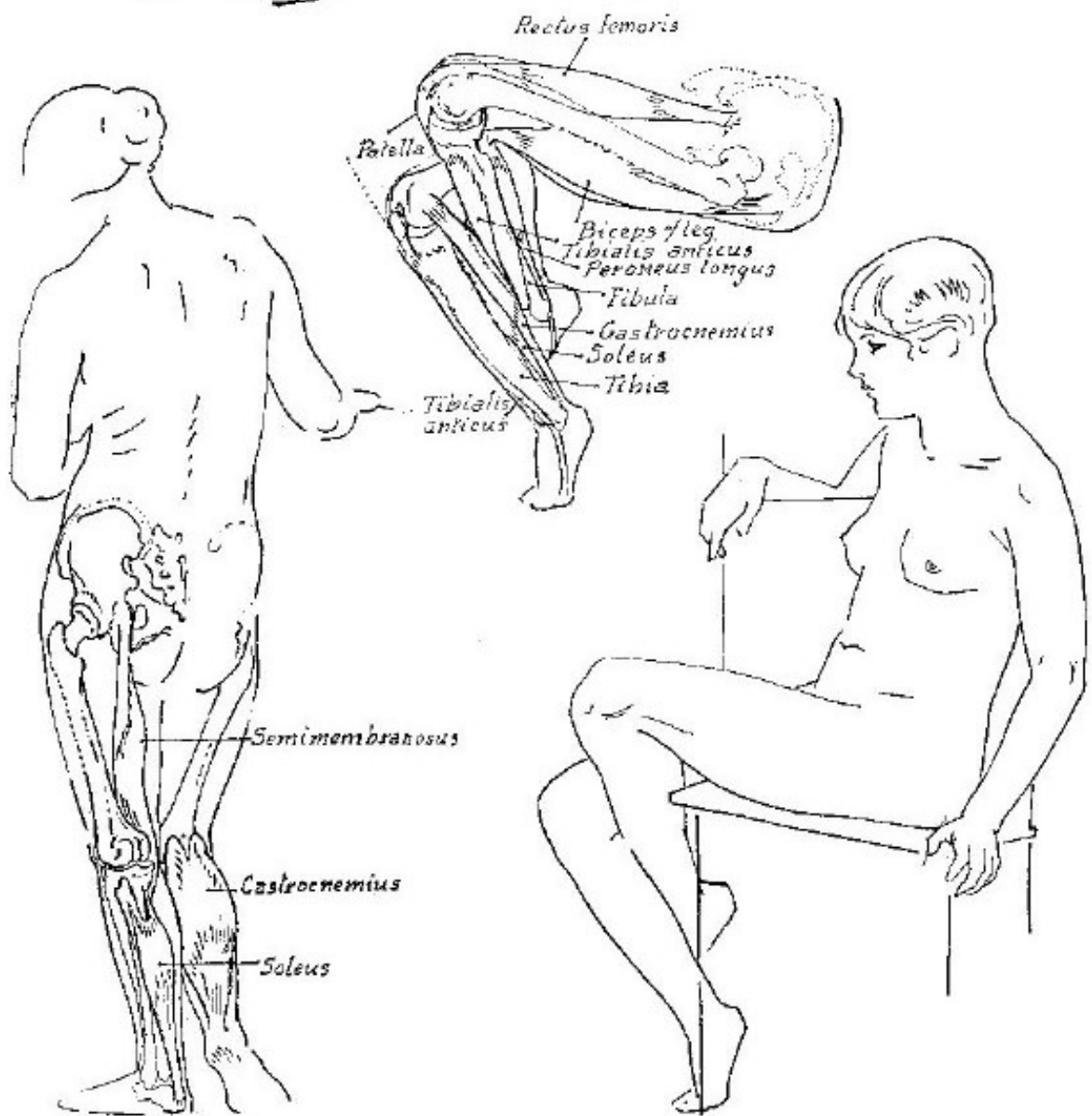
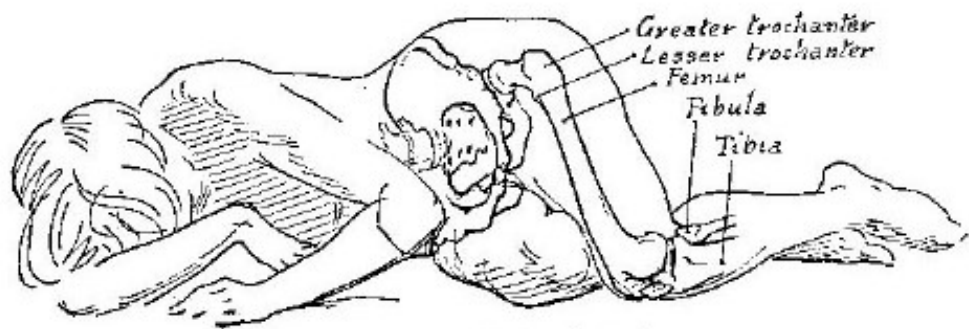
The Buttock

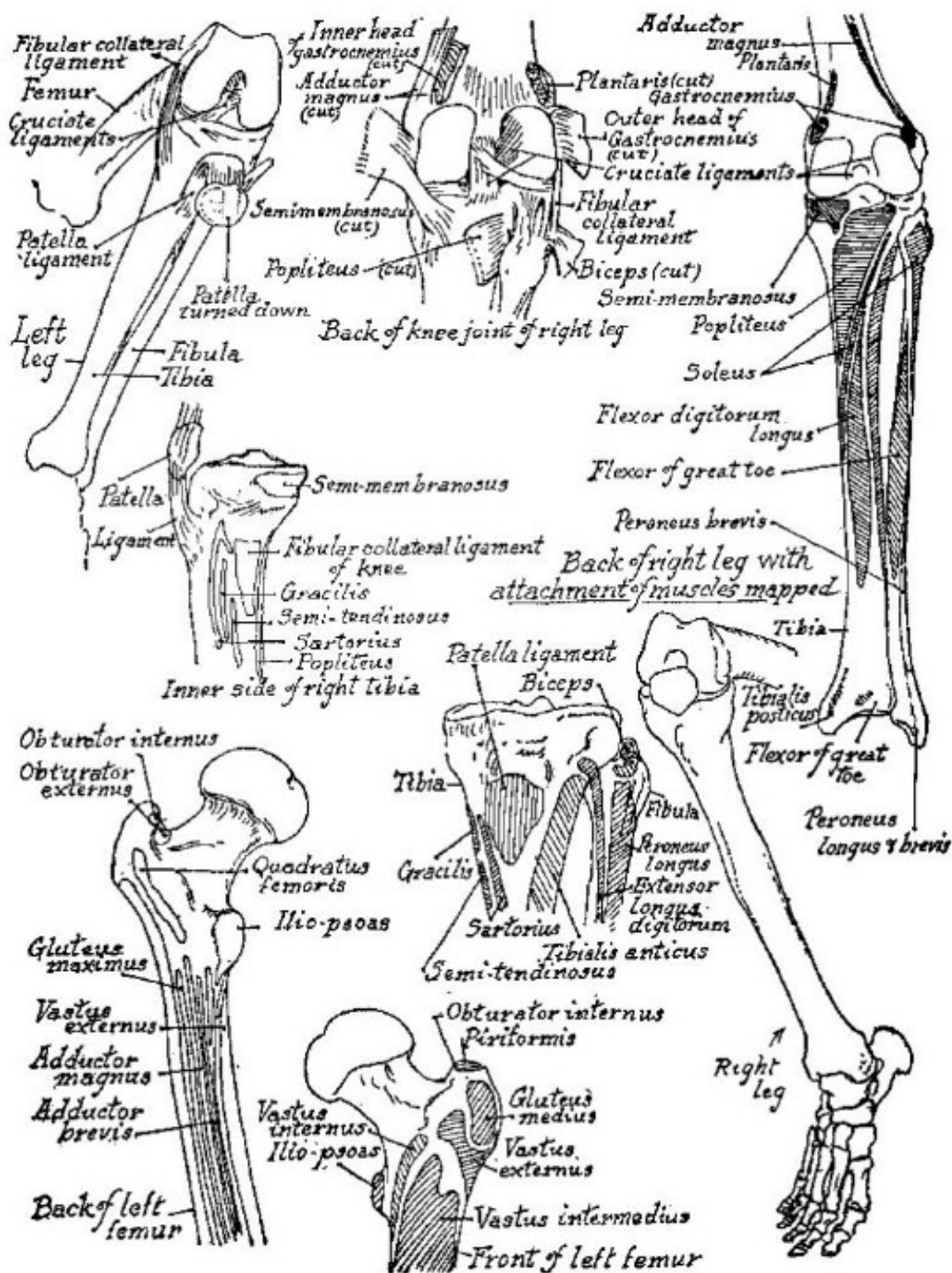




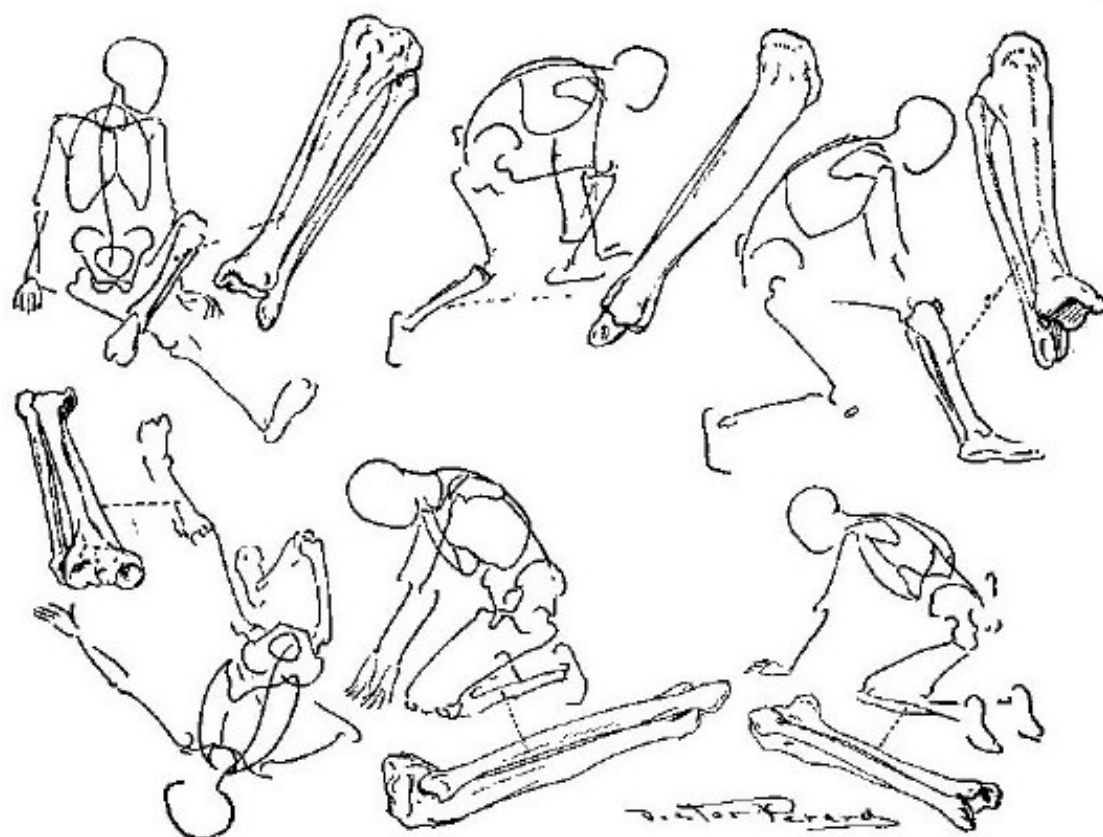
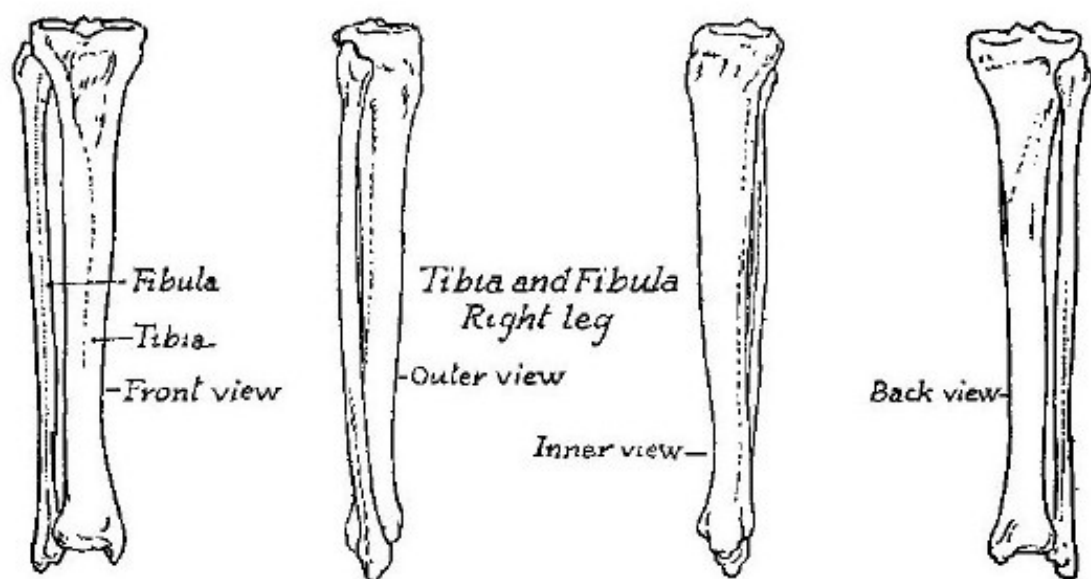


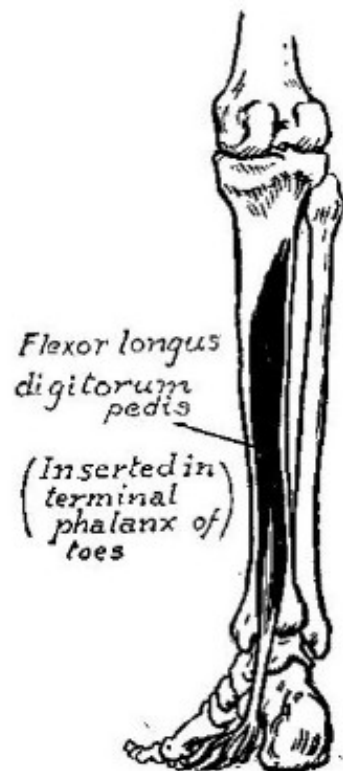
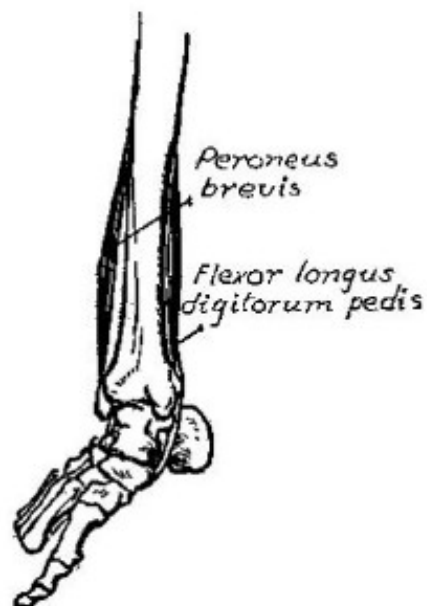
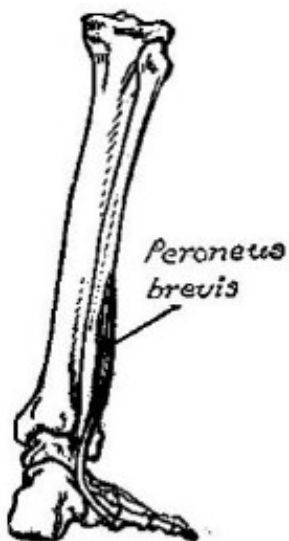
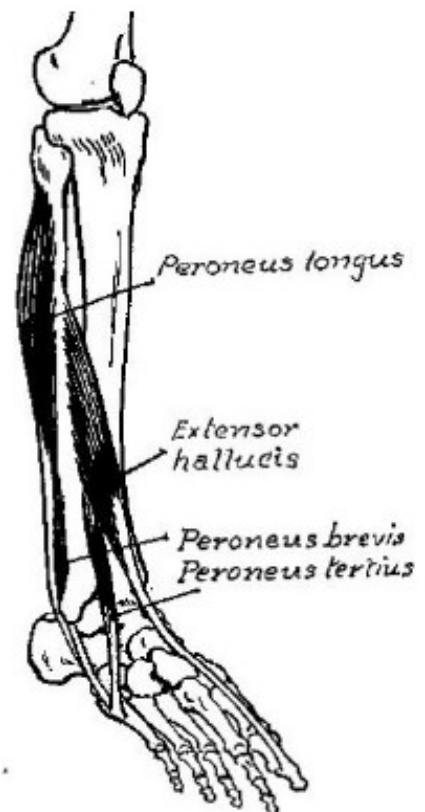
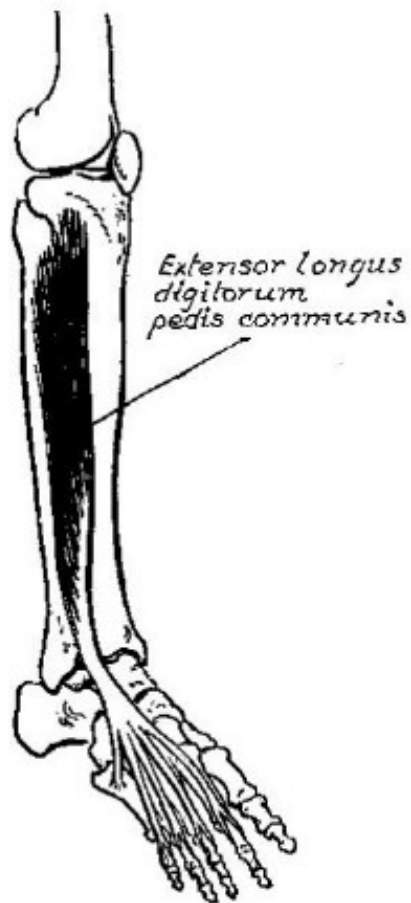
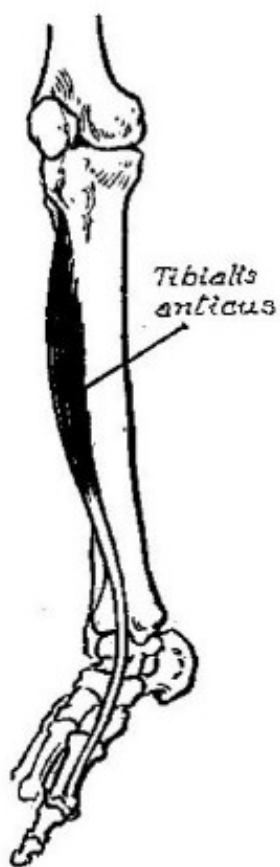


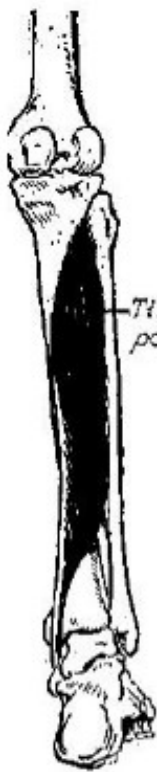











*Tibialis posterior*

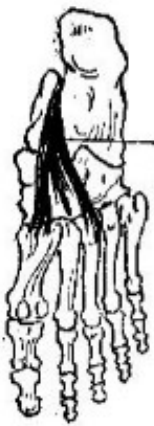

*Plantaris*  
Overlying  
the Soleus  
muscle

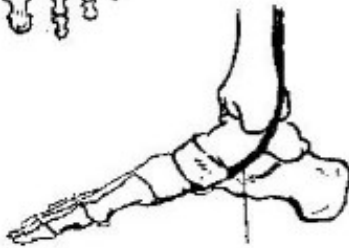
## *Muscles of the calf of leg*



*Soleus*  
Underlying  
Gastrocnemius



*Insertion  
of Tibialis  
posticus*



*Tibialis posterior*



*Flexor  
hallucis  
longus  
(big toe)*  
Insertion  
base of  
phalanx  
of  
big toe

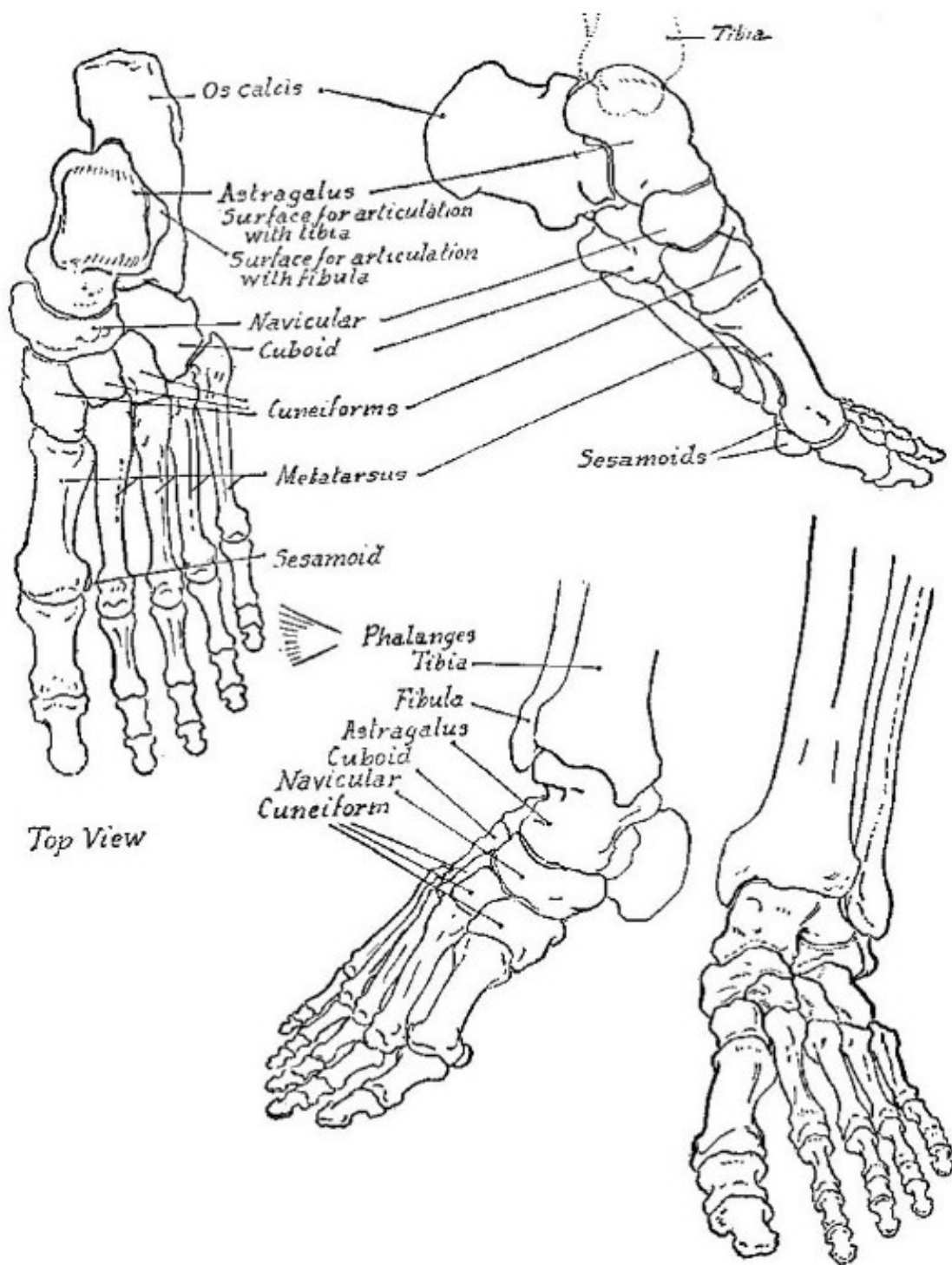
*Gastrocnemius*

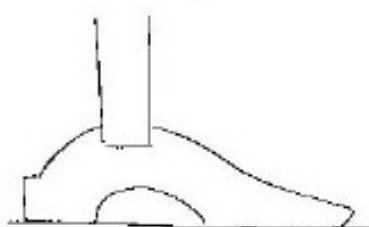
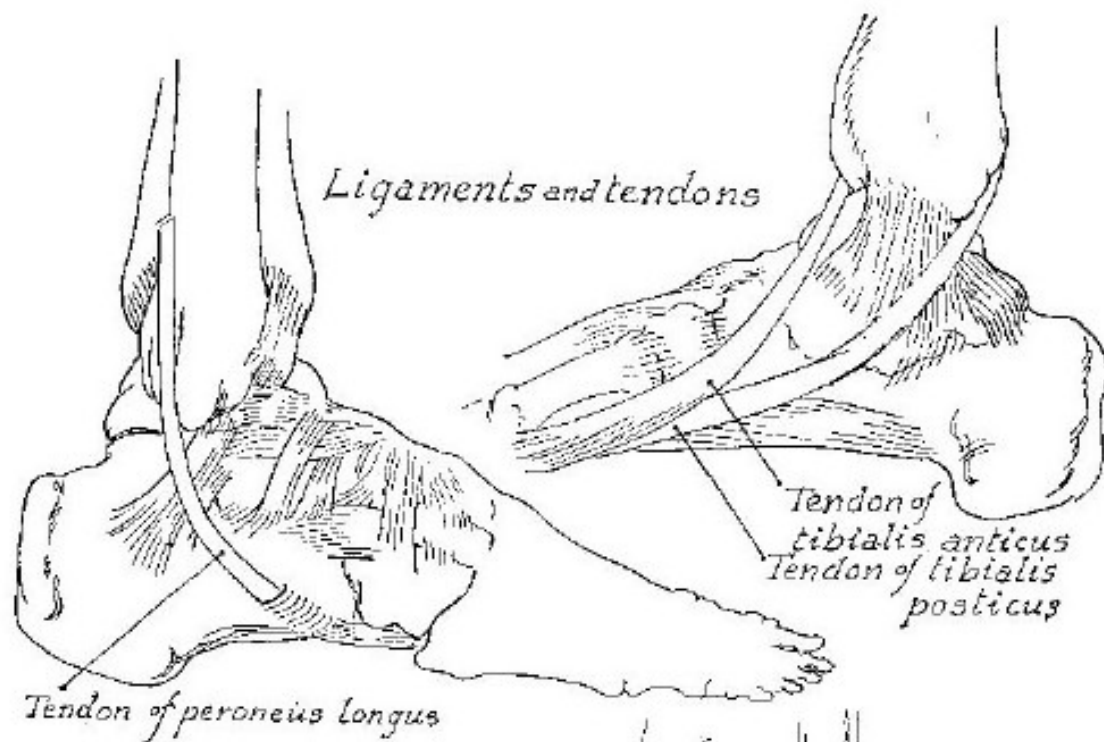




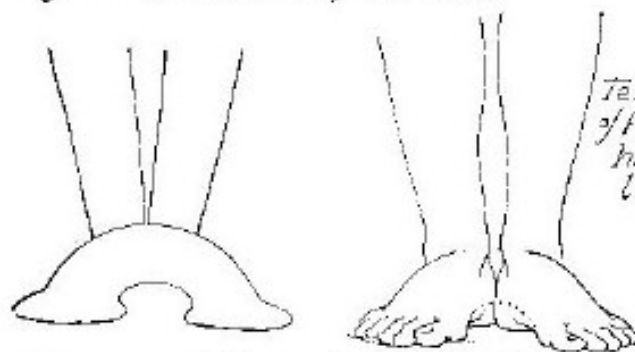
Part VIII

*The Foot*

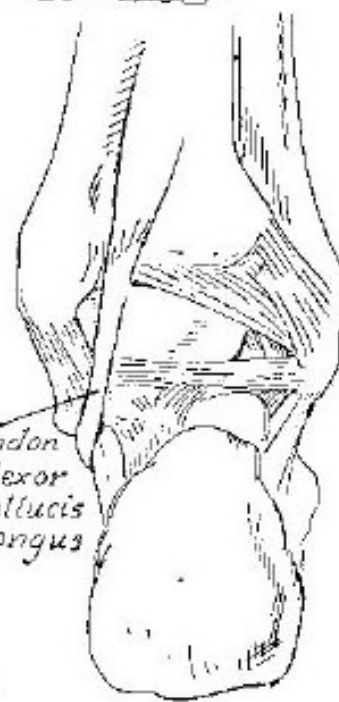


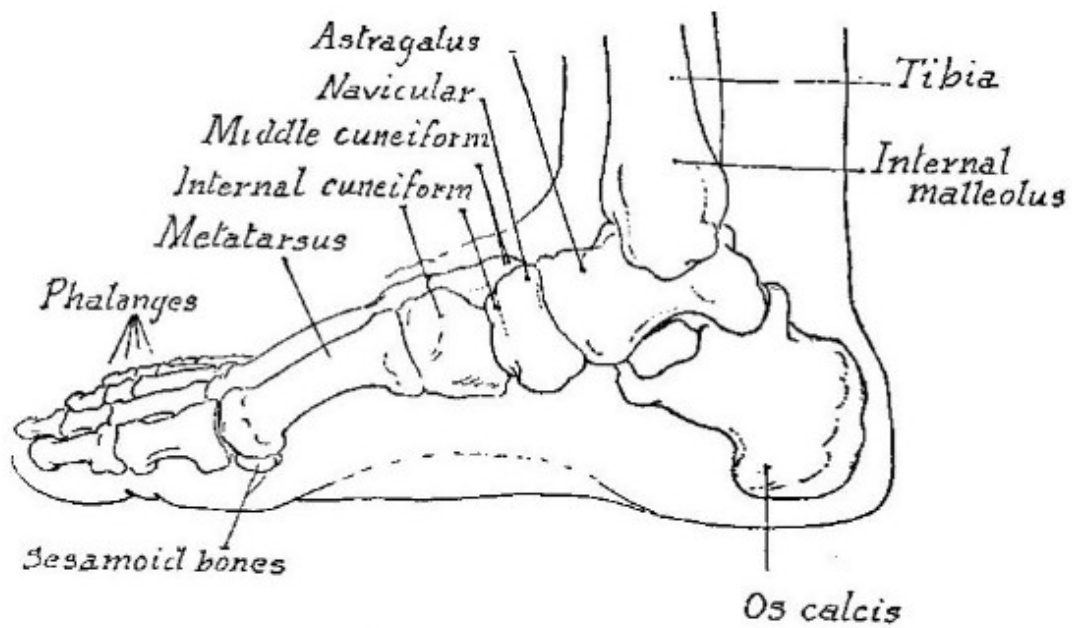


*Diagram of the arch of the foot*

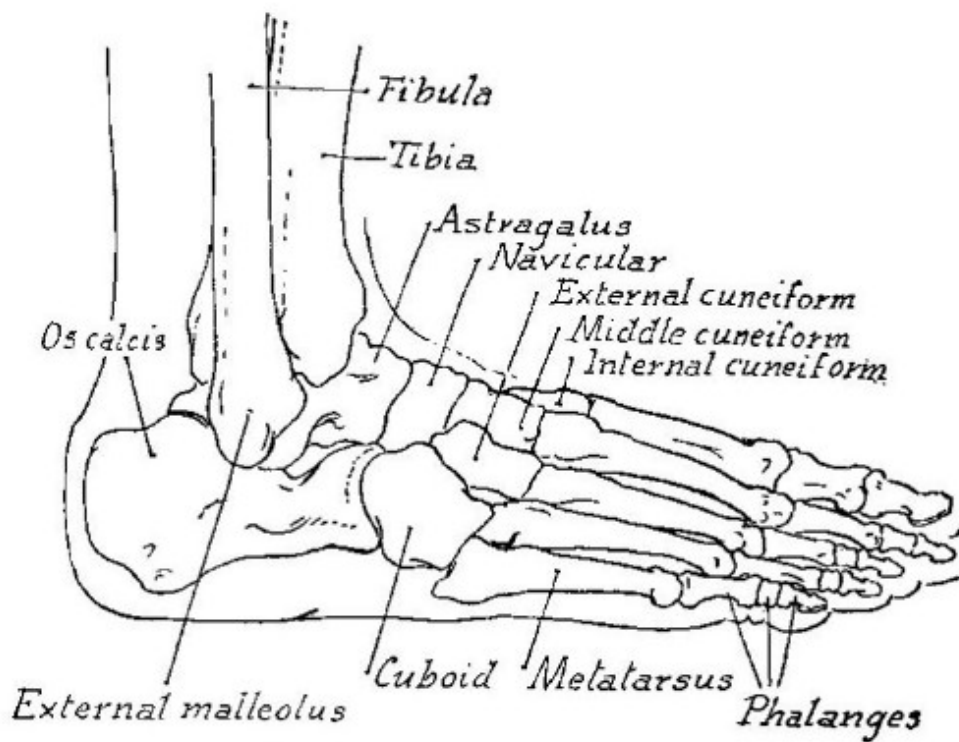


*Diagram of the arches of the feet*  
*(The arches of feet act as springs)*

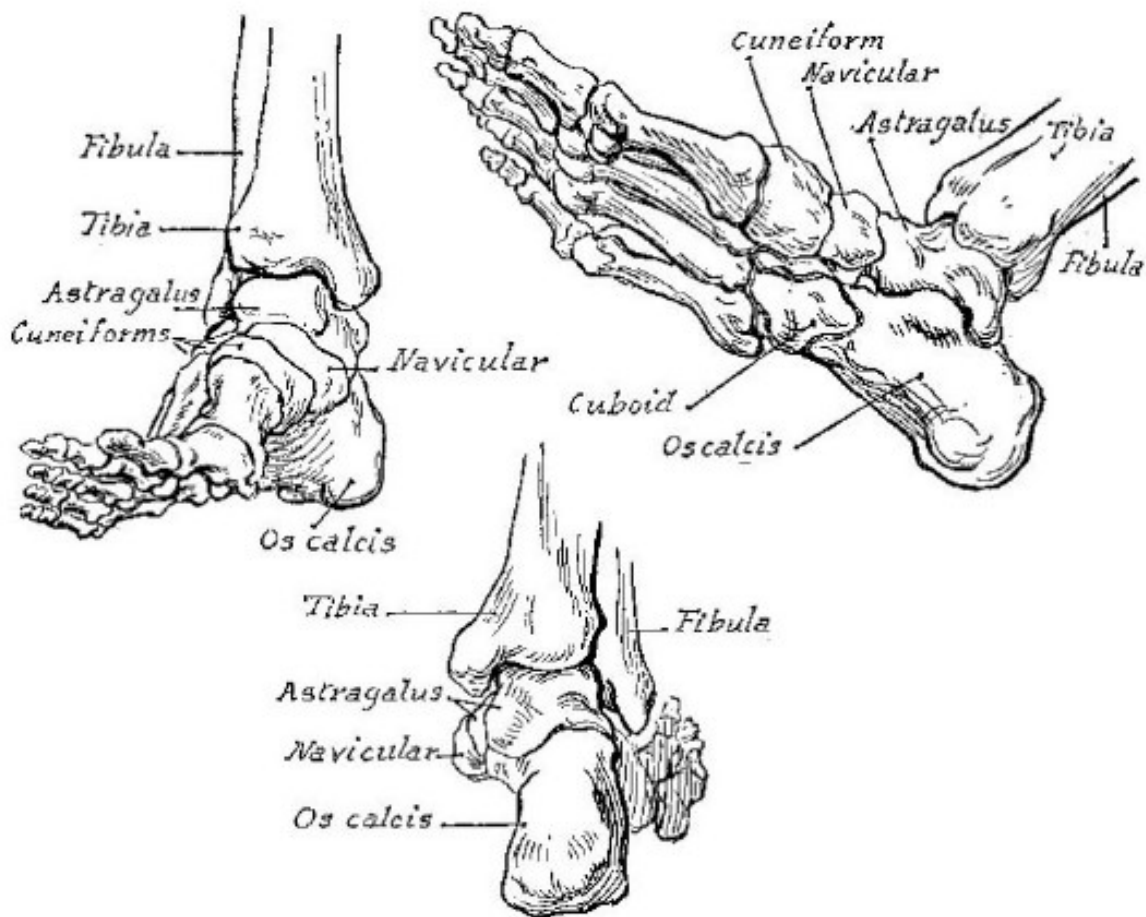
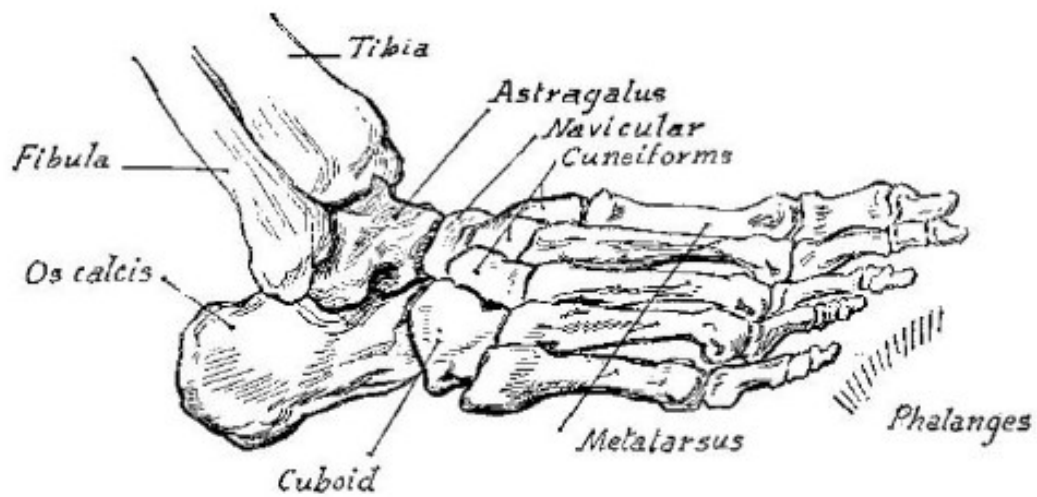




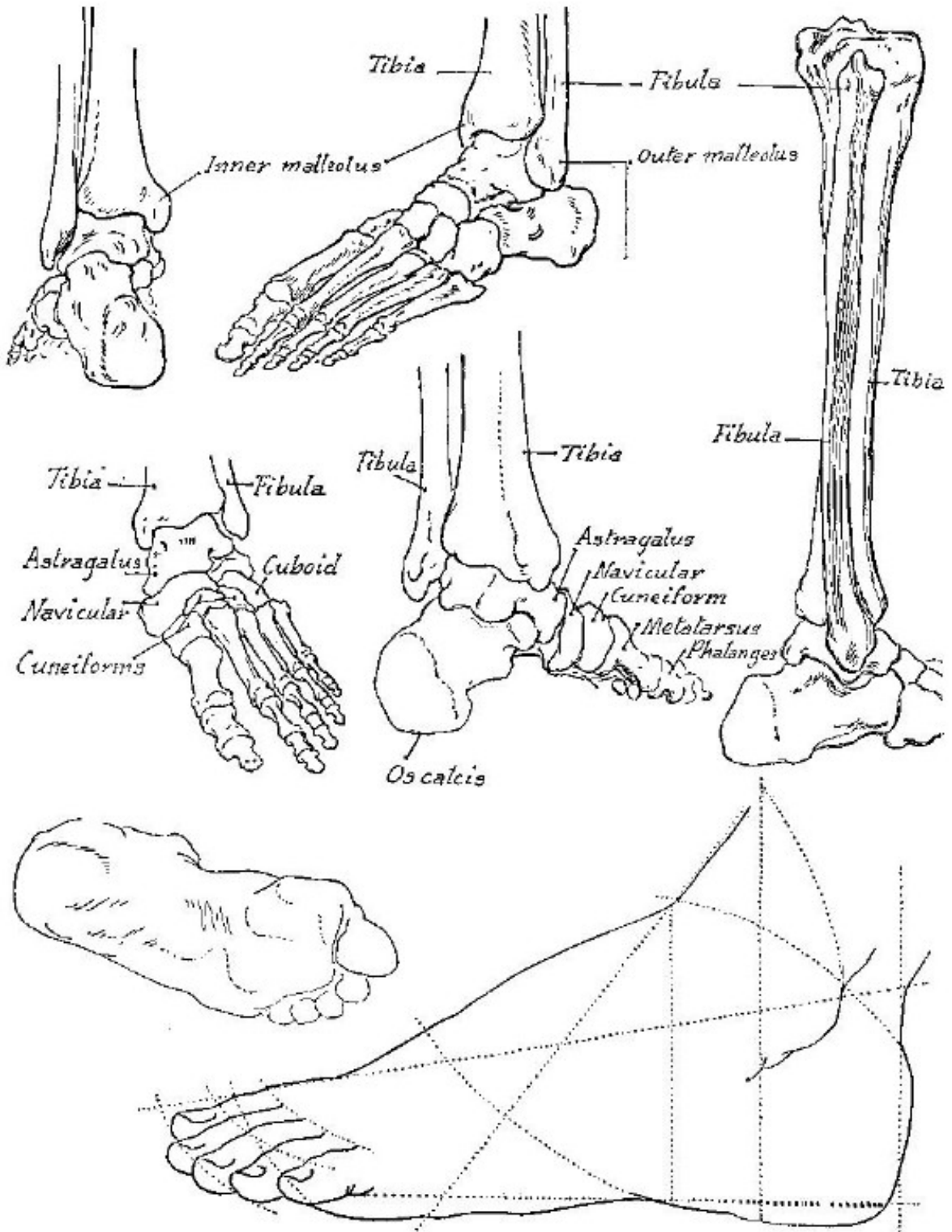
*Inner view*

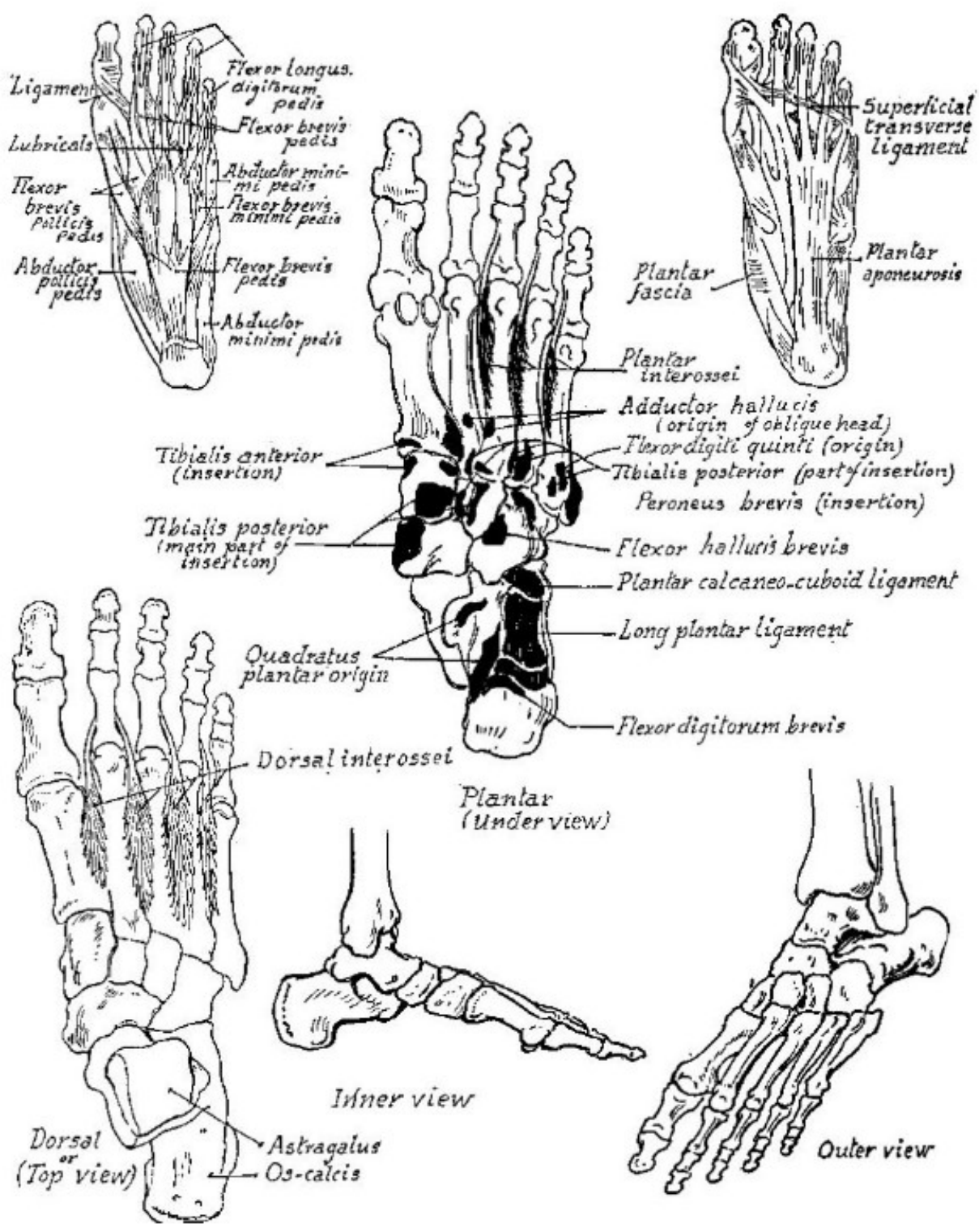


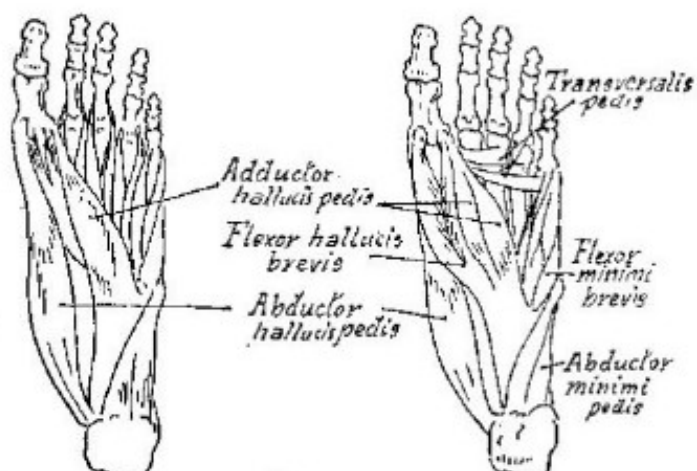
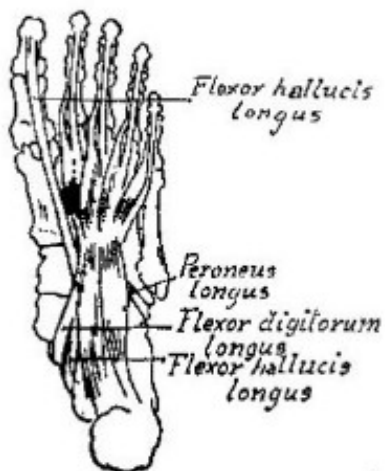
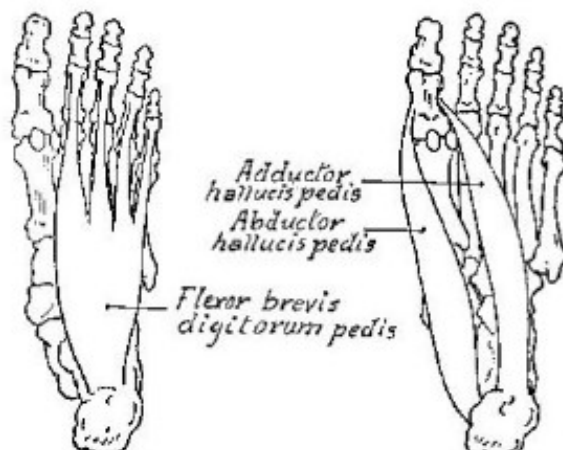
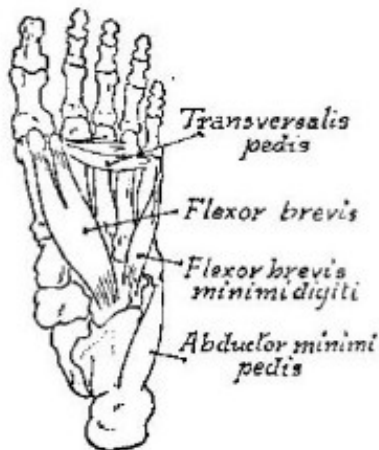
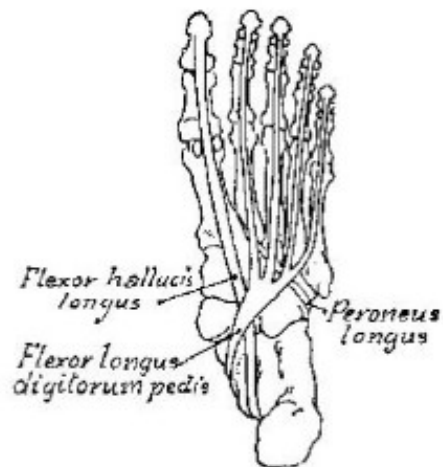
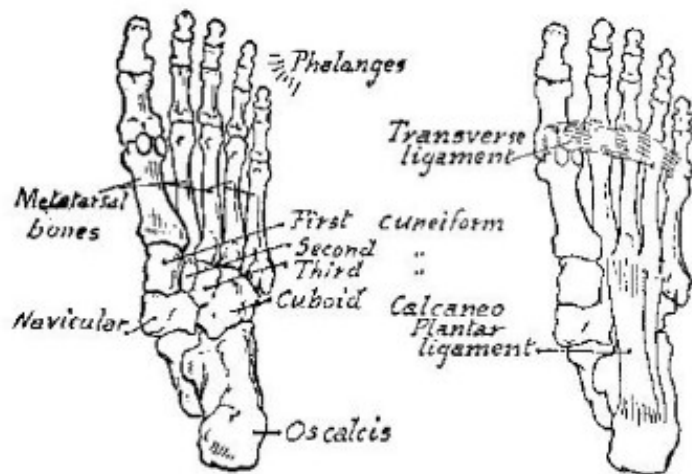
*Outer view*





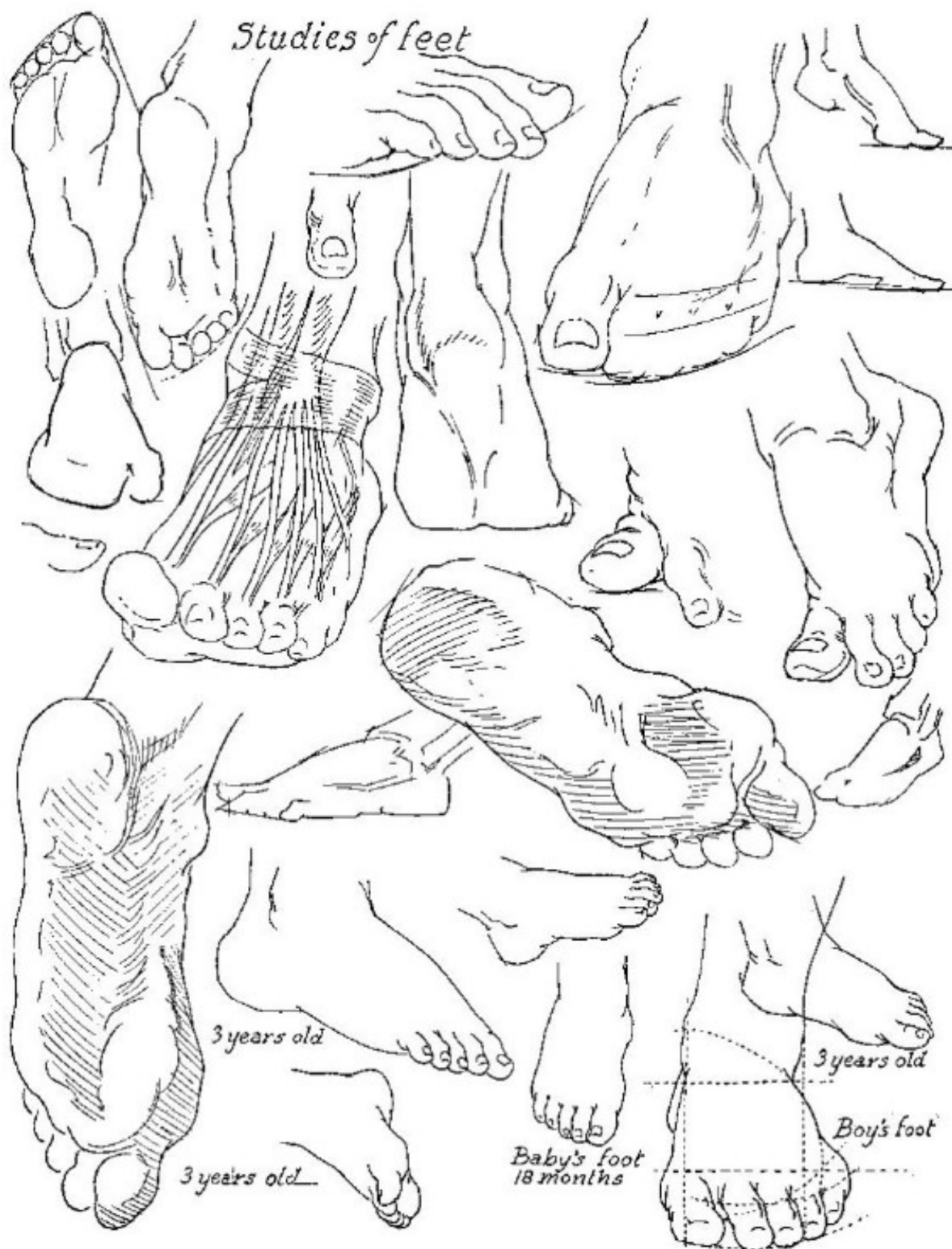


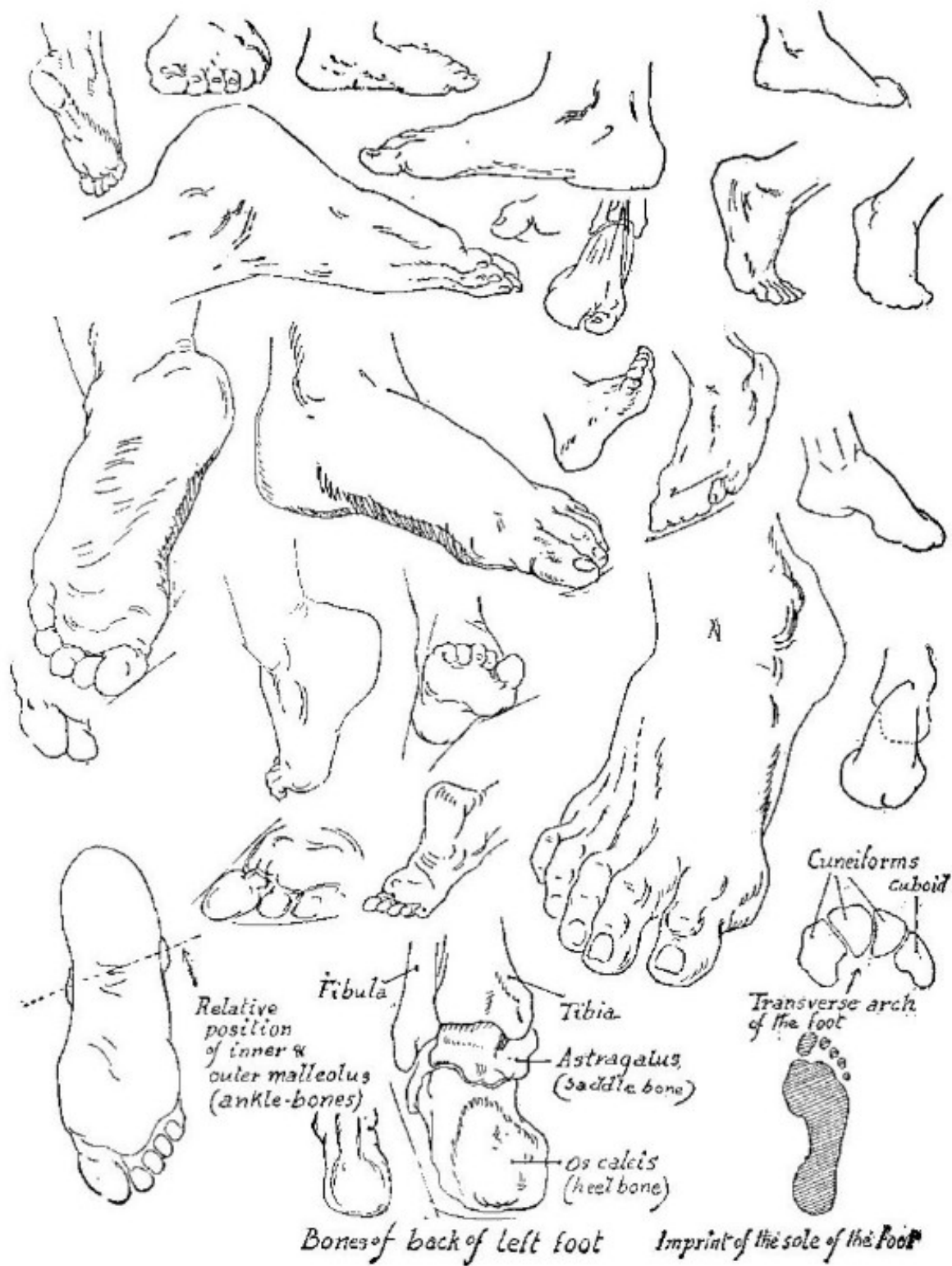


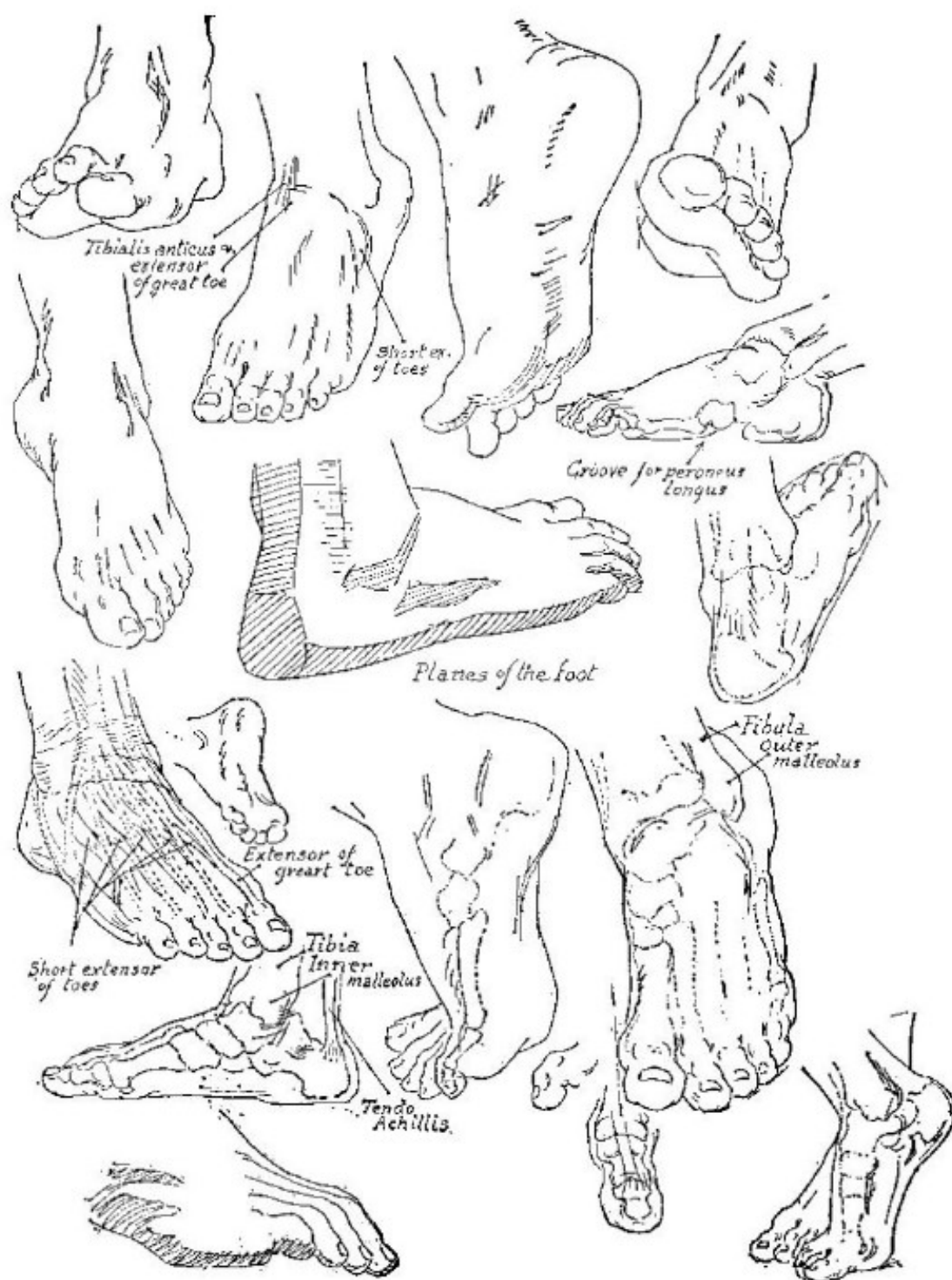


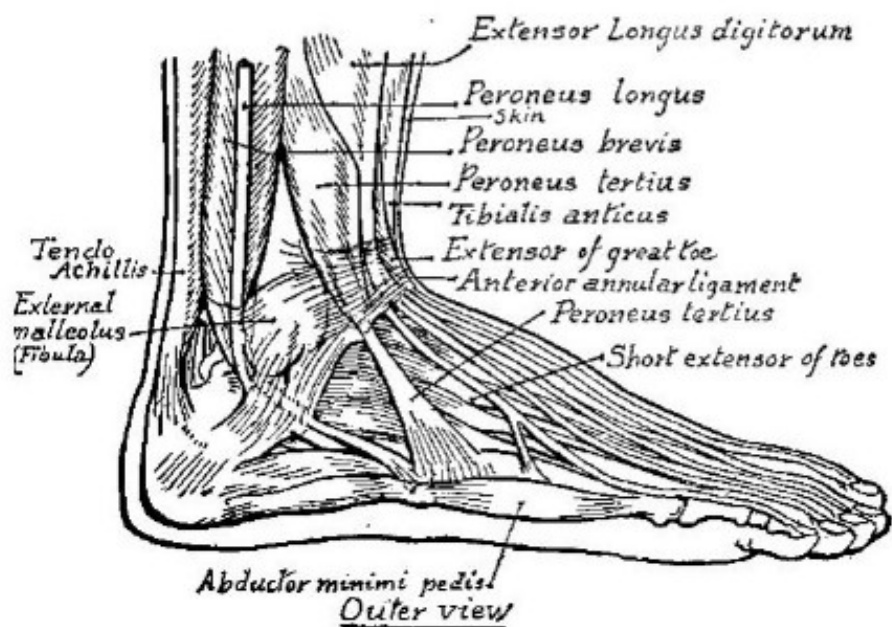
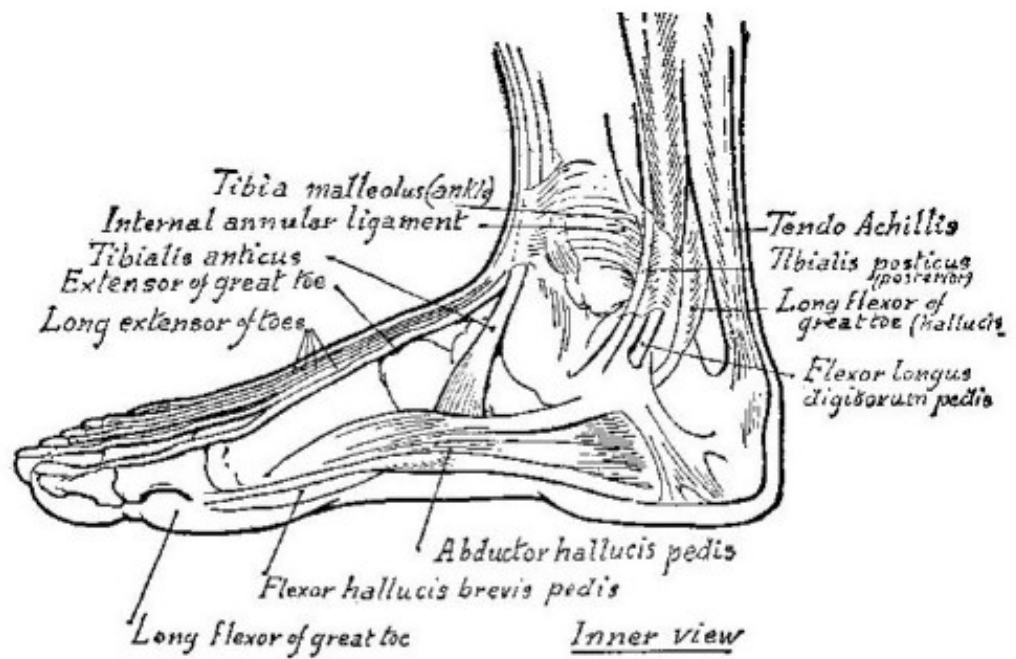
*Plantar View of Foot*

*Studies of feet*











Part IX

*The Ecorche*





